

COLUMBIA LIBRARIES OFFSITE
HEALTH SCIENCES STANDARD



HX00050067

RK280 H772

Columbia University¹⁹¹⁸
in the City of New York

College of Physicians and Surgeons

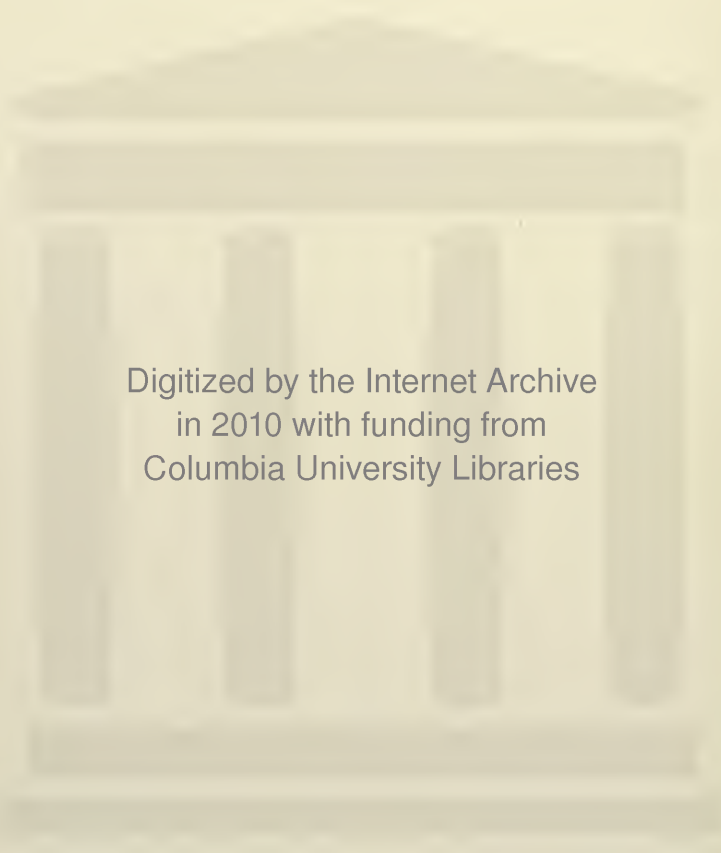


IX

Reference Library

THE NORMAL AND PATHOLOGICAL
HISTOLOGY OF THE MOUTH

VOLUME I
NORMAL HISTOLOGY



Digitized by the Internet Archive
in 2010 with funding from
Columbia University Libraries

BY THE SAME AUTHOR

"AN INTRODUCTION TO DENTAL ANATOMY
AND PHYSIOLOGY: DESCRIPTIVE
AND APPLIED," 1913.

"DENTAL MICROSCOPY," A HANDBOOK OF
PRACTICAL DENTAL HISTOLOGY.

FIRST EDITION, JANUARY, 1895.

SECOND EDITION, JULY, 1899.

THIRD EDITION, MAY, 1914.

PART EDITOR OF TOMES'

"A MANUAL OF DENTAL ANATOMY"

SEVENTH EDITION, 1914.

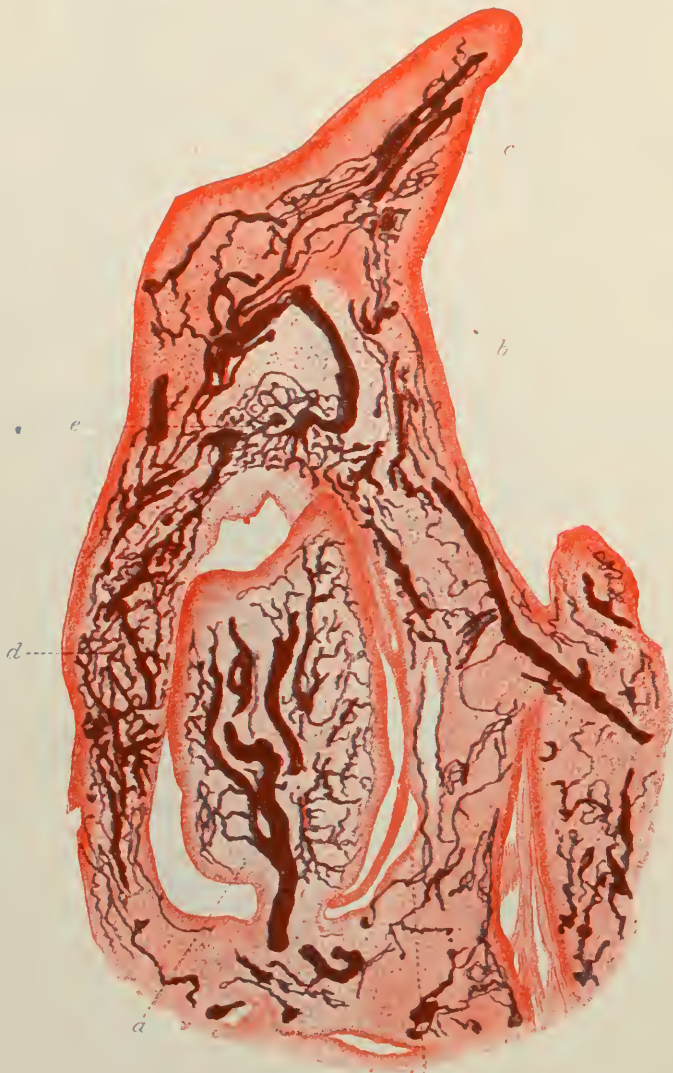

Fig. 10. The Vascular Supply of the First Dorsal Fin during Development.

DESCRIPTION OF PLATE I

Sagittal section through the mandible of a kitten at birth. The vascular system is injected with Prussian blue solution. Tissues hardened in alcohol. Section stained with carmine. Magnified 20 times. A. Internal set of bloodvessels supplying the dental pulp; B. External set to the enamel organ; C. Vessels of the gum; D. Of the alveolar wall and dental capsule; E. Internal anastomoses of external set of vessels; F. Point of junction of external and internal systems. For details see pp. 134 and 262 *et seq.*

THE UNIVERSITY OF
LIVERPOOL
LIBRARY

The Normal and Pathological Histology of the Mouth

BEING THE SECOND EDITION OF

The Histology and Patho-Histology OF THE Teeth and Associated Parts

REVISED AND ENLARGED

BY

ARTHUR HOPEWELL-SMITH

L. R. C. P., LOND., M. R. C. S., ENG., L. D. S., ENG.

PROFESSOR OF DENTAL HISTOLOGY, PATHOLOGY AND COMPARATIVE ODONTOLOGY
UNIVERSITY OF PENNSYLVANIA, PHILADELPHIA; JOHN TOMES PRIZEMAN OF
THE ROYAL COLLEGE OF SURGEONS OF ENGLAND; MEMBRE HONORAIRE
DE LA SOCIÉTÉ ODONTOLOGIQUE DE FRANCE; FORMERLY LECTURER
ON DENTAL ANATOMY, SURGEON AND DEMONSTRATOR OF DENTAL
HISTOLOGY AT THE ROYAL DENTAL HOSPITAL OF LONDON;
MEMBER OF THE FACULTY OF MEDICINE OF THE UNIVER-
SITY OF LONDON; EXTERNAL EXAMINER IN DENTAL
SURGERY AT THE UNIVERSITIES OF BIRMINGHAM,
LEEDS AND LIVERPOOL; LECTURER ON DENTAL
SURGERY AND PATHOLOGY AT THE NA-
TIONAL DENTAL HOSPITAL, LONDON

VOLUME I

NORMAL HISTOLOGY

WITH 2 COLOURED PLATES AND 262 ILLUSTRATIONS
IN THE TEXT, INCLUDING 149
ORIGINAL PHOTOMICROGRAPHS BY THE AUTHOR

PHILADELPHIA
P. BLAKISTON'S SON & CO.
1012 WALNUT STREET

Copyright, 1918, by P. Blakiston's Son & Co.

TR K 280

H 772

193

v. 1

To

SIR JAMES CRICHTON BROWNE, M.D., LL.D., F.R.S.

J. HOWARD MUMMERY, SC.D., PENN., M.R.C.S., ENG., L.D.S., ENG.

AND

FREDERICK J. BENNETT, M.R.C.S., ENG., L.D.S., ENG.

AS AN

EXPRESSION

OF THE ESTEEM AND SINCERE REGARD

OF

The Author

PREFACE TO THE SECOND EDITION

OWING to a completer extension of the subjects included in this work, it has been considered necessary to change its title. The present one more correctly represents its scope.

For the convenience of the reader the book is now issued in two volumes. The first relates to the Normal Histology of the Mouth and its Contents, and the second to the Pathological Conditions found therein, with special reference to the Teeth of Man. Part III in that Volume records the latest observations of the dental tissues at times encountered in ovarian teratomatous cysts.

A thorough revision of the First Edition has been effected. Six additional chapters appear in Volume II, being specially revised accounts of original researches undertaken by the author in recent years. Chapter XVII, Vol. II, contains part of a paper presented by Mr. MacAdam Eccles, M. S., and the author to the Royal Society of Medicine of London. The substance of the chapter dealing with "Pyorrhœa alveolaris" was originally submitted to the XIth International Medical Congress at Buda-Pesth. The illustrations remain unique.

Supplementing those first described in the First Edition, originality can be claimed for the observation, investigation, recording, and naming of several new pathological conditions of the human dental tissues, *e.g.*, Nanoid dentine, Odontocèles—extra-capsular and sub-capsular—Diphyodontic gemination, Hydropic degeneration of the oral mucous membrane, Fibroid degeneration of the alveolo-dental periosteum, etc.

Some changes in terminology have been deemed advisable and needful. Thus "epiblast" and "mesoblast" are now "ectoderm" and mesoderm;" the "medullated" and "non-medullated" nerves become "myelinic" and "amyelinic" respectively. The "dental follicle" is more correctly designated the "dental capsule;" for it bears no histological resem-

blance to, nor does it at all approach the functions of such widely dissimilar structures as the hair follicles, the Graafian follicles, the agminated and solitary follicles, etc.

A description of the pathological condition, entitled in the First Edition, a "granuloma" is omitted from the present volume. A so-called granuloma does not conform to the correct definition of a tumour, and is in no sense a new growth, being merely one form of granulation tissue, the result of chronic inflammation of the periodontal membrane. It is true that certain diseases such as tuberculosis, syphilis, glanders, leprosy, actinomycosis, etc., are grouped by some pathologists as the infective granulomata, because they give origin to formations resembling tumours composed of granulation tissue, or at least a tissue of closely allied appearance, and are of infective derivation. It is also true that some hyperplastic growths of the skin, including *Mycosis fungoides* and *Dermatitis papillomatosa*, as pointed out by Weichselbaum ("Elements of Pathological Histology," 1892), which develop as a direct consequence of inflammation are sometimes called granulomata. But there is nothing, either from a clinical or pathological point of view, to justify the application of the term to chronic inflammation of the alveolo-dental periosteum, or its retention in modern dental literature.

One hundred and sixty new and original photographs and photomicrographs have been added to the text.

The author's grateful thanks are extended to his friend and colleague Professor Nathaniel Gildersleeve, M. D., for rewriting Chapter XVI, Vol. II. His contribution represents *le dernier mot* with regard to the science of this branch of Oral and Dental Pathology: it is authoritative, perspicuous, comprehensive, important and valuable.

To "The Dental Cosmos" for the use of many illustrations, and to the Publishers for their courtesy and excellent typographical and pictorial presentation of the pages of the book the Author desires to tender his best thanks.

THE UNIVERSITY OF PENNSYLVANIA, PHILADELPHIA.

PREFACE TO THE FIRST EDITION

IN presenting to the reader this humble effort to detail the essentials of his favourite study, the writer is fully sensible of the many shortcomings, textual as well as pictorial, which are necessarily attendant upon such an undertaking. It is extremely difficult to prevent subjective impressions and interpretations from obtruding themselves here and there, no matter how subsidiary to other weighty matters the author has endeavoured to make them. The personal equation is generally present and apparent in all work. The book represents an earnest struggle for an intimate knowledge of the truth, clear and unprejudiced. And if the expressions of personal opinions seem to be rendered too conspicuous they must be regarded on their individual merits, and tested and accepted or rejected, as the case may be. The astute reader must be the judge. The fallibility of him who now enters upon his task must not be forgotten, and where errors have been committed they must be condoned. But the honesty of the writer's purpose or of his convictions must never for one moment be impugned.

The establishment on a scientific and logical basis of the order, sequence, and internal composition of each chapter has been attempted. The manner of dealing with the variety of pathological facts and histological data in Chapters XIV., XV., and XVI. has been founded on two considerations. First, it has been deemed advisable to place on record an intelligent enunciation of what is implied by certain words. Some writers, especially those of the Continent of Europe, are apt to confuse ideas, the result being a constant use of some terms found in ordinary dental nomenclature which possess a lack of uniformity of definition, etc. Second, this method of arrangement affords a convenient, and, therefore, suitable "setting" or background for the description of the

histological characteristics of teeth and allied organs, which, after all, are intended to be the most distinguishing feature of the work.

An acquaintance on the part of the student with the simple elements of histology and pathology is pre-supposed. An extensive bibliographical mass, to which references are made throughout, has been consulted. In order not to burden the text with too great a number of the writings of many histologists, an attempt has been made to place their hypotheses on an eclectic basis, namely, those which in the eyes of the author are worthy, some of notice merely, others of serious consideration. Many fundamental propositions are not universally accepted, and some of these are here noted; so that the reader, interested in any special branch of Dental Histology or Histo-Pathology, may receive hints and be guided and stimulated in taking up original research.

In this way, some prominence is accorded to the recent writings of Oscar Römer, who, with others, denies the existence *per se* of the sheaths of Neumann. On the other hand, the work of many is already sufficiently completed, and knowledge is, as far as can be ascertained, accurate enough. Thus, with no fear of being prolix, the researches of Aitchison Robertson on the growth of dentine may be cited extensively. But examples need not be multiplied.

The inclusion of Part III.—a preliminary histological examination of many of the commoner and some of the rarer morbid affections of the teeth, gums, and osseous framework of the mouth—affords the reader an opportunity of comparing the morphological differences between healthy and diseased conditions of the masticatory organs. This section of the book should, therefore, be read and studied in conjunction with Part I., and deductions drawn therefrom. The juxtaposition of the two should be of assistance to the thoughtful and enquiring student, and serve to extend and widen the area of his mental horizon.

The author desires to express his indebtedness to the published works of Mr. Charles Tomes, and to Drs. G. V. Black, Miller, Leon Williams, and Norman Broomell, for the use of

some of the electrotypes which have accompanied their communications to *The Dental Cosmos*; and also for the same to the Council of the Odontological Society of Great Britain. In addition, he is grateful for the loan of valuable material and sections to many personal friends at home and abroad. Finally, he wishes to thank Mr. Frank J. Butler, for his original water-colour drawings; and the Publishers for their unvarying courtesy and assistance in the production of the book.

BERKELEY SQUARE, LONDON, W.

Contents

Part I

THE DENTAL TISSUES

CHAPTER I

	PAGE
Prolegomena	3
Introductory—Dental Histology a Part of Dental Anatomy— Founders of the Science and Art—Importance of the Subject— Historical—Problems of the Present and Revelations of the Future	

CHAPTER II

Nasmyth's Membrane	9
Definition—Views as to its Origin—Dimensions—The Cellular Layer—The Translucent Pellicle	

CHAPTER III

The Enamel	17
Definition—Origin—Distribution—Relationships—Gross Anatomy —Structure of the Rods and Matrix—Views as to their Nature and Origin—Their Mode of Arrangement—The Striæ of Retzius— Views as to their Origin—The Lines of Schreger—Enamel “Spindles”—Views as to their Origin and Nature—The Amelo- dental Boundary	

CHAPTER IV

Ortho-dentine	49
Definition—Varieties—Origin—Gross Anatomy—Structure of the Matrix—The Tubes, their Measurements, Curvatures, Branches and Contents—Views as to the Nature of the Latter—The Sheaths of Neumann—Views as to their Nature—The Interglobular Spaces, Dimensions, and Contents—The Granular Layer of Tomes—The Lines of Schreger—The Contour Lines of Owen—Laminæ—Views as to their Nature—Secondary Dentine	

	PAGE
CHAPTER V	
The Cementum	79
Definition—Origin—Distribution—Gross Anatomy—Structure of the Matrix—Incremental Lines—Perforating Canals and Fibres	

CHAPTER VI

Structural Modifications of the Enamel, Dentine, and Cementum	93
The Enamel of the Teeth of Rodents—Of the Manatee—Of Fishes—Tubular Enamel—Views as to its Origin and Development—Plicidentine—Vaso-dentine—Osteo-dentine—Classification of Dentines—Lacunated Cementum	

CHAPTER VII

The Dental Pulp	111
Definition—Origin—Dimensions—Odontoblasts, their Shape, Size, Relationships, Structure, Processes, and Analogies—Pulp Cells Proper—The Stroma—The Basal Layer of Weil—The Vascular System—Histology of the Arteries, Veins and Capillaries—The Nerve Fibres, their Arrangement, Structure, and Terminations in Fishes, Reptiles, and Mammals—Views as to their Ultimate Endings	

CHAPTER VIII

The Alveolo-dental Periosteum	166
Definition—Origin—Dimensions—The Fibrous Elements—The Cellular Elements—The Blood Supply—The Nervous System	

Part II

THE ORAL TISSUES

CHAPTER IX

The Oral Cavity and its Accessories	181
The Minute Anatomy of the Lips and Cheeks—The Tongue—The Salivary Glands, their Ducts, and Mucous and Serous Acini—The Hard and Soft Palate—The Palatine Tonsils	

CHAPTER X

The Histology of the Maxillary and Mandibular Bones.	195
Origin—Distribution of Varieties of Bone—General Structure of Bone—Structure of Bone of the Canine Fossa—Of the Interdental Septa—Of the Hard Palate—Of the Wall of the Maxillary Sinus—Of the Mandible—Of the Alveolar Process	

CHAPTER XI

PAGE

A Group of Minor Structures.	209
The Histology of the Absorbent Organ—Of the Dental Capsule— Of the Gum, its Mucous and Sub-mucous Tissues—Of the Mucous Membrane of the Maxillary Sinus, its Epithelium, Sub-mucous Tissues and Glands	

Part III

THE HISTOGENESIS OF THE TEETH OF MAMMALS,
FISHES AND REPTILES

CHAPTER XII

The Development of the Teeth in <i>Mammalia</i>	231
Earliest Phases of Evolution—Changes in the Ectoderm—Formation of the Dental Furrow—The Primary Epithelial Inflection— Origin of the Lip-furrow and Tooth-band—Views as to Derivation— Changes in the Mesoderm—Evolution of the Enamel Organ—The Metamorphoses Occurring in and around the Tooth Germ at the Period of Formation of the Dentine Germ—Structure of the Enamel Organ—Changes in the Dentine Papilla—Subsequent Embryolo- gical Changes—Evolution of the Permanent Tooth Germs—The Blood Supply of the Developing Dental Tissues—The Origin of the Blood-vessels, their Arrangement, Mode of Distribution, and the Areas Governed by Them—Latest Research in the Vascular Supply —Final Stages of Dental Evolution—Origin of the Dental Capsule —Histories of the Various Structures Concerned in the Development of the Teeth—Development of the Enamel—Views as to its Nature —Development and Growth of the Dentine and Cementum—Table Showing Phases of Growth of the Several Parts of Tooth Germs in Human Fœtuses at Half Term—Measurements of the Same— Histogenesis of Ovarian Teratomatous Teeth	

CHAPTER XIII

Development of the Teeth in <i>Pisces</i> , <i>Reptilia</i> and <i>Batrachia</i>	312
The Evolution of the Teeth in the Cod—In the Dog-fish—In the Crocodile—In the Lizard—In the Snake—In the Newt	
Appendix	327
Note A.—On the Functions of the Cells of the Pulp—Note B.— Physiological (Lacunar) Absorption of the Alveolar Processes of the Jaws of Man	

PART I
THE DENTAL TISSUES

CHAPTER I

PROLEGOMENA

To write a book is to build a house. When completed, the chapters are the rooms, adroitly planned and suitably furnished with pictures of interest. From the windows, the eye surveys many well-known fields and oft-trodden paths; but, beyond, it is unable to pierce the problem hills of uncertainty.

All literature relating to the theme of this thesis must, perforce, have its foundation stones laid on the classic work of Hunter, Kölliker, Owen, Tomes. It is impossible and unwise to ignore this work. In this manner the following pages are but comparable to a new wing of the house of Dental Anatomy, which these investigators have progressively and successfully raised; and if, from the windows, some instructive glimpses of the surrounding country can be obtained, and a few finger-posts pointing to the unknown, though by no means unknowable, be discovered by the eye—aided not by telescope, but by microscope,—then the author will rest content.

That a treatise which deals chiefly with descriptions of the minute anatomy and pathology of the teeth and associated parts should be specially required may be questioned by some. Inasmuch, however, as these tissues, by reason of their unique constitution, differ most strikingly from other specialised organs, such as the eye, the nose, the larynx; inasmuch also, as general histological text-books treat somewhat sparingly, and sometimes incorrectly, of this subject, the production of these pages has seemed to the author perfectly justifiable, nay more, almost a necessity in these latter times. "*Cui bono?*" was once a frequent question; but there can be only few (if any) who would to-day care to diminish rather than to increase the range of knowledge, and limit the speciality of Dental Surgery to mere mechanical manipulations.

Dr. Otto Walkhoff, Professor of Conservative Dentistry in the University of Munich, in an introduction to his "Normal Histology of the Human Teeth," 1901, declares:

"The special study of the Histology of the Teeth is the binding link between practical dental surgery and general surgery. The branch of learning which deals with this subject is of great importance for the practical knowledge of the prospective dental surgeon. He learns not only the minute anatomy of the parts, but also the mutual relationships of those parts. Those dental surgeons who have had experience in making and examining sections of teeth are able to treat carious cavities with greater knowledge, and to appreciate and understand any complications that may arise, and therefore take more appropriate and more therapeutic measures than those unaccustomed to the science. With the fuller education of dental surgeons in this study, the production of false pathological and other statements will be relegated to the past. Thus one acquainted with the structure of the tissues could never claim to completely cleanse and solidly fill the root-canals of teeth. A due regard to the Histology of the tissues of the mouth (as well as its Bacteriology), and the most perfect execution of mechanical operations form the groundwork of the conservative dentistry of later years."

It must also be added, as has been expressed in another place, that the practice of microscopical work imparts to the student that delicacy of touch and nicety of adjustment of digital dexterity which is impossible of attainment by other means and methods.

This book, then, is published with the avowed purpose of drawing the attention of the reader to the essentials of a profoundly fascinating branch of science; of indicating some difficult and apparently irreconcilable and irresolvable histological propositions; of attempting to elucidate, illuminate and complete other recondite and unfinished studies; and finally, of establishing upon a permanent and convincing basis many accepted postulates and uncontested facts.

Dental Histology, with its collaterals, is nearly, but not quite, an inductive science. Unfortunately, it is by no means

an exact one, although, through the medium of new methods of research, there is no reason why, during the next half-century, it should not become so.

The science and art peculiar to it are of paramount importance alike to student, pathologist and surgeon. In the interpretation of many ordinary and extraordinary phenomena connected with the genesis and evolution of the teeth; in the solution of certain obscure physiological and anatomical and pathological problems; in the every-day diagnosis of oral and dental disease; in short, in the undoubted assistance it can and does render to the earnest worker in the art of Dental Surgery, it may fairly be claimed for this subject that to-day it cannot be dismissed without recognition, or without the bestowal upon its varied aspects of such thoughts and labour and research as they deserve. In its scope and aims it is certainly ancillary to no other branch of learning.

On so slender a scaffolding it would seem somewhat difficult, if not well-nigh impossible, to build up such a large and diversified collection of valuable and interesting data; nevertheless, a moment's reflection will soon assure the reader that this framework is extensive even in its limitations.

To attempt to recall and record the History of Dental Histology would form a congenial and satisfactory task. Mere mention of the names of those specially associated with it must, however, here suffice. As for the past, it is pleasant to an Englishman to dwell on the works of Thomas Huxley, Sir Richard Owen, Salter, Sir John Tomes, Storer Bennett; while as for the present, the bibliography of British dental science has been enriched by the writings of C. S. Tomes, who has patiently and laboriously investigated, among other subjects, the development of the teeth of fishes, reptiles, batrachians, and marsupial mammals; of Howard Mummery, to whom our knowledge of the development and growth of dentine is largely due; of Milles and Underwood, in their researches on dental caries; of Leon Williams, the able and skilful exponent of the structure and pathology of human enamel; of Paul, who has successfully demonstrated the minute anatomy of Nasmyth's membrane; of J. G.

Turner, who has identified himself with the etiology and pathology of dental cysts; and of Kenneth Goadby, the prolific contributor to current literature of a mass of information on dental and oral mycetology, etc. In America, the list of names must be headed by those of Andrews, Black, Norman Broomell, etc.; and on the Continent of Europe by those of Arkövy, von Ebner, Galippe, Grevers, Kölliker, Legros, Magitot, Miller, Retzius, Röse, Vignal, Walkhoff, Wedl, Weil, Zsigmondy, etc.

Rising out of a review of this subject come many thoughts, and chief among them are the remarkable scantiness of actual and reliable information concerning many things. Thus, with regard to the normal minute anatomy of the hard tissues, no answers have been returned to the questions, "How is enamel fixed so intimately to the periphery of the dentine?" "Whence comes its pigmentation?" "What is the manner of development of the branches of the dentinal tubes?" As to the pulp and alveolo-dental periosteum, some knowledge is available of the nerve endings in the first, while the histology of the latter still remains, as far as its nervous system is concerned, a *terra incognita*.

Turning to the realm of Pathology in general, and erosion of the teeth in particular, the causes of the occurrence of occlusion of the tubes requires further consideration, as do also the presence and sensitiveness or non-sensitiveness of the interglobular spaces in hypoplastic teeth and ovarian cystic teeth, the changes in the dentinal tubes producing the "pipe-stem" appearance of caries, and their invisibility in senile affections. Tempting fields for research are all these and many others. The exigencies of this chapter disallow more than the brief consideration of one subject for discussion—viz., the pigmentation of enamel.

Thick sections of this tissue examined macroscopically before finally grinding, polishing and mounting always appear stained more or less deep brown colour. This is different from and other than that of the brown striæ of Retzius. The thinnest sections ultimately reveal apparently but little, if any, pigmentation. Is this colouring, then, due to mere optical effects?

In the opinion of the author, No. Because, examples of the natural staining of epithelial tissues constantly occur—as in the case of the epidermis of the negro, where granules of melanin are found in the *rete Malpighii* of the epithelial layer of cells. Other analogies may be cited also—*e.g.*, the pigment corpuscles in the ramified nerve cells in the anterior cornua of the spinal cord of man, and the pigment bodies in the cortical substance of the hairs of man.

Again, the normal pigmentation of the enamel is a prominent feature of the teeth of many rodents. This also disappears on grinding very thin; and it is impossible to say whether it is resident in the enamel rods, or in the cementing substance, or in both. The tissue is unequally pigmented; if it was due to the chromatic aberrations of light it would most likely be uniform. Finally, in the case of pathological or congenital pigmentation of the cementum and dentine, the colour, though pronounced in thick sections or even before these have been made, has vanished when the thinnest are examined. The inference would be that this may also hold good with regard to enamel.

It would seem that the dental histologist of the future must more closely combine microscopical technics with a profounder knowledge of anatomy and physiology.

Of the utmost importance to such an one are three great principles,—the selection of material, the preparation of that material for experimental and histological research, and the correct interpretation of results.

First, the selection of material which is about to form the basis of investigation must not only be confined to perfectly fresh tissues, but as far as it is possible to determine to tissues absolutely unaffected by morbid conditions. This may be exemplified by the study, say, of the histogenesis of the teeth in normal well-developed embryos and fœtuses as compared with the different stages and rates of growth in rachitic individuals of a corresponding age. Contrasting the appearance of the two conditions may throw useful light on both; but conclusions drawn from examination of diseased tissues erroneously believed to be healthy, can only give rise to false deduc-

tions and misleading statements. Loose plans of procedure unfortunately militate strongly against that advancement of the science which is so earnestly desired.

Further, the preparation of the tissues is all important. The quotation of one single instance, in itself sufficiently striking, will be enough. The discovery of the real nature and characteristics of Nasmyth's membrane has followed the employment of proper methods of preparation.

Thirdly, tissues having been properly selected and prepared, suitably stained and carefully mounted—the risk of shrinkage or swelling having been reduced to a minimum—must be scrutinizingly examined and carefully and critically interpreted. It was undoubtedly the precipitation of amorphous silver chromate salts (as in Golgi's method of staining) or methylene-blue granules which lead Mørgenstern and Römer to erroneously affirm the actual presence of amyelinic nerve fibres in the dentinal tubules and enamel. Check experiments must be conscientiously followed, and check stainings and methods of preparation adopted.

In conclusion, the original worker must be assisted in his accurate explanations of the meanings of the structures of cells and organs by keeping himself quite *en rapport* with the latest teachings of physiology and pathology. He will be most helped by devoting his attention to a preliminary thorough study of the knowledge we possess of the differentiated functions of cells; of the general principles that underlie and govern the physiological methods of tissue formation; of the metabolism of the cells forming the component parts of that tissue; and of the effects of pathological influences on the life-histories of the cells and other essential elements of the organs with which he has to deal.

CHAPTER II

NASMYTH'S MEMBRANE

MICROSCOPICAL ELEMENTS: (i) Cellular layer; (ii) Translucent pellicle

GENERAL CHARACTERISTICS

Definition.—A macroscopically-invisible cellulo-laminar film situated on the free surface of the adult enamel of man and certain animals.

Origin.—This tissue, which has recently been studied afresh microscopically, is now known to have its origin as an ectodermic formation of the epithelial cells of the enamel organ.

It is most probable that the cellular layer is derived from the external epithelium, and the pellicle or innermost layer from the spent cells of the internal epithelium, which have previously undergone a keratinous or somewhat analogous change.

With regard to its origin, R. R. Andrews ("The American Text-book of Operative Dentistry," p. 92, 1901), says that his investigations lead him to believe that the internal epithelium of the enamel-organ (ameloblasts) composes the cells of the membrane. These "having performed their function, have filled with calcoglobulin and have partially calcified, becoming somewhat like that tissue which we find on the borderland of calcification." That this is an entirely incorrect view is obvious when Paul's and the author's sections are examined.

Distribution.—Situated externally on the cortical aspect of the unworn enamel of man, monkey and sheep, is found under suitable conditions Nasmyth's membrane. It is a thin continuous tissue spread flat over the enamel, dipping into the naturally-formed pits and fissures on the surface, and limited in extent by the cervical portion of the tooth, to the edges of

which it is attached. *Synonym.*—The enamel cuticle. It has also been incorrectly termed “persistent dental capsule.”

Bödecker¹ considers that it is in direct union with the outermost epithelial layer of the gum, being therefore the only layer which closes up the space between the neck of the tooth and the adjacent gum.

In a well-developed adult premolar its measurements are 29 mm. in its widest part, 19 mm. in the narrowest, and 26 mm. round the cervical region of the tooth. All teeth possess the

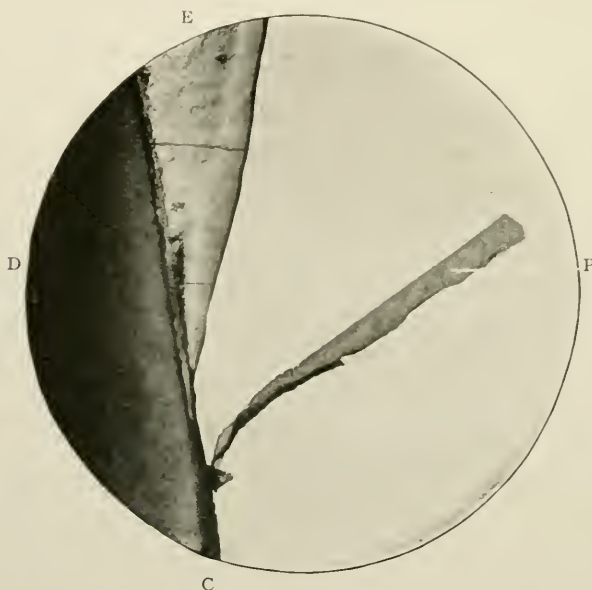


FIG. 1.—Nasmyth's membrane attached to the cementum. Prepared by decalcification of a ground section. Magnified 40 times. P. The membrane; E. Enamel; D. Dentine; c. Cementum.

membrane in a more or less complete condition. Even senile teeth when treated with a decalcifying solution to remove the enamel have traces of it, but it is best observed in those teeth which, while still unerupted (premolars, for instance), have been removed for the treatment of irregularities, because in this case the cellular layer is undamaged, though it may be injured during the act of extraction. Portions of the cellular layer may remain attached to the inner aspect of the

¹ “Anatomy and Pathology of the Teeth,” p. 43, 1894.

dental capsule, which as a rule comes away with the tooth. According to Kölliker it measures in thickness from 1μ to 2μ . This is probably erroneous, a measurement of 50μ being likely to be more accurate. Easily detached by the action of strong acids, it is only when Paul's method of preparing specimens is adopted that its real normal structure is ascertained.

HISTOLOGY

Nasmyth's membrane consists of two parts (i) an outer cellular portion, and (ii) an inner structureless translucent lamina or pellicle. These are both intimately adherent, not only to each other, but also to the free ends of the underlying enamel columns.

(i) *The Cells*

The cellular portion is interesting, inasmuch as its structure is made up of a layer or layers of large polygonal flattened epithelial cells, with pronounced nuclei. "The epithelial cells," writes Bödecker (*op. cit.* p. 92), "in transverse section, have the appearance of shallow spindles. Not infrequently there occurs also a stratified epithelium on the surface of the tooth. The enamel-fibres are in connection with these epithelial bodies which, if detached, show delicate offshoots adhering in regular intervals—the broken enamel fibres. Sometimes the surface of the enamel is coated by a thin uniform layer of protoplasm with regularly scattered nuclei. In such an instance single epithelia are not traceable, though scarcely any doubt can arise about the epithelial nature of this layer."

It is quite possible and most probable that the cells are more than one layer in depth. Preparations when correctly stained exhibit such a dense pattern of cells that this belief in the multiplicity of layers is probably well founded. It is doubtful, however, if more than three layers ever exist. The double or treble layers are not observed all over the surface of the pellicle, but only in those situations where the membrane dips down deeply into the pits or crevices of the enamel; and here too the pellicle itself is apparently thicker than elsewhere. The protoplasm of the cells is faintly granular. Under high

powers, the spongioplasm and hyaloplasm may be clearly defined.¹

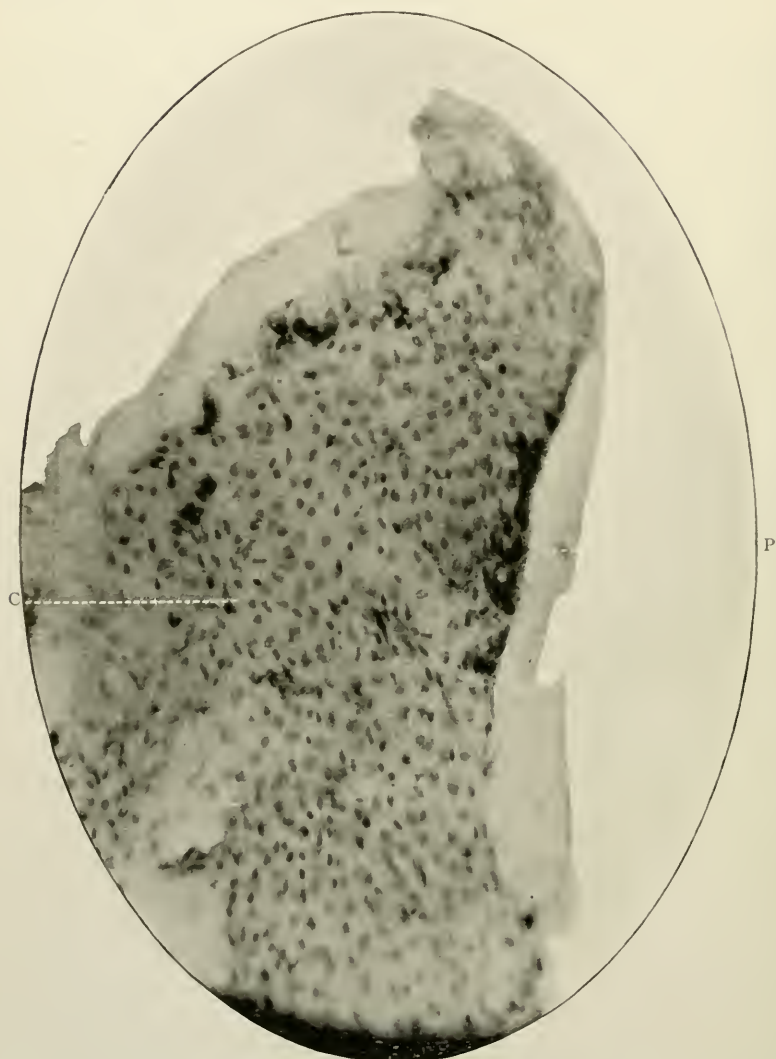


FIG. 2.—A piece of the thinnest portion of Nasmyth's membrane flattened out, and photographed from above. Its elastic nature made it impossible to critically focus it in all parts. Prepared by Paul's method. Magnified 200 times. c. Nuclei of the cells; p. Translucent pellicle.

¹ The "spongioplasm," according to Schäfer, is a reticulum or network of protoplasm in the cell substance; and "hyaloplasm" is the name applied to the material which occupies or fills its meshes.

Paul¹ attributes to the cells an average diameter of 12μ and a length of 25μ . Cells having "cogged" outlines—spiny cells—are seen constantly (Cf. Fig. 196): and in places the polygonal cells are flattened, probably by mutual pressure, in one or more lateral directions, and may thus assume a cubical or even cylindrical shape. The nuclei are particularly large compared to the size of each cell, are ovoid in shape or nearly round in outline, and possess faint nucleoli. These are usually single, and often contain in their interiors, as well as near their exteriors, one or more vacuole-like, bright, shining globules.

(ii) *The Pellicle*

The inner or subepithelial layer is a delicate continuous membrane, apparently without histological structure of any kind. It is translucent, elastic and cornified, and resists the action of acids in a similar way to the sheaths of Neumann or the linings of Haversian canals. On its under surface, *i.e.*, the part nearest enamel, a reticulated pattern can be fairly easily demonstrated. This corresponds to and is probably produced by the free ends of the enamel rods, which have left their hexagonal impressions on the membrane. It is to be noted that the hexagons of the pattern have sharp, clear margins made up of straight outlines, correspond in size to the diameter of the enamel rods, and in no way approximate the size of the epithelial cells which are "at least ten times too large for the enamel rods." (Paul.)

In sections of Nasmyth's membrane which have been obtained *in situ* it has been possible to find in the deep enamel-pits lacunæ similar to those of osseous tissue, surrounded by a capsule, and apparently associated very closely with the translucent layer of the membrane. Tomes² has repeatedly seen this condition. How these encapsuled cells get into the pits or fissures is not quite clear. There is an occasional appearance noticed in teased or spread-out pieces of the membrane of the cells being arranged concentrically round certain tiny spaces, and it may be that these represent in some way the

¹ "Nasmyth's Membrane." *The Dental Record*, 1894.

² "A Manual of Dental Anatomy," p. 123, 1914.

spots where encapsuled lacunæ may be deposited. A lacuna may perhaps represent a persistent retained and imprisoned cell of the *stratum intermedium* of the enamel organ where, owing to the formation of the cusps of the teeth, an involution

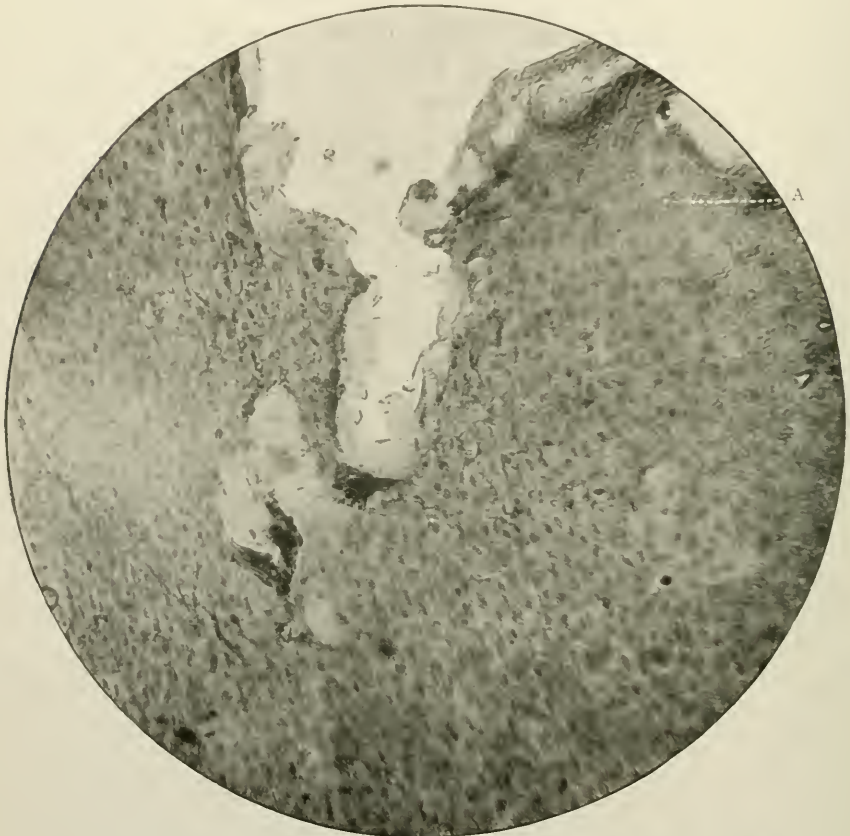


FIG. 3.—A thicker portion of Nasmyth's membrane than in Fig. 2. Magnified 200 times. A. Hexagonal impressions of the enamel rods.

of this layer of cells has taken place; or it may represent an aberrant osteoblast which has likewise remained unatrophied or unabsorbed.

Prof. Rodolfo Erausquin of the University of Buenos Aires, in a private letter to the author, expresses the opinion which is very plausible, that the so-called "encapsuled lacunæ" are, after all, merely vegetable cells introduced into the deep pits of

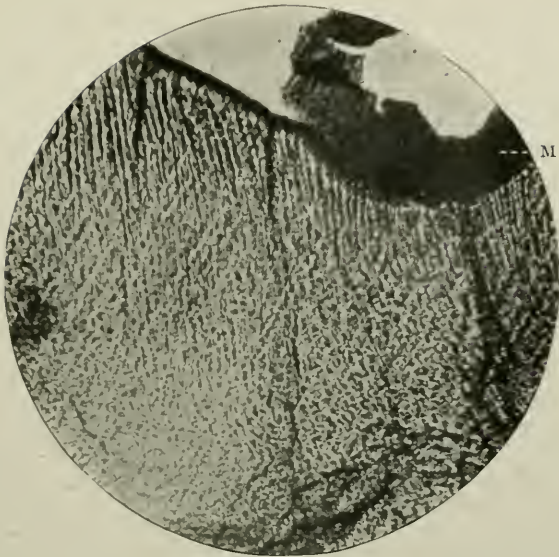


FIG. 4.—Enamel of a tooth, with Nasmyth's membrane on the free surface, removed from an oöphoronic cyst or teratoma. Ground thin and then decalcified. Unstained. Magnified 250 times. M. Nasmyth's membrane.

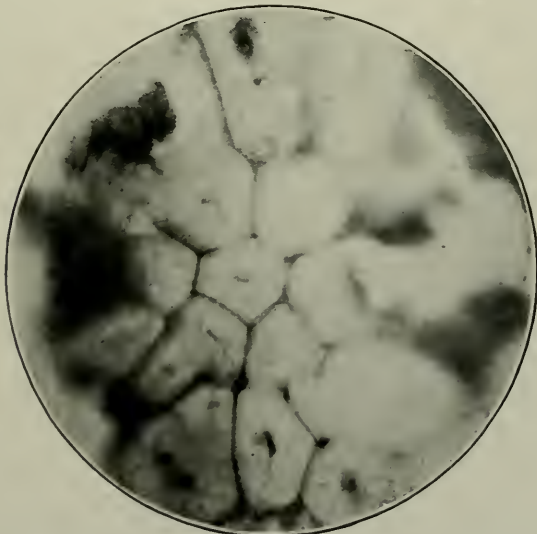


FIG. 5.—Vegetable cells found in a pit on the surface of human Nasmyth's membrane. Photomicrograph supplied by Dr. R. Erasquin.

enamel during the act of comminution of food, where they may be retained indefinitely. The accompanying photomicrograph adequately represents the microscopical appearances of such cells.

Fresh research on this matter is needed before a dogmatic opinion can be expressed.

It is now perfectly established that Nasmyth's membrane can be regarded with certainty as an epithelial remnant of the enamel organ, and thus the theories of Waldeyer, Röse, and others are to be considered correct.

From the enamel of recent teeth removed from ovarian teratomatous cysts, the pellicle can be isolated by careful decalcification.

It is absent, from the crowns of teeth found in follicular odontomes (*q.v.*), although, according to Warwick James, ("The Science and Practice of Dental Surgery," edited by Norman G. Bennett, 1914) this is not always the case.

CHAPTER III

THE ENAMEL

MICROSCOPICAL ELEMENTS: (i) Enamel rods and intercolumnar substance; (ii) Curvatures of rods; (iii) Brown Striæ of Retzius; (iv) Lines of Schreger; (v) Enamel "Spindles."

GENERAL CHARACTERISTICS

Definition.—The smooth, hard, glistening inorganic substance which partially or wholly envelopes the crowns or visible portions of the calcified teeth of the *Pisces*, *Reptilia*, and *Mammalia* classes of the *Vertebrata*.

Origin.—It is the final product of the layer of cells—the ameloblasts—which constitute the internal epithelium of the enamel organ. It is yet undecided whether enamel is a secretion or conversion of these cells, but the balance of opinion would seem to be in favour of the former.

Distribution.—Existing as (i) a tiny point or tip, as in the teeth of some members of the class *Pisces*, e.g., the order *Anacanthini*—*Merlucius vulgaris* (the hake), the order *Physostomi*, family *Murænidæ*—*Anguilla acutirostris* (the eel); or (ii) a partial investment of the cutting edges of teeth, such as those of the incisors of *Rodentia*, the lower canines of some *Bunodonts*, &c.; or (iii) longitudinal bands, as in the upper canines (tusks) of the wild boar; or (iv) an entire cap of varying thickness, which covers over the normally erupted parts of the teeth of mammalia generally,—except of the sub-order *Artiodactyla*, where a thick coating of cementum is developed in this situation,—enamel is the hardest tissue of the teeth or any of the organs of man and animals.¹

¹ In the mandibular incisors of the *Chiromyda* (e.g., the Aye Aye) enamel forms by far the greater portion of the teeth, exceeding in amount both dentine and cementum.

In man it intervenes between the translucent pellicle of Nasmyth's membrane, placed externally, and the periphery of the dentine which goes to make up the greater part of the tooth substance internally. Nasmyth's membrane is invisible macroscopically; at least it is unrecognisable, and, therefore, as this film becomes abraded the enamel becomes the most external of the dental tissues.

In the *Artiodactyla* it occupies a position (Fig. 6) between the cementum and the dentine.

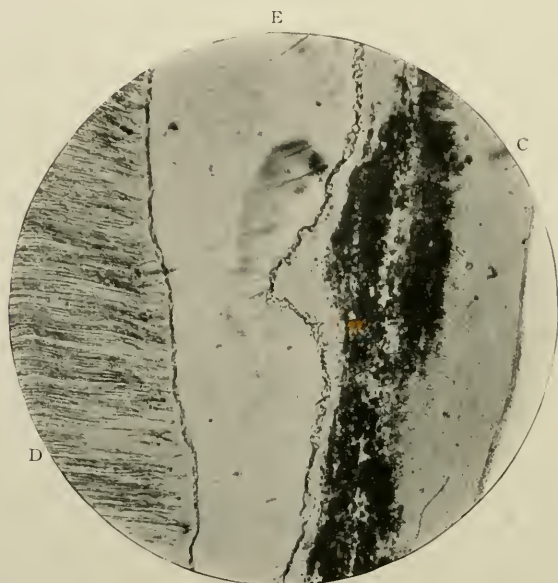

FIG. 6.—Vertical section of a molar of a young horse. Section ground thin. Unstained. Magnified 45 times. E. Enamel; D. Dentine; C. Cementum. 11

In sagittal (vertical labio-lingual) sections of the well-developed incisor teeth of man, unworn by attrition, it measures at the incisive edge about 2 mm. in depth; and then, as it gradually approaches the cervical margin, it becomes thinned down to zero. Over the cusps of premolars it is 2.3 mm., and over the cusps of molars it is 2.6 mm. in thickness.

The enamel of the deciduous teeth may be half the thickness of that of the permanent series.

At the gingival edge it may or may not slightly overlap the

thin structureless border of cementum. Monsieur Jules Choquet, who investigated (1899) the question of the anatomical relationships of the two tissues, in an interesting *brochure*

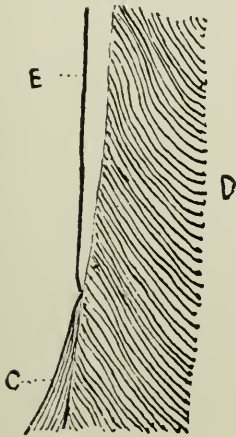


FIG. 7.

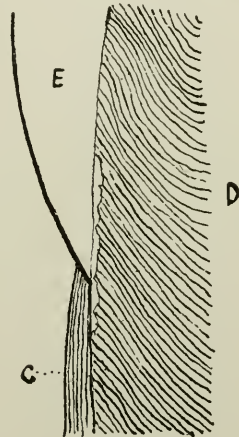


FIG. 8.

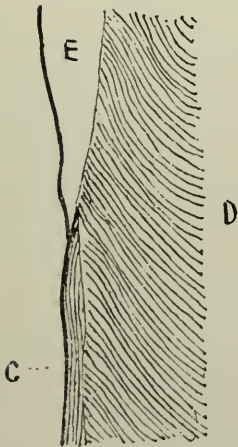


FIG. 9.

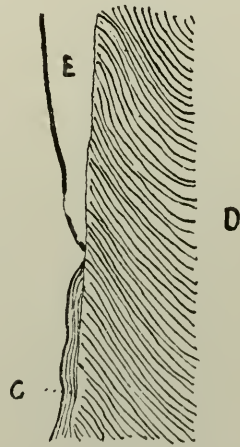


FIG. 10.

FIGS. 7, 8, 9, and 10.—Adapted from photomicrographs by Jules Choquet, and published by *L'Odontologie*, 1899. Semi-diagrammatic. Human. E. Enamel; c. Cementum; D. Dentine.

entitled "Note sur les rapports anatomiques existant chez l'homme entre l'émail et le ciment," has succeeded in throwing light on this subject. He examined and reported on twenty-nine human teeth; and found that the enamel covered

the edge of cementum eight times (Fig. 9), while the cementum overlapped the enamel seven times (Fig. 8). This author also reports that, in the majority of cases, the enamel and cementum meet each other, and there is no overlapping (Fig. 7). Out of his twenty-nine sections this occurred nineteen times. Thus the rule would be that the two tissues are in absolute contact, and both lie in the same plane without any involution whatsoever. Choquet further found that in 27.5 per cent. of the cases he examined, there was a breach of continuity of these two structures, leaving a minute portion of the dentine fully exposed (Fig. 10). His sections were cut longitudinally,

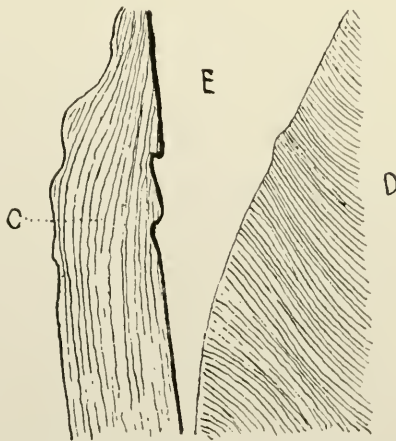


FIG. 11.—Vertical section of a Human tooth, from a photomicrograph. Semi-diagrammatic. E. Enamel; D. Dentine; C. Cementum.

and some were studied on both their aspects, whilst others only on one. “Cette différence tient à ce que dans certains cas il y avait eu fracture de l'émail d'un des bords pendant l'usure de la coupe.” There was often a diversity of method of ending of the tissues: thus, one section would have on its labial aspect the enamel overlapping the cementum, and on its lingual surface, the former internal to the latter. The teeth were representative specimens from young, old, and gouty subjects.

This subject has been re-examined by Thorsen (*Den Norske Tandlaege Tidende*, 1917,) who finds that enamel meets cementum edge to edge in 30 per cent. of cases; is covered by cementum in 60 to 65 per cent., and covers cementum in 0.5

per cent. In 5 to 10 per cent. the two tissues were not in contact.

On rare occasions, as in Fig. 11, from a section in the possession of Sydney Spokes, the margin of cementum may extend in a remarkable way, some considerable distance over the edge of enamel. From the structure of the tissue, consisting as it did of matrix containing many large lacunæ and incremental lines, it is important to point out the fact that the cementum was in no sense normal. The tooth, a mandibular third molar, was slowly erupting in an irregular manner.

Macroscopical Appearances.—Surface smooth, shiny, sometimes traversed by tiny vertical or horizontal depressions, occasionally scrobiculated and normally deeply fissured in premolars and molars, and pure white in colour. When fractured, pure white, non-lustrous.

HISTOLOGY

On microscopical examination Human enamel reveals many interesting structures. These may be described in the order of their importance as: (i) The striated columns and calcified matrix; (ii) The curvatures or courses of the rods; (iii) The brown striæ of Retzius; (iv) The lines of Schreger; and, (v) Certain spaces or "enamel spindles."

(i) *Enamel Rods* (Man)

Enamel is built up of minute solid calcified columns or rods, frequently hexagonal or pentagonal in shape, all united by a matrix or intercolumnar cementing material of somewhat different refractive index.¹ It is probable that the *real* shape

¹ It is extremely difficult to estimate the chemical composition of enamel. Hoppe-Seyler (*Handbuch d. Physiolog. und Pathologisch-chem. Analyse*, 1893) has the following formula: $\text{Ca}_{10}\text{CO}_3(\text{PO}_4)_6$, 95.35 per cent.; MgHPO_4 , 1.05 per cent. and so-called "organic substance," 3.60 per cent.; while Dr. Lovatt Evans (*Proc. Internat. Med. Congress*, 1913) thinks that in dried enamel of man the organic material amounts to 1 per cent. or 2 per cent., for he computed that 3.659 gm. contained 39.56 c.c. of gas consisting of carbon dioxide 30.21 c.c., and nitrogen 9.35 c.c.

The "organic substance," and "organic material" mentioned above are probably, as Tomes has shown, (*Dental Anatomy*, 1914, p. 34), only water combined with the lime salts.

of the columns is that of a solid cylinder. If an ameloblast could undergo complete segregation and continue its functional

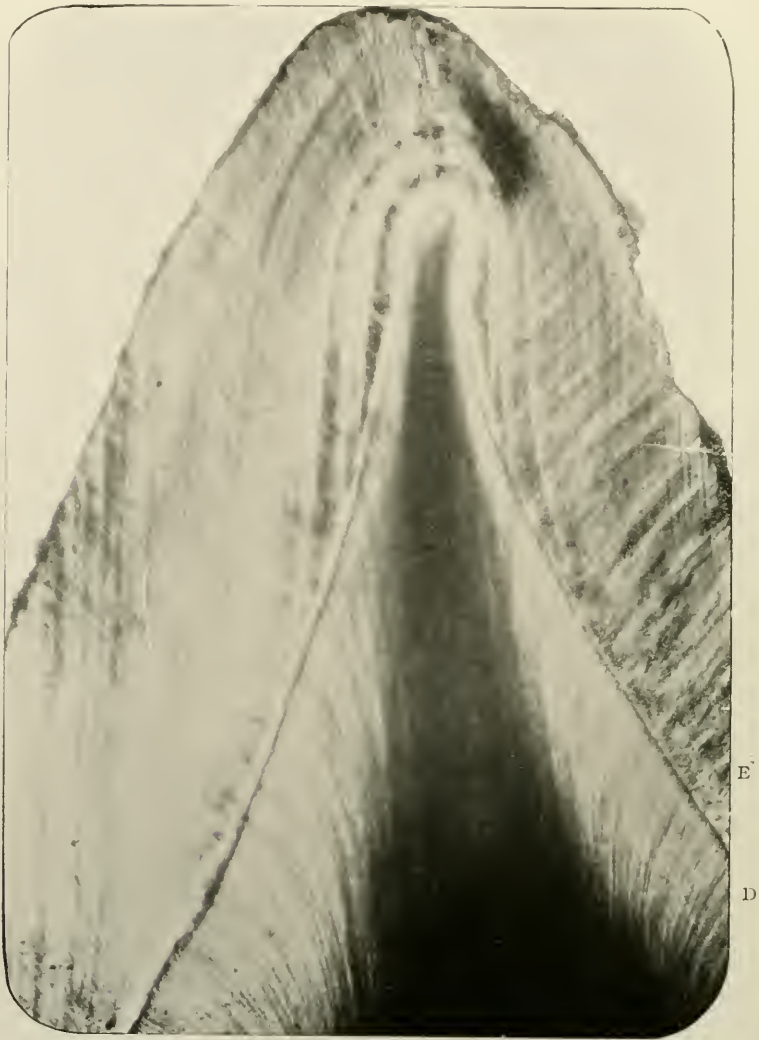

FIG. 12.—Sagittal section of the incisive edge of a Human incisor tooth. Ground thin. Unstained. Magnified 45 times. Shows the general pigmented appearance of the enamel. E. Enamel; D. Dentine.

activity a rounded rod would, no doubt, result. The hexagons are most likely produced by the lateral pressure of lengths of

contiguous rods, in much the same way as obtains in the six-sided cells of the bee's honey-comb (See Fig. 15). The



FIG. 13.—Sagittal section of the incisive edge of a Human canine tooth. Ground thin. Unstained. Magnified 45 times. E. Enamel; D. Dentine.

matrix is not a connective tissue ground substance; but merely a more or less perfectly calcified cementing substance.

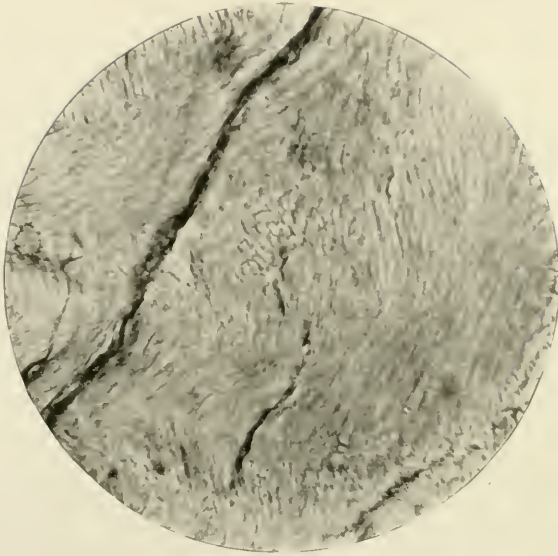


FIG. 14.—Human enamel. Prepared by grinding. Unstained. Magnified 250 times.

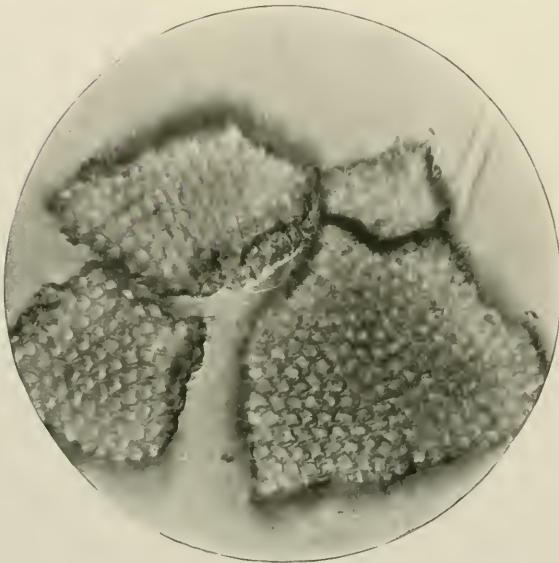


FIG. 15.—Enamel rods, as seen in transverse section. Decalcified and teased out. Magnified 500 times.

When isolated by means of the careful application of dilute acid solutions, the rods have their cementing substance dissolved and can then be examined critically (Fig. 16). They are absolutely solid in the adult or mature state, *i.e.*, when fully completed, rather flexuous or curved in contour, and measure .005 mm. (5μ) in diameter. Kölliker in "A Manual of Human Microscopic Anatomy," 1860, gives their breadth as 6.4μ to 5.1μ . Their length may attain to 2 mm. The outlines of

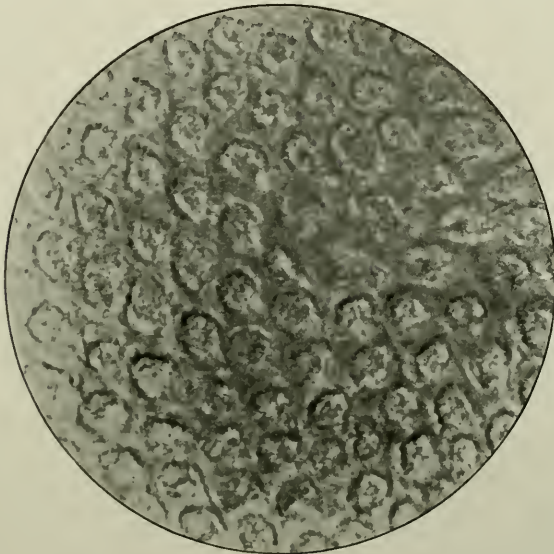


FIG. 16.—Transverse section of enamel rods, magnified 2,000 times.
Photomicrograph by Leon Williams.

the rods, in addition to being curved, are beaded, or very slightly varicose. Their long axes are, speaking broadly, placed at right angles to the surface of the tooth. Their inner extremities are inserted securely in tiny hexagonal depressions on the surface of the dentine: while their outer ends are free, and crop out of the periphery of the enamel itself, thus giving rise to imbrication lines on its cortical outer aspect, and probably affording close attachment to the pellicle of the enamel cuticle, to the hexagonal impressions of which they are ultimately and intimately fixed (see Fig. 3).

The term "imbrication lines" has been introduced by Prof. Pickerill of the University of Otago, New Zealand. ("The Prevention of Dental Caries and Oral Sepsis," 1912), to describe these outcrops on the surface of enamel of the free ends of the rods. He has clearly demonstrated the fact that, to a slight extent, the ridges and furrows of the enamel periphery




FIG. 17.—Section of enamel from Human tooth. Magnified 2,000 times. Dark ground illumination. Focussed in the middle of the section to show the granular calcified plasm-strings. The transparency of the cement-substance between the enamel rods is perfectly demonstrated in this illustration. Photomicrograph by Leon Williams.

are made up of the overlapping free terminations of the rods. Inasmuch as this arrangement resembles that which obtains generally in the disposition of the scales of a fish, or the tiles of a house roof, the term is very appropriate.

At regular linear intervals, and at distances varying from 5μ to 3.5μ , the enamel rods are crossed by distinct shadings

called transverse striæ or varicosities, which closely resemble the stripes of striated voluntary muscle fibres (Figs. 18 and 23). These striæ are only seen in longitudinal or oblique sections of the rods, and are ordinarily very faint. They are rendered more apparent by the action of dilute hydrochloric acid, and




FIG. 18.—Section of enamel from Human tooth. Magnified 350 times. Section prepared by Howard Mummery. The transverse markings of the enamel-rods are very pronounced. The enamel-rods are everywhere seen to be united by projecting processes. Photomicrograph by Leon Williams.

occasionally when a $\frac{1}{4}$ per cent. solution of chromic acid has been used. The markings are more clearly and easily seen in the outer portions of the enamel, and may be remarkably demonstrated in very pigmented or degenerated conditions of the hard tissues: they may be very indistinct, or even absent, in the region of the enamel near the dentine.

According to Bödecker the enamel is traversed by fibres of living matter located in the interstices between the enamel rods. The fibres are connected with one another by delicate fibrillæ, piercing the enamel rods in a vertical direction. Besides these rectangular unions, the basis-substance contains a minute network of living material which pervades it throughout its whole extent. The enamel fibres send conical thorns toward the

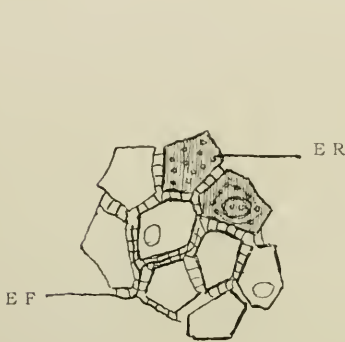


FIG. 19.

FIG. 19.—Transverse section of enamel, after Bödecker. Magnified 2,000 times. E.R. Rods of enamel; partly exhibiting formations like nuclei; the light interstices between the rods traversed by delicate beaded fibres; E.F. or by vertical thorns.

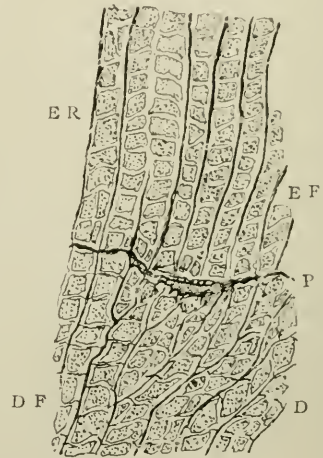


FIG. 20.

FIG. 20.—Longitudinal section of enamel and dentine, after Bödecker. Magnified 1,200 times. E.R. Enamel rod; E.F. Enamel fibre; D. Dentine; D.F. Dentine fibrils; P. Soft protoplasmic formations at the boundary between both tissues.

enamel rods, and such thorns are visible in all interstices between the enamel rods.

The enamel fibres are continuous on the outer surface with the covering layer of flat epithelium, and on the inner surface with the dentinal fibres. The connection with the latter is either direct or indirect through a network of living matter, or through intervening protoplasmic bodies in the interzonal layer (Fig. 19).

And also Abbott (*op. cit.* p. 95) has further given a drawing

showing the enamel-rods, the light reticulum within them, the intervening fibres, and the lateral off-shoots of the fibres.

The researches of Tomes, Leon Williams, and others, have, however, demonstrated the fallacy of such statements, and it must surely be an unpardonable hyperbole to affirm the existence of a chain of living material passing from the periphery of a tooth to its sentient pulp. The experiments of Tomes and Black have conclusively and for ever proved the inorganic nature of enamel.

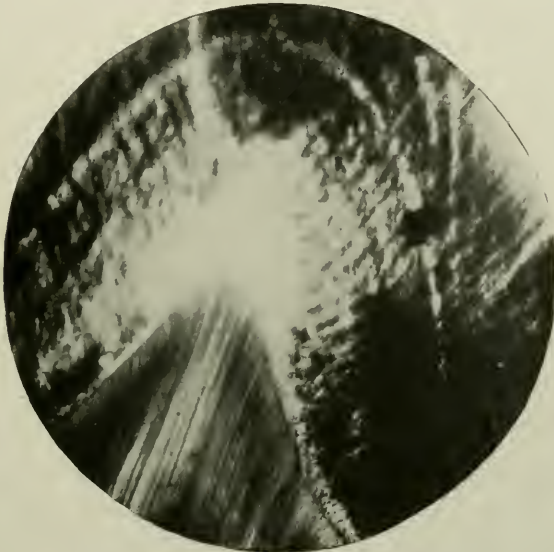


FIG. 21.—Vertical section of normal enamel treated by Golgi's rapid process. Magnified 45 times.

Nearly every section of normal as well as pathological enamel, whether ground and mounted in balsam or glycerine, whether stained or unstained, whether decalcified slightly with weak acid, like one per cent. citric acid, or prepared under conditions resembling Nature as closely as possible, reveals a certain degree of pigmentation. If, however, treated with Golgi's rapid silver chromate method, this coloration in normal ground sections is intensified.

The enamel of ovarian teeth, deciduous teeth, and nodules found on the necks or roots of teeth, exhibits also the pigmentation.




FIG. 22.—Longitudinal section of enamel from outer surface of Human incisor. Magnified 3,000 times. The structure of the calcified enamel-globules of which the rods are composed is very finely shown in this illustration. This section represents normal human enamel of the finest type. Photomicrograph by Leon Williams.

Of all investigators in the difficult subject of enamel histology, the name of Leon Williams will ever stand out pre-eminently. His magnificent work on the minute anatomy as well as the pathology of this tissue is well known, and he has contributed probably by far the greatest amount of knowledge on the matter.




FIG. 23.—Longitudinal section of enamel from Human tooth. Magnified 1,000 times. Shows enamel-rods passing through Retzius bands without break of continuity. The rods are separated by rather more than the normal amount of cement-substance, and show imperfect formation in lower right-hand corner. Photomicrograph by Leon Williams.

According to this author¹ enamel rods are constructed by the successive deposition of certain "bodies" formed in the enamel cells, a deposition which goes on with the utmost order and regularity. The rods possess a more or less definite

¹ "On the Formation and Structure of Dental Enamel." *The Dental Cosmos*, 1896.

organisation. These "bodies" are beads of granular material, which, under high magnification, are joined together by calcified plasmic strings and processes (Figs. 17 and 22). They lie exactly opposite each other, and the granular strings are larger and more clearly defined on the extreme margins of the enamel rods. Thus Leon Williams has demonstrated indubitably that the "bodies" are connected vertically by plasmic strings of granular origin which traverse the entire length of the rods; that they are also united to the bodies of contiguous rods by radiating processes, or even touch one another at the points of the greatest diameter of the rods; that there may be as many as fifteen or twenty calcified plasmic strings in each enamel rod; and that their ultimate structure is most suitably revealed by the action of weak acids, such as citric in lemon juice, which first removes the connecting threads.

The Cementing substance or matrix varies considerably in amount. In the majority of cases, in the teeth of man, the rods are more or less in actual contact throughout their entire course, being united by the varicosities or bodies: but in some sections they lie quite apart, separated sometimes by matrix which may equal one-fourth or one-fifth the diameter of a column (*viz.*, 1μ), (Fig. 16). This translucent intercolumnar, calcified substance has in it delicate connecting lateral processes and fine, tiny granules, and does not contain either the organic fibres, which Bödecker¹ and Abbott² affirm pass between the rods and give off "thorn-like" processes, or the channels which have been described by von Ebner³ (Fig. 19).

Otto Walkhoff,⁴ *ex cathedrâ*, refuses to grant that this cement substance exists. He examined the enamel rods of certain *Primates*, *Carnivora* and *Ungulata*, in which the structural elements of the tissue are regular. He affirmed that vertical sections of enamel never give, for great distances, the con-

¹ "The Anatomy and Pathology of the Teeth," 1894.

² "Minute Anatomy of the Human Tooth" in *Trans. Dent. Soc., New York*, 1882.

³ "Histologie der Zähne" in "Handbuch der Zahnheilkunde," 1891.

⁴ "Contributions relating to the more minute structure of the Enamel, and to the Development of Dentine." *Deutsche Monatsschrift für Zahnheilkunde*, Jan., 1898.

tours of the rods in one plane, and that observations on such sections are untrustworthy. When magnified 3,500 times, a measurable, thick, doubly coloured stripe was seen: viewed horizontally, the rods, at a magnification of 2,400, exhibited no cement substance. He wrote: "A series of photomicrographs with the apochromatic 1.9 mm. oil immersion, objective N.A. 1.40, showed that enamel rods consist of two parts optically distinctly divided from each other. The central part, or real body of the rod, is grainless, or, at the most, slightly spotted, but darker coloured than the peripheral layer, which appears whitish. A delicate, somewhat darker line forms the border between the two layers; the outer border lining the whole column, which appears somewhat blacker, is sharply sectioned, even with high magnifications. Such pictures are produced only when focussing has been *most exact*, and where possible has been directed to the surface of the rod. In its surroundings there are immediately seen, if there is the slightest obliqueness in the section, diffraction seams, especially if oblique illumination has been used. With *inexact* focussing the picture totally changes. Between the rods there is then shown a line which appears dark, which by increasing the inexactness grows in width. What previously was light now becomes dark, and such a picture gives only too well the delusion of cement substance between the enamel rods."

A recurrence to the belief in the existence of an organic matrix in the structure of enamel has been furnished in the pages of the *Deutsche Monatsschrift für Zahnheilkunde*, August, 1902, by Viggo Andresen of Vejle, Denmark. His paper ("Beitrag zur Histologie des Schmelzes") is, however, inconclusive, and his illustrations unconvincing.

It is interesting to note the various opinions and theories in connection with the histology of enamel and its rods.

Thus:

Abbott says that "normal enamel is non-striated."

Sudduth¹ denies that the rods have any internal structure.

von Ebner believes in the existence of the striæ but considers they are an artificial appearance, due to the action of acids.

¹ "Dental Embryology and Histology" in "American System of Dentistry," 1887.

The propositions advanced as to the origin of the shadings or transverse markings are:

- (i) An intermittent calcification of the rods would produce the dark and light bands. (Hertz.)
- (ii) They are due to the existence of beads or varicosities in the rods. (Kölliker, Waldeyer, Haycraft, Ewald, and Leon Williams.),
- (iii) Or to inequalities on the surfaces of the rods. (Sudcluth and Febiger.)

(ii) *The Courses or Curvatures of the Rods*

Individually each rod runs a more or less spiral course and often decussates with its neighbours, so that it is exceedingly difficult, if not impossible, to trace its entire course.

Collectively, the courses are neither perfectly straight nor perfectly parallel. At the cervical region they run horizontally outwards from the dentine; at the cutting edge or the masticating surface they are chiefly set vertically with it. They thus radiate outwards all round. According to Tomes, "Dental Anatomy," 1914, p. 40, "On the whole the rods are parallel and run from the surface of the dentine continuously to that of the enamel. Their paths are not, however, either perfectly straight or perfectly parallel; for alternate layers appear to be inclined in opposite directions, while they are also wavy, forming several curves in their length. The curvature of the rods is most marked on the masticating surface: while the layers, alternating in the direction of their inclination, as just described, are in places transverse to the long axis of the crown, and correspond to the fine imbrication lines on the surface of the enamel, which appear to be caused by their outcrop. The curvatures take place in more than one plane; in other words, the course of the individual rod is more or less a spiral."

A general idea of the courses of the rods may be obtained by macroscopic examination of a section.

(iii) *The Brown Striæ of Retzius*

Nearly every longitudinal section of enamel exhibits in a more or less degree these stripes. They appear as shadings

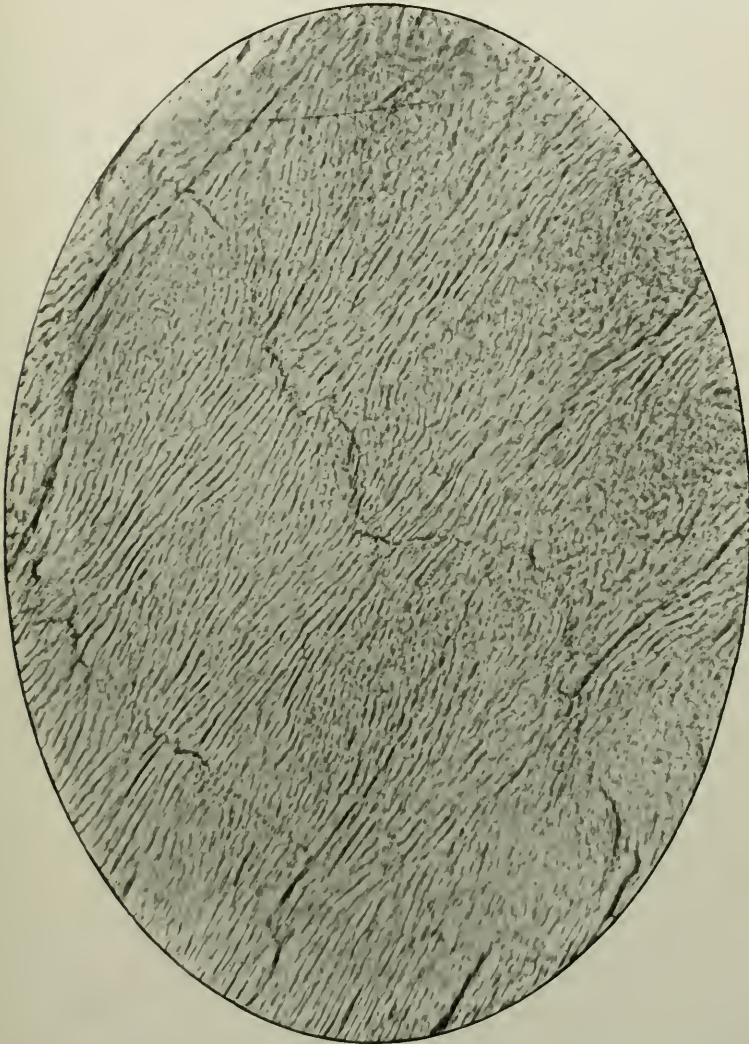


FIG. 24.—Vertical section of Human enamel. Unstained, and non-decalcified. Magnified 250 times. The lines which run across the rods are cracks in the tissue produced by grinding the section.

or brown markings, arranged in the form of arcuate stripes; and they maintain a certain amount of parallelism to the

boundary-line of enamel and dentine, which may be called the amelo-dentinal junction (Fig. 25). Crossing the columns in various planes and in various directions, they are more pronounced on the cortical portions of the tissue, but extend right up to the junction. Between thirty-six and forty have been counted as crossing a segment of enamel, but the number varies very greatly. The bands are interrupted partially or com-

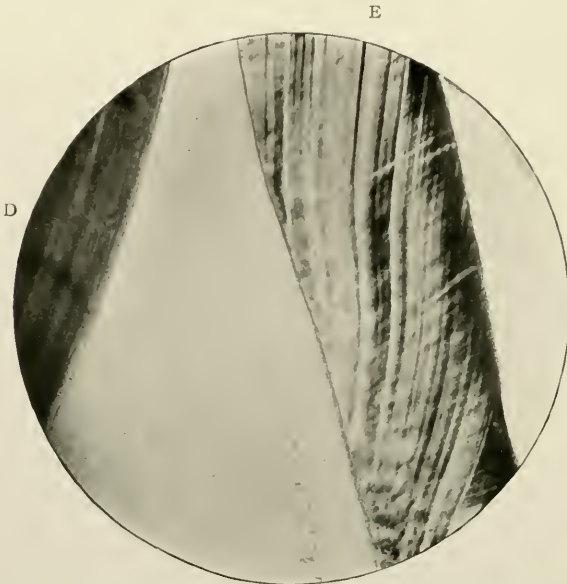


FIG. 25.—The Brown Striæ of Retzius in enamel. Prepared by grinding thin. Unstained. Magnified 40 times. E. Enamel; D. Dentine.

pletely. Sudduth calls them “the *broken striæ*,” etc. Many are broad and many are narrow, the thickest and most marked of the former measuring sometimes, roughly, one-fifteenth part of the whole thickness of the enamel. These stratifications are only visible in vertical sections. Horizontally, the stripes are cut obliquely or transversely, and thus are seen as concentric bands, darker and more distinct at the edge than near the dentine; and therefore they give the enamel a more or less lamellated appearance.

The striæ of Retzius are due to pigmentary deposition in the rods. The theories propounded by von Ebner and Kölliker

have been dismissed by Leon Williams as incorrect. The former observer supposes that the bands are due to "imprisoned air or gas which has entered the ground-off ends of the rods through minute channels." And to this Leon Williams replies (*op. cit.* page 475) that the idea is a mistaken one, "first, because the supposed canals have no existence; secondly, because the ground-off ends of enamel rods do not appear except when the section of enamel is ground at a certain angle."

According to Walkhoff (*loc. cit.*) the striæ of Retzius are nothing else than the ordinary transverse striping of the enamel rods on a large scale. He declares that both striæ are the expression of the deposition by the lime salts of the enamel-tissue strata-wise, a longer lasting interruption of the calcifying process producing the Retzian stripes, and one short, often-repeated, the transverse striæ of the prisms.

Thus the brown striæ of Retzius have been attributed in their origin to:—

- (i) The lamellated mode of formation of the enamel; (Kölliker, Walkhoff.)
- (ii) The entrance of air into cavities between enamel rods; (von Ebner.)
- (iii) The varying character of food taken by the mother during the period of gestation, some food being rich in lime salts of one kind and some rich in salts of another kind; ("American System of Dentistry," p. 656, 1887.)
- (iv) And finally, and correctly, pigmentation. (Leon Williams.)

(iv) *The Lines of Schreger*

By reflected light, as well as by transmitted light, it is often possible to distinguish in ground perpendicular sections of the teeth of man, entire band-shaped layers of rods alternately decussating in such a manner as to produce lines. By the former, they appear white, by the latter black, as in the photomicrograph. These differ very markedly from the striæ of Retzius, inasmuch as they run transversely to them (Fig. 26)

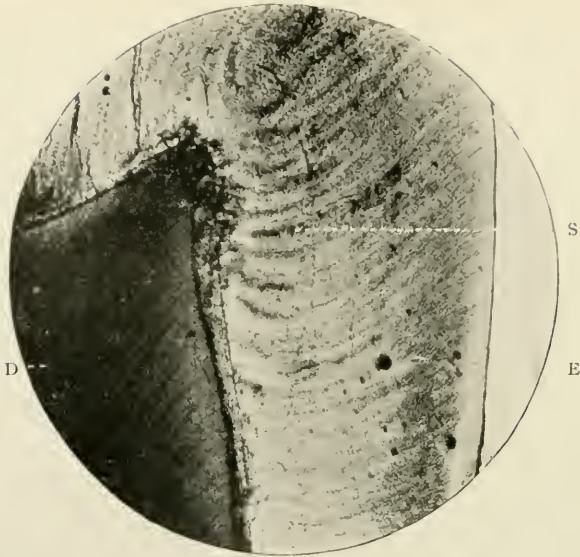


FIG. 26.—Vertical section of Human enamel shewing the lines of Schreger. Section ground thin. Unstained. Magnified 45 times. E. Free surface of the enamel; S. Schreger's lines; D. Dentine.

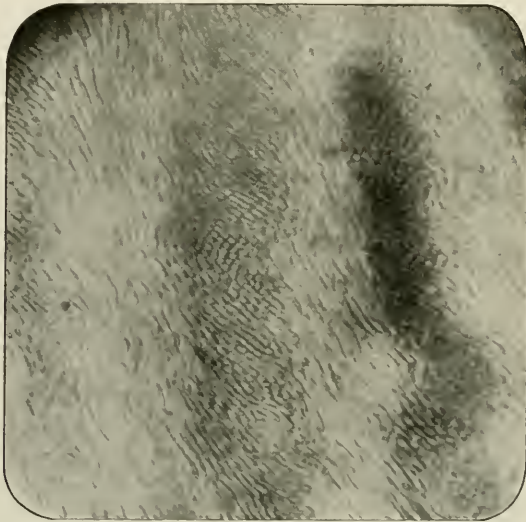


FIG. 27.—Same as preceding figure. Magnified 250 times.

and are long, level, very broad bands, which bear some resemblance to flat clouds (Fig. 28) of the cumulo-stratus type. All sections by no means exhibit them; but those specimens which do, commonly shew them most clearly and distinctly. They blend together, and therefore form blackish masses in the enamel. They may be distributed anywhere throughout the thickness of the tissue, but very often are confined to its inner aspect, particularly at the cusps of premolars and molars.

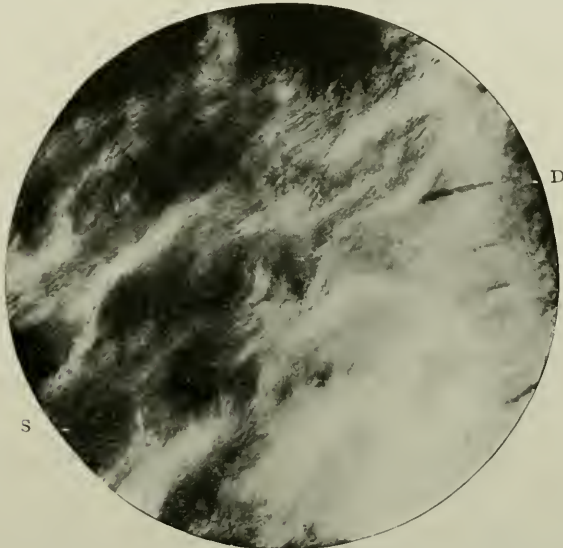


FIG. 28.—Schreger's lines in enamel, as cloud-like masses through dense pigmentation. Magnified 300 times. S. Schreger's lines; D. Dentine with enamel spindles.

High powers reveal the fact that the rods are histologically normal, and it is only low magnifications which make apparent their occasional lengthwise groupings.

(v) *Certain Spaces or "Enamel Spindles"*

Independent of certain cavities or clefts on the free surface of enamel, which have no special structure, there can often be found in teeth free from any apparent structural defects, near the amelo-dentinal junction, irregularly shaped chasms, which in ground sections are remarkably clear and brilliant (see Fig. 31). They appear to be in direct continuity with

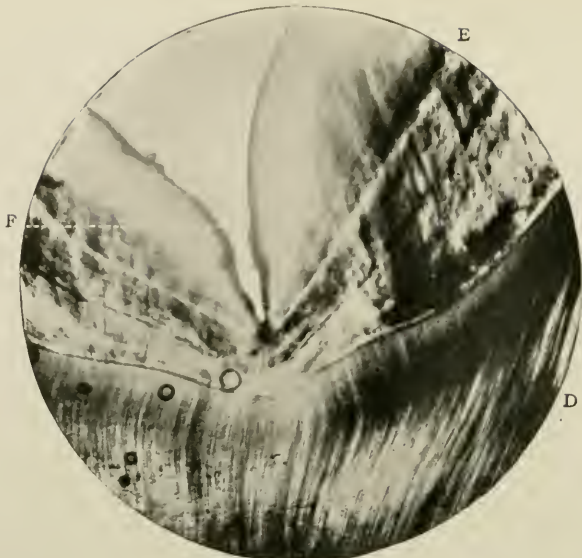


FIG. 29.

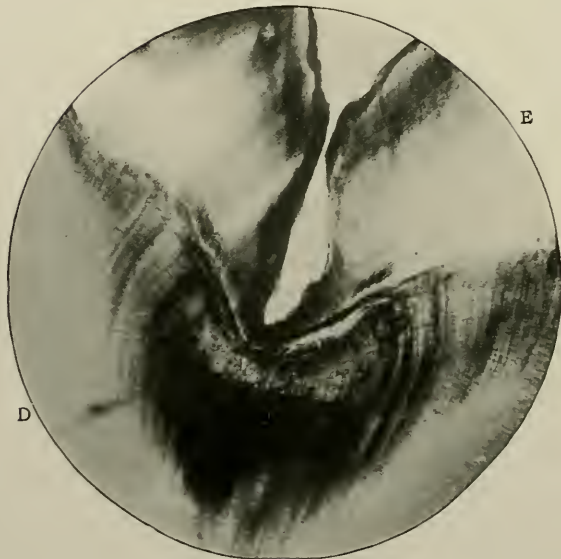


FIG. 30.

FIGS. 29 and 30.—Vertical sections through cusps of Human molar. Stained with Golgi's rapid process. Magnified 45 times. E. Enamel; D. Dentine; F. Fissure with clear structureless margins.

those few dentinal tubes which manage to cross the boundary line of the two hard tissues. In fact they resemble bulbous enlargements of the tubes (Fig. 32). Situated between the rods, in the cement substance, which, according to von Ebner, and quoted by Römer in his "Zahnhistologische Studie," 1899, p. 39, is more abundant near the dentine than the cortex, they run vertically outwards, are narrow, and about 40μ long. They may be clubbed or spindle-shaped.

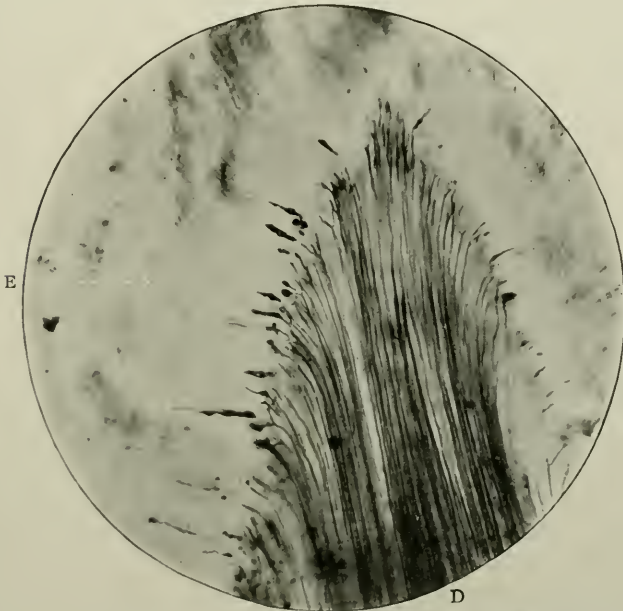


FIG. 31.—Vertical section through cusps of tooth. Magnified 50 times. E. Enamel; D. Dentine, many tubes of which end in the enamel spindles. Photomicrograph by Douglas Gabell.

These spaces are not infrequently observed in vertical ground sections of molars or premolars.

In the margins of the apices of the dentine cusps (Fig. 33) they are more numerous than in the saddle-shaped depressions between them, in which situation they are only to be met with singly or in sparse numbers. The knobs sit on the dentinal tubules exactly like ears on the stems of the straw of corn bound up into sheaves. Those found in the highest parts of the cusps appear to stand upright; while on the con-

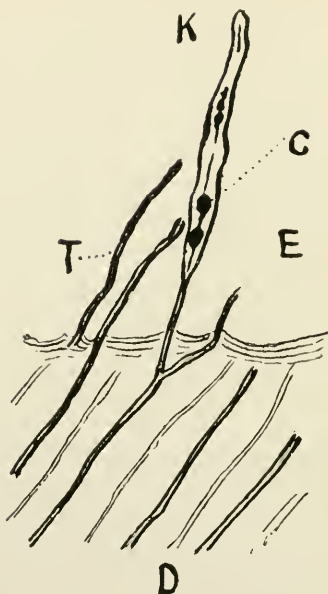


FIG. 32.

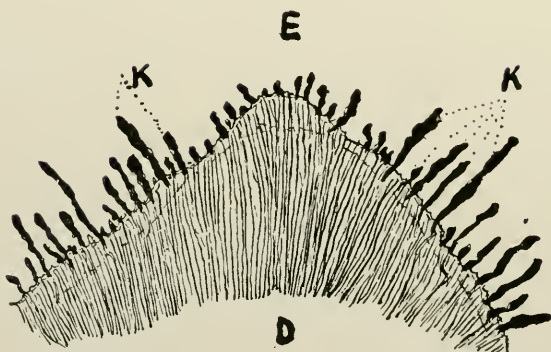


FIG. 33.

FIGS. 32 and 33.—Adapted from two drawings by Kretz, in Römer's "Zahnhistologische Studie," 1899. FIG. 32.—Vertical section through amelo-dental junction in molar of a child, stained with gold chloride, and potassium iodide. Magnified 1,500 times. D. Dentine; E. Enamel; T. Dentinal tube; K. Enamel spindle; C. Dark red corpuscle in the interior of the enamel spindle. FIG. 33.—Vertical section through the amelo-dental junction of a cusp of a left maxillary first molar of a boy, aged 13 years. Stained as in last Figure. Magnified 250 times. E. Enamel; D. Dentine; K. Enamel spindles.

trary those at the slopes incline more or less to the horizontal plane. Thus, in a longitudinal ground section through the middle of the cusp they are cut perpendicularly, whereas in a tangential ground section going through the lower portion they are found for the most part cut transversely.

In sections ground in the ordinary way, and subsequently treated in the usual manner, these enamel-knobs stand out black or dark grey on a light background. There is no internal structure visible, the space being filled with detritus, etc., from the act of grinding.

Whether protoplasm ever filled them is a difficult matter to decide. It is probable that in the fresh condition it did.

Various accounts are given by different authors as to their histological characteristics, amongst whom Tomes, von Ebner,¹ Höllander,² Wedl,³ Bödecker,⁴ and Oscar Römer⁵ may be cited.

Charles Tomes (*op. cit.* p. 49) makes no mention of their contents, and concludes that "perhaps they are to be regarded as pathological."

That hollow spaces constitute these enamel-spindles von Ebner and Wedl are agreed: but the former holds that they contain air, and the latter that they are filled with amorphous dark calcareous masses. von Ebner thinks they are actually produced by the shrivelling up of the cement substance, which is more easily possible at the amelo-dentinal line than at the free surface of the tissue. Höllander describes their presence in the juxta-dentinal zone of enamel, but regards them as non-pathological. Bödecker says "They invariably contain protoplasmic bodies of distinctly reticular structure and sometimes one or more compact clusters, which may be spoken of as nuclei. The spindle-shaped corpuscles stand at their central terminations in direct connection with the ends of the dentinal *fibres*, as these originated from repeated branchings. At many places, especially those corresponding to the crown apices, the spindle-shaped enlargements of the dentinal fibres are very numerous,

¹ Scheff's "Handbuch der Zahnheilkunde," Vienna, 1891.

² "Die Anatomie der Zähne des Menschen und der Wirbelthiere," Berlin, 1877.

³ "Pathologie der Zähne," Leipzig, 1870.

⁴ Heitzmann's "Mikroskopische Morphologie," Vienna, 1883.

⁵ *Nerven in Zahnbein*, "Zahnhistologische Studie," Freiburg, 1899.

and nearly regular in size and direction. . . . In the teeth of younger persons the spindle-shaped swellings are relatively larger and more regular than in those of older people." This is called the "Bio-plasson theory."

Römer coincides on the whole with Bödecker's view, with the reservation that he would apply the term "dentinal tubules," instead of "dentinal fibres," to those formations which widen out into clubs or spindles in the enamel. He declares that the spaces contain an organic matter capable

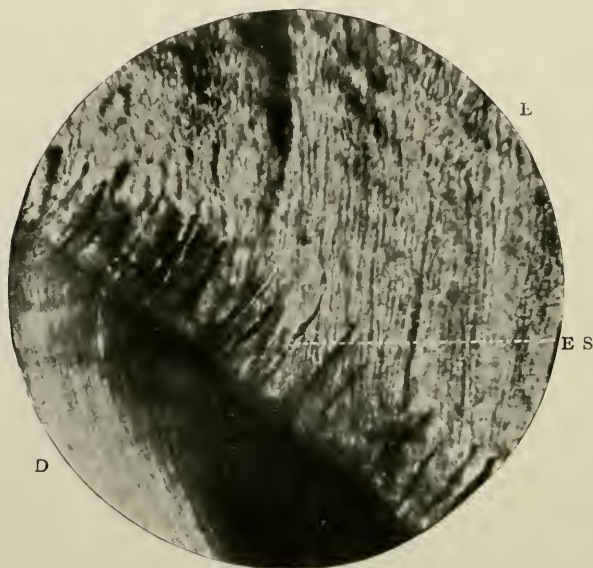


FIG. 34.—Vertical section through the coronal part of a tooth. Prepared by Weil's process. Magnified 250 times. E. Enamel; D. Dentine; E.S. Enamel spindle critically focussed to shew Römer's corpuscles.

of becoming stained with chloride of gold, and appear of a reddish tint, varying from a rose-colour to a dark-red hue (marked C in Fig. 32). He admits that in most cases they are merely filled with air, through the shrinking of some of the organic material; but affirms that when teeth are treated by the Koch-Weil method there is no shrinkage, and that a non-reticulated organic substance is really present inside the knob. He describes and figures (Fig. xxxiii., Tafel vii.) in one space "several spherical corpuscles hanging together by a fine,

scarcely measurable fibre, also stained dark-red and running out into a fine point" (see Fig. 32, also Fig. 34). In conclusion, he writes:—"I should not, however, call these round or oval corpuscles cell-nuclei, as Bödecker does; especially I cannot, like him, in defending his 'Bio-plasson' theory, testify to a connection between these knobs and 'the living enamel material;' but I think we should much rather venture to see in these fine corpuscles, so often arranged in rosary-like order, *sensitive nerve-end apparatus* of the nerve filaments which run in the dentinal tubules." For the arguments which Römer advances in favour of this extraordinary hypothesis, see his paper.

The tubes of the dentine themselves often traverse the boundary line and penetrate the enamel sometimes to a depth of 30μ . They run in the cement substance, not in the interior of the rods.

Before altogether dismissing these theories, one or two more instances may be given of other opinions on this most interesting subject.

F. T. Paul (*The Dental Record*, p. 495, 1896) explains their occurrence in this manner:—"In early mammalian tooth-germs, the ameloblasts and odontoblasts are seen to be separated by a thin band of transparent dentine matrix, due to certain changes in the surface of the pulp. This band has two sets of processes of formed matrix. One, as Howard Mummery first showed, passes between the odontoblasts to communicate with the connective tissue matrix of the pulp, and the other extends outwards between the ameloblasts, which, in some instances, are therefore kept apart, and thus form elongated spaces filled with the imperfectly calcified matrix of dentine. "That processes of dentine matrix thrust up between the enamel rods should never calcify, is certainly nothing surprising when one remembers that the first layer of dentine usually only calcifies imperfectly, being characteristically the site of the interglobular spaces of Tomes.'"

Waldeyer (in Stricker's "Handbuch der Lehre von den Geweben," Leipzig, 1871) denies that the spindle-shaped spaces in enamel exist at all, as structural elements, either as develop-

mental errors or pathological lesions. He bases his view on the assumption that the least defect in the parallelism of the sections would be likely to lead to incorrect appearances. Cracks or fissures in the enamel, produced by manipulative interference, would also yield deceptive results. Hertz, too, another of the earlier investigators, interpreted the meaning of these spaces in a similar way.

But Walkhoff¹ has often seen them.

One of the most difficult problems in the whole of dental histology is that connected with the relationship of enamel and dentine; for not only is it hard to conceive how enamel, an ectodermic substance, should be so securely fixed on the surface of a mesodermic substance, and by what means they are thus bound together; but the transpiercing of the amelo-dentinal boundary by the dentinal tubes is infinitely still more perplexing. Walkhoff has published (*op. cit.*) an ingenious hypothesis in attempting to explain this phenomenon. In common with Wedl (*op. cit.*) and von Ebner, he assumes that at this border-line there must have been an absorption of the first deposited dentine. His arguments in favour of this are founded on the facts that under the enamel, Tomes' granular layer is never seen, because, though once existing, it has in the process of time become absorbed: that the dentinal canals run up to the edge without much narrowing of their diameters, thus apparently proving that they have been diminished in *length*: and, finally, that here, too, there are practically no branchings, these having disappeared in consequence of the resorptive process.

Granting that the interpretations of these phenomena are correct, he proceeds to explain that, owing to an especial vitality on the part of certain individual tubes, they are enabled to completely resist the absorption of the defectively built dentine which is going on all round, remain *in situ*, and, therefore, have the appearance of actually projecting beyond the amelo-dentinal junction. Walkhoff adds that the canals appear as if sharply cut off, a proof that their terminations are absorbed.

¹ *Deutsche Monatsschrift für Zahnheilkunde*, January, 1898; also "Die Normale Histologie Menschlicher Zähne," Leipzig, 1901.

The direction of their courses is not always parallel with the enamel columns, because they frequently break through the rods transversely. There occur formations (the enamel-knobs) at the apices of the dentine cusps in the teeth of *Primates* and *Carnivora*, which may reach far into the enamel, and do not consist of simple dentine tubes, but may have round them a large amount of uncalcified basis substance or matrix.

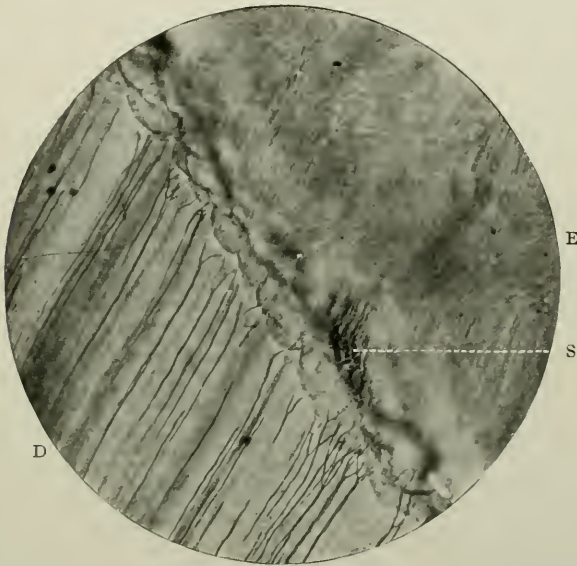


FIG. 35.—Vertical section through coronal region of a tooth, shewing the amelo-dentinal junction. Prepared by grinding. Unstained. Magnified 250 times. E. Enamel; D. Dentine; S. Granular enamel rods of irregular formation.

Walkhoff summarises his investigations by asserting that the club-like processes represent simple dentinal tubes, which, through unusual vitality, have opposed sufficient resistance to the absorption of the dentine, which takes place during the formation of the enamel; and that there were certain masses of basal substance already formed round each tube which the resorption was unable to destroy.

The amelo-dentinal line, junction, or boundary, is made up of a fairly straight or slightly undulating line with pale homogeneous tissue on either side. The tubules do not end on the line, but near it, while the enamel rods themselves are struc-

tureless or faintly granular. This condition obtains in horizontal sections of premolar and molar teeth taken at the cervical margin, and at the narrow part of that margin. In its broadest part the boundary is represented by a linear series of tiny enamel convexities looking towards the dentine. Here the tubules are strong and thick and come quite up to the edge of the convexities, and the structure of the enamel convex surface is pale, bright, and glistening when viewed by transmitted light (Fig. 35). The enamel in the immediate neighbourhood is translucent and structureless.¹

The same appearance is found in vertical sections, but the enamel crescents are more constant. They closely resemble that edge of the layer of formed but uncalcified dentine—the dentogenetic zone—in developing teeth which is in juxtaposition to the calcified dentine.

As has been already stated, tubules from the dentine with or without their bulbous enlargements occasionally cross this border.

¹ It is of great interest to note that when sections of sound teeth have been subjected to impregnation with coloured collodion, as first advocated by Charters White, isolated patches of the enamel of this region may become stained. (See Fig. 35.) This often occurs, and may show that the chemical properties of the enamel are different here. The fact may probably throw some light on the actual method of production of secondary enamel decay; and may be regarded as an evidence of degeneracy of human enamel.

CHAPTER IV

ORTHO-DENTINE

MICROSCOPICAL ELEMENTS.—(i) Matrix; (ii) Tubes; (iii) Sheaths of Neumann; (iv) Interglobular spaces; (v) Granular layer; (vi) Schreger's Lines; (vii) Contour lines of Owen; (viii) Laminæ. Secondary dentine.

GENERAL CHARACTERISTICS

Definition.—That hard tissue¹ of the tooth, which, while comprising its greatest bulk, forms the natural boundary of its pulp.

Varieties.—There are four varieties:—Ortho-dentine—hard or unvascular plici-dentine, vaso-dentine, and osteo-dentine. This is Tomes' classification. Dr. Med. C. Röse,² of Leipzig, basing his opinion on the definition of dentine as “a hard tissue with a smooth surface, which is developed under an epithelial sheath (enamel organ), and grows on one side only,” groups the different kinds under the headings of (i) “Normal tubular dentine,” (ii) “Vitro-dentine” which contains *no* protoplasmic processes, (iii) “the Vaso-dentine of Tomes,” and (iv) “Trabecular dentine.” The latter—a new term—is defined as “a hard tissue, rich in short dentinal canals, and capable of increase in all directions; but not growing immediately beneath, and in dependence upon an epithelial sheath.” Here will be considered the first-named variety, viz., hard dentine, or, more correctly, ortho-dentine.³

¹ According to Gallippe (*Comp. Rend. des Séances et Mémoires de la Société de Biologie*, 1884) the chemical constituents of dentine are as follow: Phosphoric acid, 23.70 per cent.; Calcium, 45.11 per cent.; Magnesium, 1.67 per cent.; Magnesium Carbonate, 1.13 per cent.; Calcium Carbonate, 0.35 per cent.; Silicates, 0.41 per cent.; Alkaline chlorides and phosphates, 0.54 per cent.; water and organic matter (probably collagen), 25.29 per cent.; and an unknown salt, 1.8 per cent.

² “On the various alterations of the Hard Tissues in the lower vertebrate animals.” From the *Anatomischer Anzeiger*, 1898. (Bd. xiv., Nos. 1, 2, and 3.)

³ In the following pages the use of the word “dentine” is applied to the commoner variety, viz., ortho-dentine,—unless otherwise indicated.

Origin.—The matrix or intertubular ground substance is formed by calcification proceeding from certain cells of the pulp; the walls and contents of the tubules are manufactured probably by the columnar cells on the surface of the pulp, these as well as the other cells being derived from the stomodæal mesoderm.¹

Distribution.—Hard unvascular dentine is found in the teeth of man, and most mammals; also in some reptiles and fishes. In the adult human dentition it measures about 2 mm. in the radicular, and 4 mm. to 5 mm. in the coronal regions, over the cornua of the pulp.

Macroscopical Appearances.—Yellowish-white in colour, dull, and slightly lustrous on cleavage.

HISTOLOGY

In considering the minute anatomy of dentine, it will be convenient to describe its (i) Matrix, (ii) tubes, (iii) sheaths of Neumann, (iv) interglobular spaces, (v) granular layer, (vi) lines of Schreger, (vii) contour lines of Owen, and (viii) lamellæ or laminae.

(i) *The Matrix*

The matrix, or inter-tubular substance, called also the basis-substance by some authors, appears to be perfectly homogeneous, translucent and hyaline. The researches of von Ebner² (who first successfully demonstrated the existence of a connective tissue stroma in bone) and Howard Mummery (*Philosoph. Trans. Roy. Soc.*, 1892), have, however, proved that a delicate network of fine connective tissue fibres pervades it. The latter says (p. 537) "We can no longer look upon the

¹ Throughout these pages the conventional use of the word "odontoblast" (meaning each of the large columnar cells on the surface of the pulp) will be retained. The author's view as to the term being a misnomer when applied to these cells is well-known; the reader is, however, referred to a Note in the Appendix for the arguments. It may be possible, a few years hence, to properly attach the name to the other round central pulp cells, and not to the constituents of the *membrana choris*, which may be designated "pulp corpuscles."

² "Histologie der Zähne mit Einschluss der Histogenese," in Scheff's "Handbuch der Zahnheilkunde," Vienna, 1891.

matrix of dentine as being a homogeneous substance, but must regard it as composed of a reticulum of fine fibres of connective tissue, modified by calcification, and when that process is complete, entirely hidden by the densely deposited lime salts.”

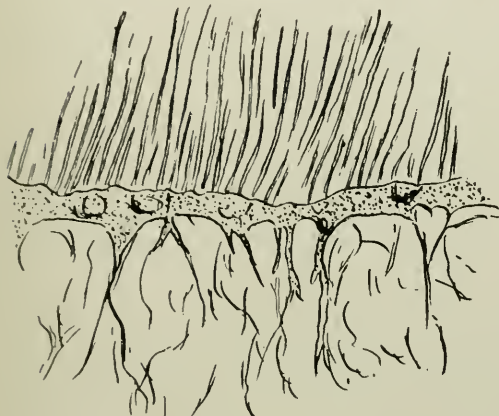


FIG. 36.



FIG. 37.

FIG. 36.—Longitudinal section at apex of radicular portion of pulp in Human premolar, shewing odontogenic fibres in continuity with the dentogenetic zone. Magnified 350 times. (After a drawing by Howard Mummery in the *Philosoph. Trans. Royal Society.*)

FIG. 37.—Transverse section of pulp of crown of a Human premolar, shewing fine fibres in connection with the dentine on one side, and the pulp on the other, crowded with cell nuclei. Magnified 230 times. (After a drawing by Howard Mummery from the same source.)

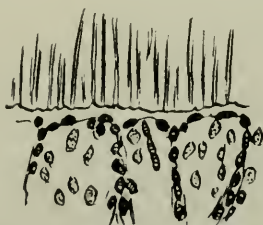


FIG. 38.—Same as preceding drawing, and from the same source. The larger nuclei belong apparently to odontoblasts. Magnified 230 times.

“These fibres decussate freely with one another, and I believe them to be analogous to the decussating fibres of bone. They are rendered visible, in some instances, by the slow decalcifying action of caries, as they appear to resist the

action of acids more than do the lime salts." He suggests for these the term "odontogenic fibres." They are, therefore,

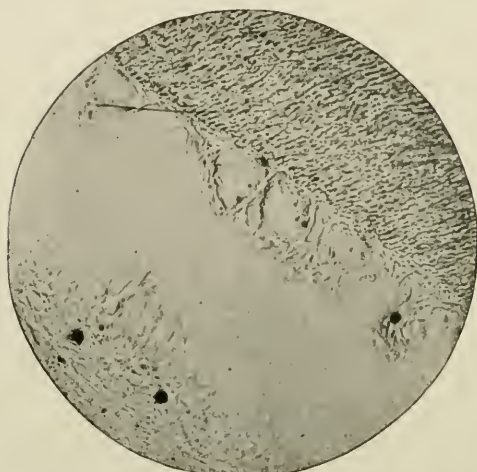

FIG. 39.—Odontogenic fibres. (*Photomicrograph by Howard Mummery.*)

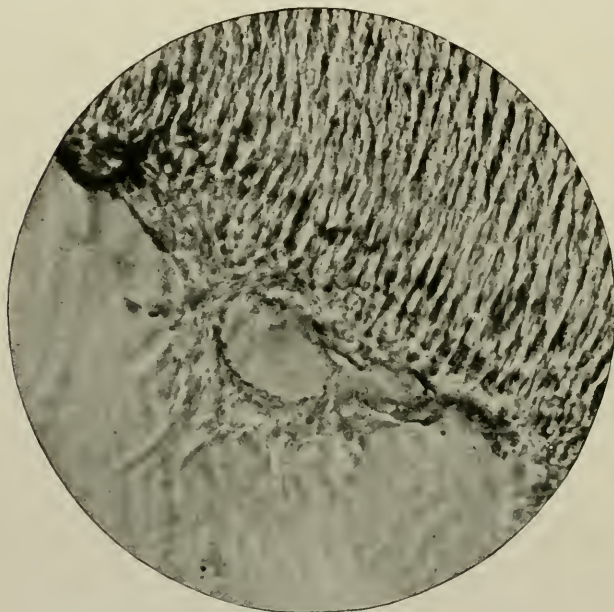

FIG. 40.—Same as preceding figure. (*Photomicrograph by Howard Mummery.*)

most likely, morphologically and chemically, identical with those found in the matrix of the bone, and have their origin in

connection with or are closely attached to certain connective tissue fibres of the pulp. They are uncalcified.

(ii) *The Tubes or Tubules*

The microscopical examination of a section of dentine, whether lengthwise, crosswise, or oblique, whether decalcified or not, discloses the fact that, interpenetrating it everywhere, are very numerous, fine, ramulous, fastigiated fibril-transmitting channels. Ground sections exhibit the tubes better than those

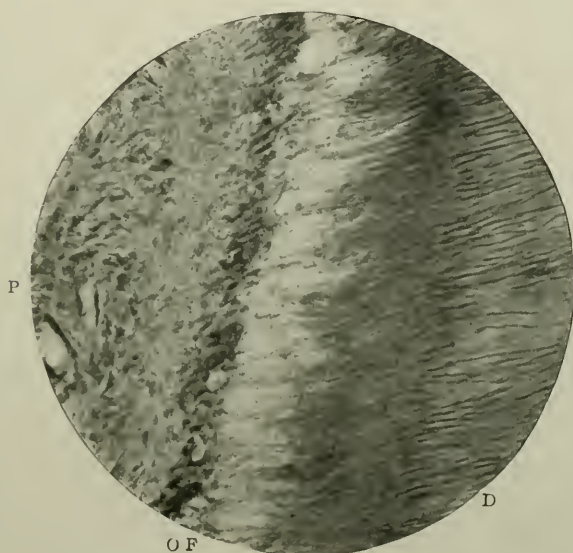


FIG. 41.—Odontogenic fibres in a vertical section of carious dentine, the decalcification of which has rendered them very apparent. The crown of a molar tooth of man. Decalcified by the author's process. Stained with Ehrlich's acid hæmatoxylene. Magnified 420 times. D. Dentine; P. Pulp; O.F. Odontogenic fibres.

chemically softened, because they retain *débris* and air, and are thus more strikingly differentiated from the matrix.

When viewed vertically, it is at once apparent that the tubes run centrifugally and radially from the pulp-cavity. They maintain a certain amount of coincidence with the direction of the peripheral cells of the pulp (the so-called odontoblasts)—that is, they leave the soft tissue in lines nearly always continuous with the long axes of the odontoblasts.



FIG. 42.—Vertical section of dentine, coronal portion, showing the arrangement of the primary curvatures of the tubules. Unstained. Magnified 40 times. E, Enamel; D, Dentine; F, Interglobular spaces.




FIG. 43.—Vertical section of dentine, radicular portion, showing the branching and terminations of the tubules. Prepared by grinding, after staining by impregnation with coloured collodion. Magnified 240 times. D. Dentine; C. Cementum.

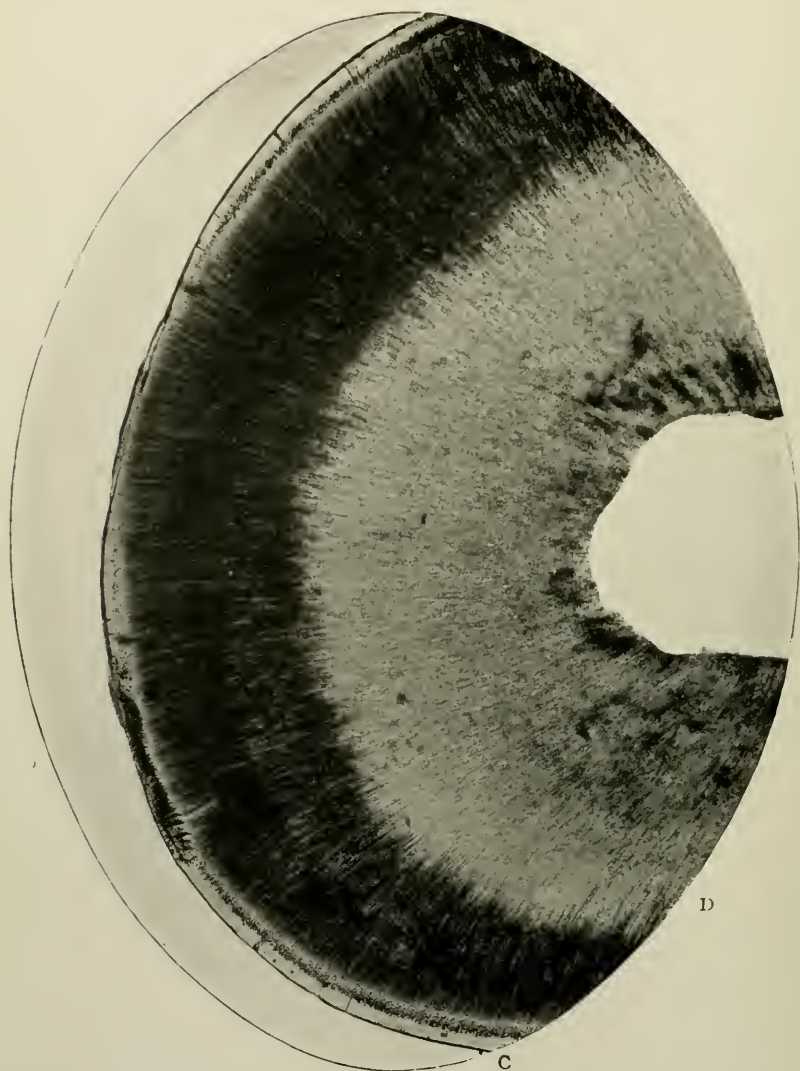


FIG 44.—Transverse section of dentine, radicular portion, showing the radiation of the tubes from the pulp cavity. Prepared by grinding. Unstained. Magnified 40 times. d. Dentine; c. Cementum.

They are arranged side by side in an approximately parallel manner to each other.

In width they vary from 1.7μ to 2.2μ , or 5μ (Kölliker); 2.5μ (Owen);¹ or 0.0055 mm.—an average measurement—at their pulpar or large extremity (Schäfer in "Quain's Anatomy," Vol. II., Part I., 1912). The distance between their mouths may be considered to be twice or thrice their diameter in the same situation, where, too, it—the distance—is fairly regularly

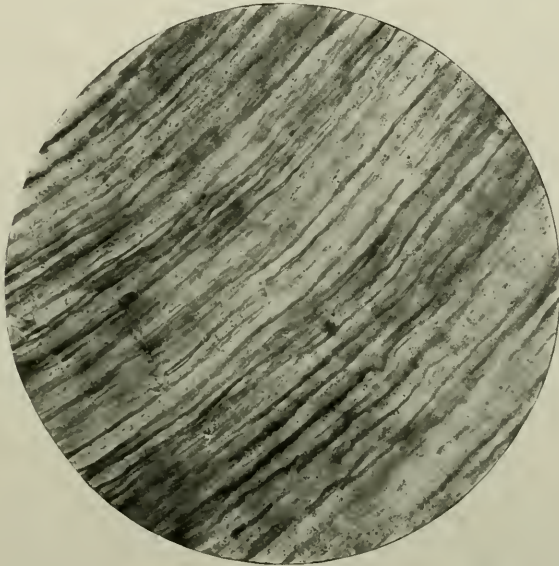


FIG. 45.—Longitudinal section of dentine. Prepared by grinding. Unstained. Magnified 420 times.

maintained. No hard-and-fast statement can, however, be made on this point, as the amount of intervening matrix is greater or less in different parts of the tooth and of the teeth in the same mouth. The diameter of the tubes diminishes as it proceeds outwards, till at the cervical region of the tooth it becomes immeasurable. Their greatest lengths may equal from 5 mm. to 6 mm.

The inner extremity of a canal is a wide open orifice looking on to the surface of the pulp; the other near the enamel or

¹ "Odontography," p. 459, 1840.

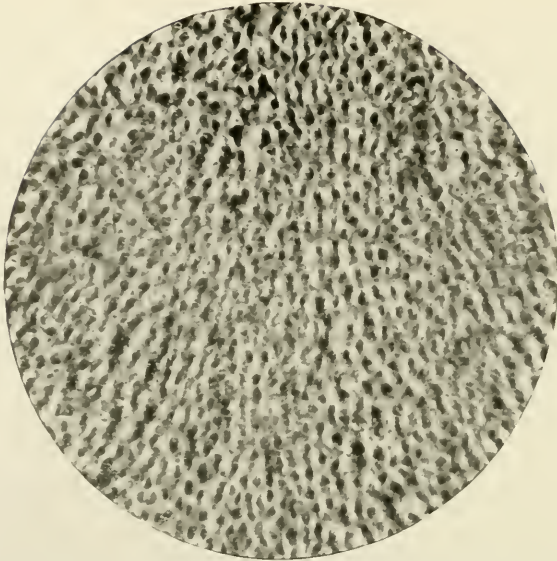


FIG. 46.—Dentine Nearly transverse section. Prepared by grinding. Stained by Weil's process. Magnified 160 times.




FIG. 47.—Dentine. Oblique section, showing the branches of the tubes. Prepared as in last figure. Magnified 420 times.

cementum is a cul-de-sac of large dimensions in the former locality, and generally one or more minute spherical knobs in the latter. Those in the coronal part of the tooth run vertically from the pulp cavity, at the cervical margin obliquely, and in the radicular region horizontally or with an inclination towards the apex. This difference in direction is gradually brought about, and varies considerably in different specimens (Fig. 42).

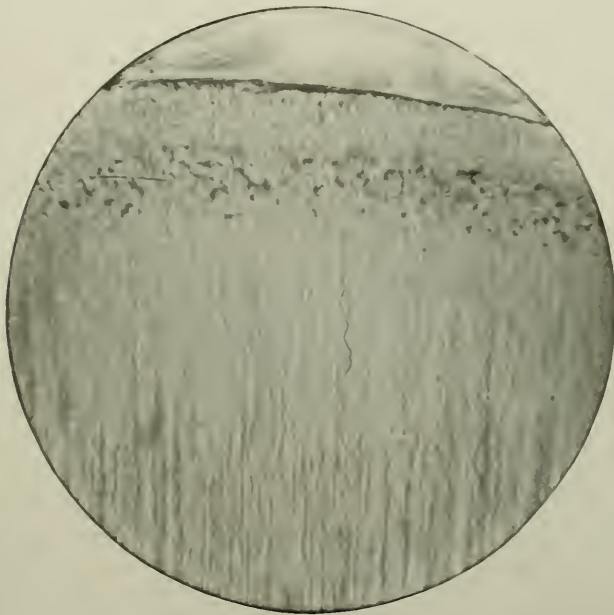


FIG. 48.—Dentine, radicular portion, showing secondary curvatures of the tubes. Magnified 160 times. (Photomicrograph by Douglas Gabbell.)

Each tube describes in its somewhat divergent course certain curves or flexures. These are called the “primary” and “secondary” curvatures of the dentinal tubules. The former are more marked in the crown than the root, the latter the root than the crown; the former are large, gentle undulations, the latter small spiral twists; the former are on the same plane or nearly so, the latter not on the same plane; the former two or three in number, the latter very numerous, as many as two hundred in a line— $\frac{1}{12}$ of an inch—according to Retzius.

Welcker has likened a tubule to "the thread of a corkscrew stretched so that the turns are drawn far apart," its breadth thereby being proportionately diminished. In thick longitudinal and transverse sections of the dentine of the root this corkscrew-like appearance is easily noted (Fig. 48).

The tubules of dentine in deciduous teeth are sometimes constricted at short intervals, and thus present a moniliform appearance.




FIG. 49.—Dentine. Coronal portion, showing tubes and spherical dilations of the termination of the branches. Prepared by grinding. Unstained. Magnified 160 times. D, Dentine; E, Enamel; A, Amelo-dentinal junction.

Further, at the cervical regions of the deciduous teeth the tubes make a conspicuous, sudden, extensive bend in their courses, in addition to the primary and secondary curvatures just noted. These curves are in a direction downwards and outwards toward the gingival edge. The result is the formation of that peculiar prominence or ridge of enamel, itself not increased in amount, at the cervical portions, which is so characteristically displayed in the teeth, (particularly the molars,) of the deciduous series, thus producing the appearance of great constriction at their necks. This does not occur in the permanent dentition.

Branches.—As they proceed outwards, the tubes give off exceedingly fine subsidiary tubes. These are branches which somewhat simulate those on a twig of a tree. They come off alternately and laterally from the stem or main trunk, sometimes at right, sometimes at acute angles to it; they are particularly abundant in the dentine of the roots, less frequent in or almost absent from that of the crowns, where they are chiefly found as the tube approaches its free termination. These



FIG. 50.—Dentine, radicular portion, showing branches of the tubes. D. Dentine; C. Cementum. Prepared and photographed by Dr. H. Box, Royal College of Dental Surgeons, Toronto.

channels may end, either in the form of branches or not, (i) in tiny spherical culs-de-sac near the margin of the enamel; (ii) by anastomoses with their neighbours—"the terminal loops" of Kölliker; (iii) in the interglobular spaces; (iv) in the granular layer of Tomes; (v) in the cementum; (vi) in the enamel-spindles beyond the amelodentinal junction or (vii) as straight cæcal terminations in the intercolumnar cement substance. In the crown they often divide dichotomously (*i.e.*, by pairs). These divisions, most commonly observed near the pulp cavity, are frequently bifurcations which Kölliker has described as being "repeated two to five times or more,

so that at length four, eight, sixteen or more canals may arise from a single one." He also mentions certain "ramifications" which would seem to him to be the sub-divisions of the main tubes. He says (*op. cit.* p. 291) "the canals, now narrower after their division, run close together and nearly parallel towards the surface of the dentine; and, except in the root, just begin to send out ramifications in the outer half or outer third of their course. These ramifications appear in the roots,

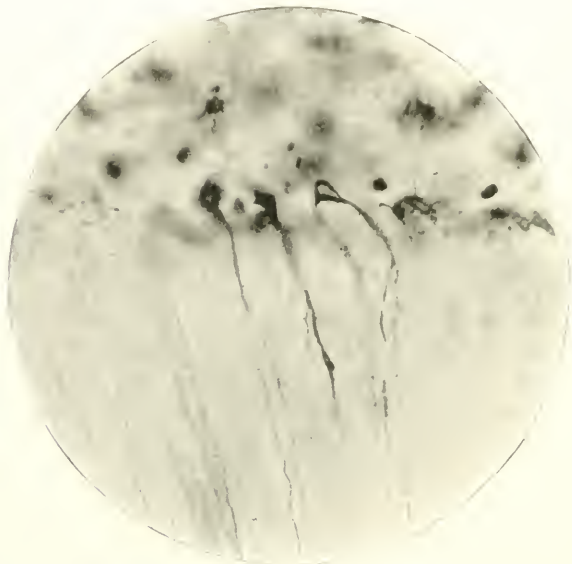


FIG. 51.—Terminations of the dental tubes in the spaces of the granular layer of Tomes. Prepared by grinding. Unstained. Magnified 420 times.

chiefly as fine branches issuing from the main tubes, but in the crown bifurcated terminations of them. In the latter case they are for the most part few in number: it is otherwise in the root, where the branches, being generally close to each other, and passing off from the canals at right or acute angles, give them sometimes the appearance of a feather, sometimes of a brush, the latter especially when the branches are large and ramify still more."

The off-shoots, like the main tubes, taper towards their terminations.

Transverse sections of dentine, in which the tubes are cut across, show abundant rounded piercings of the matrix, each having a slightly modified boundary or wall. The boundary is represented by a yellowish ring—black or grey if stained by Golgi's rapid process—which, when unstained, is often quite unrecognisable; but nevertheless exists as one of the sheaths of Neumann. The walls are very minute, and, in thickness less than the diameter of the aperture of the tubule.

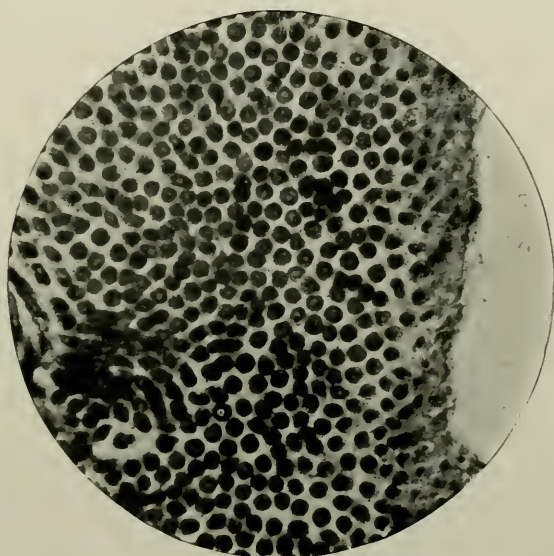


FIG. 52.—Dentinal tubes in transverse section. Prepared by Weil's process. Magnified 800 times.

Kölliker gives a description of and pictures (*op. cit.* p. 291), a transverse section through the dentine of the roots of teeth in which the tubes are intimately connected by extremely numerous anastomoses. Probably it was taken close to the pulp surface, as there are no indications in the drawing of any spherical or other termination of the branches.

The channel, in the fresh state, contains the dentinal fibril and lymph. The former in transverse sections appears like a

delicate roundish dot.¹ This does not necessarily occupy the centre of the canal, although it is most probable that during life it fills, or very nearly fills, its entire length. It is impossible to prepare, for histological purposes, sections of the hard and soft tissues of teeth in combination, without altering their normal characteristics. Hence it seems reasonable to believe that not only does the protoplasmic filament traverse the tube from pulp to extremity, but that also it rarely, if ever, completely occludes it.

It is evident that the contents of the tubules are protoplasmic processes or fibrils which emanate from the odontoblasts of the pulp. They represent their distal or dentinal

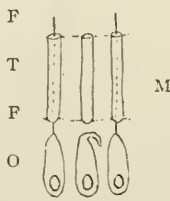


FIG. 53.

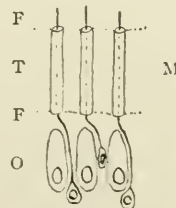


FIG. 54.

FIG. 53.—Diagram shewing Tomes' conception of relations of (o) Odontoblasts; (F) Dentinal fibril; (T) Dentinal tube, with its sheath; and (M) Matrix.

FIG. 54.—Klein's conception of the same.

processes. E. Klein, "Atlas of Histology," 1880, p. 185, considers that the odontoblasts do not furnish the dentinal fibrils. He says: "I cannot find convincing evidence of the odontoblasts doing more than producing the dentine matrix. The dentinal fibres appear to me to be derived solely from the deeper layer of cells which are wedged in between the former." The fibrils themselves are soft structureless threads, devoid of a covering of any kind, and continuous through all the length of the tubule and its branches. They are bathed during life with a serous exudation from the surface of the pulp. This

¹ Bödecker, "Dentin, Cement und Schmelz," in Heitzmann's "Mikroskopische Morphologie," Vienna, 1883, describes the fibrils as angular, not round—under enormous magnifications. He thinks they give off tiny off-shoots which run into the matrix of the dentine through the sheaths of Neumann. The action of reagents used for fixing and hardening the fibrils *in situ* produced this effect of angularity. The processes of cells in other parts of the body are never angular in cross-section.

exercises, no doubt, a trophic influence upon them, and prevents injury, which might occur if they were brought into immediate contact with the lining membrane of the tubule.

All authors are not agreed on this elementary question of their contents. Magitot ("Traité de Carie Dentaire," 1878), says that "during life the dentinal canaliculi contain a colourless transparent fluid;" and Morgenstern ("Ueber die Innervation des Zahnbeins" in "Archiv. für Anatomie und Physiologie," 1896), declares he has seen many *nerve filaments* in the tubes. "It is the dentinal canaliculi," he writes, "which for the most part contain the larger nerve filaments." His arguments are weak and valueless, depending as they do on the results obtained from the vagaries of so uncertain and unreliable a method of staining as that of Golgi, when applied to sections of dentine.

The matrix and tubes of dentine show marked translucency in places, especially the roots, in senile and functionless teeth.

(iii) *The Sheaths of Neumann*

After careful decalcification there remains a soft, mucoid, felt-like mass, the organic part of dentine—the walls of the tubes. Highly elastic and slightly cohesive to the intermediate matrix, when thus isolated the sheaths look like long yellow-elastic connective tissue-fibres: but they are, of course, quite hollow. They possess no histological significance. They were first accurately and most fully described by Neumann in 1863.¹ He demonstrated that all soft tissues of the tooth having first been removed, subsequent maceration in boiling acids, of various strengths for varying periods of time, led to dissolution of the whole of the inorganic elements, and left behind a tube-like formation, which was characterised by, and distinguished from, the dentine matrix by the peculiar property of resisting the action of chemical substances, and by great elasticity, and slight cohesion with the inter-tubular material. Some attention has lately been again given to the

¹ "Ein Beitrag zur Kenntniss des Normalen Zahnbein-und Knochen-gewebes." Leipzig.

question of the existence or non-existence of these sheaths; and interest revived in what seems a simple, but is, in reality, a complex study.¹ Optical effects are so easily produced when examining dentine: its collagenous substance is so hard: its association with the soft protoplasmic easily-destructible soft tissues so direct and complete, that it can be no small matter for wonder that investigators still hold opposite opinions which give rise to considerable confusion.

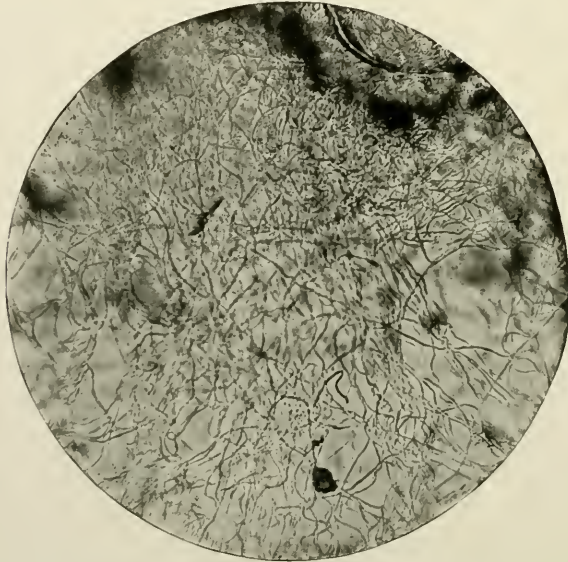


FIG. 55.—The sheaths of Neumann. Prepared by decalcification and teasing out. Stained with borax-carminé. Magnified 240 times.

Neumann affirmed that the tubules possess proper walls. He called them "Dental Sheaths" ("Zahnschieden") and he added that: "In the dental tubes are contained fibrous non-calcified processes of the peripheral pulp-cells ("Tooth-fibres"). In this way was corroborated the original statement of John Tomes in 1856, in his classical contribution to the *Philosophical Transactions of the Royal Society*, entitled "On the presence of fibrils of soft-tissue in the dentinal tubes."

¹"A Study of the Minute Structure of Dentine" by Dr. Kanæ Hanazawa, Tokyo. "The Dental Cosmos," 1917.

Kölliker, who actually first discovered them by acid maceration, points out that the apparent walls of the tubes in transverse sections are not the *real* walls, but a certain length of the canals themselves, which appear as dark rings. If, however, an edge, very narrow in width, and yellowish in colour, is seen, this he regards as the *true* wall ("Mikroskopische Anatomie," Leipzig, 1854).

Oscar Römer denies *in toto* the existence of these sheaths of Neumann. In his monograph already quoted, Part I. is devoted entirely to the consideration of their presence or non-presence in dentine. According to his measurements, they are 1μ to 2μ in width at their broadest part. He contends that the *contents* correspond to the *walls* of the tubes; in other words, "that the odontoblast *processes* (or dental fibrils),

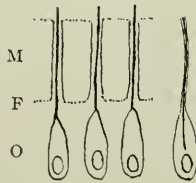


FIG. 56.—Diagram showing Römer's conception of relations of (o) Odontoblasts; (F) Dental fibril; and (M) Matrix.

really correspond to Kölliker's dental *tubules*," are therefore hollow, and continue as, and do not enter into Neumann's sheaths. He sums up his arguments with the following assertions:—

- (a) The fibrils described and depicted by Tomes in 1856 are no new formations, but completely identical with the dental fibrils described by Kölliker in 1834, while Tomes' membrane of the fibrils corresponds to the wall of the tubules, and to Neumann's sheath; and the contents of the fibrils, described by Tomes as semi-fluid, correspond to the contents of the tubules described as fluid by other writers.
- (b) The dental tubes assumed by Tomes do not correspond to the dental tubules of Kölliker, but are artificially produced, wall-less, tube-shaped hollow spaces produced

in the matrix of dentine by decalcification and dissolution, spaces from which Kölliker's tubules and Tomes' tubes can be easily isolated.

- (c) The odontoblast processes, designated "Tooth-fibres" or "Tomes's fibres," are not the contents of Kölliker's dentinal tubules, but represent both *the sheath* of Neumann and *the contents* together. Therefore, the conception of "Tooth fibres" or "Tomes's fibres," as the contents of Kölliker's tubules, must be dropped, and we must content ourselves for the present with the original assumption, that the contents of the dentinal tubules are a fluid or semi-fluid material, or one that has not yet been adequately investigated.

And he concludes: "According to my observations, there do not exist in the dentinal substance any tubules other than those of Kölliker. The dentinal tubes of Tomes are only tube-shaped holes produced in the dentinal substance by maceration; one cannot perceive, even under the strongest magnifying power, and even in stained section-preparations of *normal non-carious* dentine—whether in transverse, longitudinal, or diagonal section—any intervening space whatever, between odontoblast process (or the dentinal tubule) and the matrix of the dentine." Römer's observations are entirely faulty and untrustworthy; for the processes of cells in other parts of the body are never hollow—with the possible exception of the cilia of ciliated columnar epithelium, which are highly specialised processes of the cells endowed with movement.

The various contradictory theories concerning the existence and non-existence, the walling, and the contents of the dentinal tubules may be briefly mentioned as follow:

- (i) Their absence is affirmed by Magitot (1880).
- (ii) Their presence in mature dentine is denied by Xavier Sudduth (1887), who ("American System of Dentistry," p. 594), says: "The salts of calcium are deposited around the fibrils of the odontoblasts, and in a certain sense, dentinal tubuli may be said to exist at that time. We may say that this tissue is an aggregation of tubes containing fibrils, but in the process of aggregation they

lose their identity as such, becoming cemented together into a solid tissue." And further, "The fact that dentine is not capable of being broken up into tubes is, in my mind, conclusive evidence against the theory of the existence of a *dentinal sheath per se* as the wall of a dentinal tube."

- (iii) There are two kinds of tubules in dentine, one containing the processes of the odontoblasts, the other, finer, to receive *nerve fibres*. An unproved postulate of Franz Boll, 1868, "Untersuchungen über die Zahnpulpa" in "Archiv für Mikroskopische Anatomie." Bd. iv.
- (iv) The processes of the odontoblasts (dentinal fibrils) are Kölliker's dentinal tubes. Lent, 1885, "Ueber die Entwicklung des Zahnbeins und des Schmelzes," "Zeitschr. für wissenschaft. Zoologie," Leipzig.
- (v) The sheaths of Neumann are dependent on calcified dentine substance, because they are invisible (absent) in the dento-genetic zone. Erwin Höhl, 1896, "Beitrag zur Histologie der Pulpa und des Dentins" in "Archiv für Anatomie."
- (vi) The membrane of the processes of the odontoblasts form the sheaths which run in wall-less tubes. The sheaths *in situ* are wider than those artificially isolated by acids. Römer, 1899, *op. cit.*
- (vii) Their existence as separated structures is doubted by Underwood, "Aids to Dental Anatomy and Physiology," 1902.
- (viii) The tubules have definite walls (sheaths), and contain Tomes' dentinal fibrils,—processes from certain cells of the pulp. Tomes *op. cit.* 1914; as well as many other authors.

(iv) *The Interglobular Spaces of Czermak*

At varying distances below the amelo-dentinal junction are found in apparently sound as well as in imperfectly developed dentine numerous globular markings arranged in linear series, and running transversely to the dentinal tubes. Defective

dentine exhibits them remarkably well. They were first described by J. Czermak in 1850, and designated by him the "interglobular spaces." "Beitrag zur Mikro-Anatomie der Menschlicher Zähne."

As Tomes has pointed out, they are due to an arrested development of the tissue during certain early stages of its growth, when, for some cause or other, the calco-globular

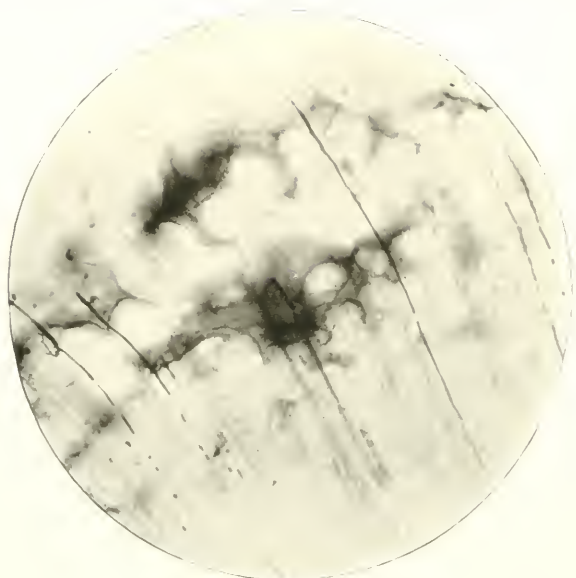


FIG. 57.—Interglobular spaces crossed by dentinal tubes. Prepared by Weil's process. Magnified 240 times.

masses have not fused, or have only partially melted together. The functions of the lime-bearing cells of the pulp have become temporarily modified, and instead of the dentinal basis-substance being deposited in proper amount and regularity—making a homogeneous whole—the calco-globular masses have remained unchanged or slightly changed, and the matrix has flowed around, and become, in time, fully calcified.

Seen under advantageous circumstances, *e.g.*, in sections which have been carefully ground thin, and stained by Golgi's silver chromate method, or impregnated with coloured colloid, the spaces vary greatly in shape and size. Their scalloped edges are made up of the rounded or oval margins of spheres

of calco-globulin mutually pressed together. If these bodies retain their rotundity, the spaces have here three, four, five, or more concavities forming their outline, the semi-lunes being often dissimilar in size and shape; there, they have a lobulated appearance; while elsewhere, by the process of union of two or three spaces, they become elongated and irregular. In diameter they vary from 2.5μ to 4.2μ , or less.

As to their contents they are generally believed to hold in their interiors, in the fresh state, soft protoplasm which fills them entirely. Dentinal tubules often traverse them. Tomes has proved this by noting in fragments of carious dentine, that the tubules which cross, not only contain micro-organisms, but have themselves become occasionally enlarged. The protoplasm, under favourable conditions, undergoes calcification, and the dentine is said to be areolated.¹

Dentinal tubules may terminate in the interglobular spaces.

In dried sections, they contain air, a fact which is easily demonstrated by soaking thin slices of dentine in coloured collodion, which runs into and fills every part. They are therefore in dried specimens veritably "spaces."

(v) *The Granular Layer of Tomes*

In the radicular portions of teeth, and beginning at the cervical margin, is the granular layer. It stretches as a fairly thick black or grey band, round the roots, at the periphery of the dentine immediately internal to the cementum. It presents the appearance, under low powers, of a line of black grains of sand. Near the neck of the tooth the layer is narrow, but as it reaches the apical foramen, it broadens out considerably, and soon is more pronounced. This is not, however, constant. The author possesses a section in which the rows of interglobular spaces and the granular layer are coalescent at a spot immediately subjacent to the ending of the enamel

¹ These areolations of dentine are most likely perfectly analogous with those irregularly shaped layers made up of solid rounded calcified bodies seen occasionally near the surface of the shafts of long bones, lying in their osseous laminae. They differ, however, in the fact that, whereas the former betray certain developmental defects, the latter mark various sites of absorption and re-deposition of bone.

at the cervical region; and here the latter is very broad and marked. In some sections it is hardly at all visible.

On closer examination, these multitudinous dots assume various irregular shapes. Some are more or less circular, others oval; some triangular, others quadrate; some clavi-form, others stellate; a granule—in a word—represents a compromise between an interglobular space and a lacuna in hyperplastic cementum.

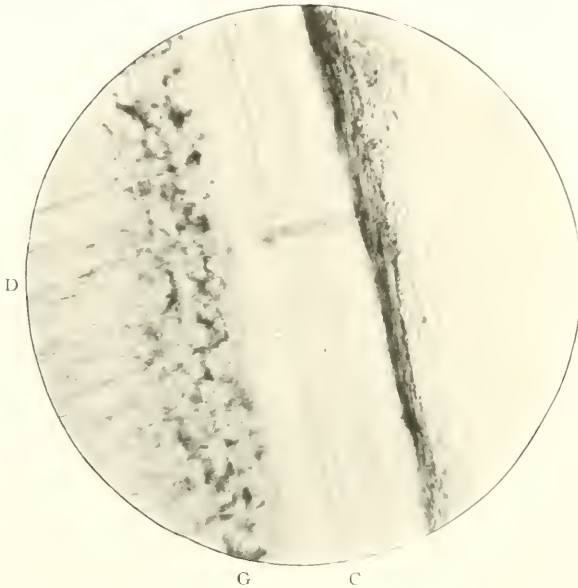


FIG. 58.—The granular layer of Tomes. Prepared by grinding and staining with coloured collodion. Magnified 240 times. D. Dentine; c. Cementum; G. Granular layer.

Many instances are noted where the terminations of the dentinal tubules end in these tiny spaces; and when canaliculi seem to lead from them, they can be traced to one of the endings of a tubule.

Approaching the apex of the root, the spaces increase greatly in numbers, and are much larger and more irregular. Occasionally, a large spindle-shaped lacuna may be found. The layer is situated in a matrix of dentine which is distinctly granular; though the term “granular layer” refers obviously to the spaces.

Their contents, according to Bödecker, are soft protoplasm which is in connection with the contents of the tubules on one side, and the canaliculi of the cemental lacunæ (when they exist) on the other. It would seem, however, that it is by no means easy to prove this assertion. The granular layer is stained with the utmost difficulty by the action of carmine or any of the other basic, acid, or aniline dyes. It is more likely to be beyond the pale of nutrition.

Bounding the granular layer externally is a very narrow strip of homogeneous dentine: then comes a dark line—it is nothing more than that—which forms the point of demarcation between dentine and cementum. The homogeneous zone and this line are devoid of any structure whatever.




FIG. 59.—Schreger's lines in dentine. From the ivory of the tusk of a walrus. Prepared by grinding. Unstained. Magnified 45 times. Cf. Fig. 26.

(vi) *Schreger's Lines*

These, sometimes seen in horizontal sections of dentine, must not be confounded with Schreger's lines in enamel. Many of the dentinal tubes as they course outwards form the artificial appearance of bands, through the primary curvatures passing in the same direction. Thus, Schreger's lines are

merely markings which, running parallel to the external edge of dentine, are produced by the coincidence of the primary curvatures of the tubules (see Fig. 60).

They are well perhaps best exhibited in sections of the ivory of the tusk of the walrus, where they appear to be due to sudden short bends or twists of the primary curvatures, occurring at identical places in their lengths. The effect under low powers is a much striated character of the tissue.

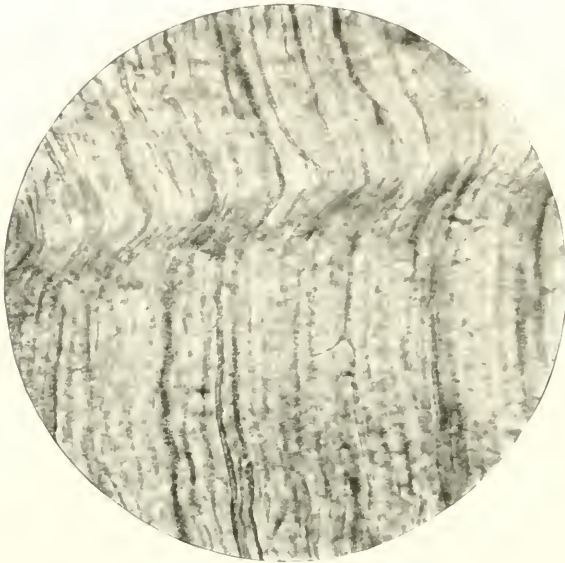


FIG. 60.—Same as the preceding. Magnified 420 times. Cf. Fig. 27.

(vii) *The Contour Lines of Owen*¹

comprise (i) Schreger's lines in dentine, and also (ii) rows of so-called "dentinal cells." Under low powers these rows resemble lines, particularly in human molars and in the teeth of *Cetacea*, and it is to them that he refers when he describes them as "contour lines." On page 460, he says, "Both the primary and secondary curves of adjacent tubes are parallel; and occasionally the tubes make a short bend along a line parallel with the outer contour of the crown, giving rise to the appearance which may be called "contour lines," the par-

¹ Owen: "Odontography," 1840.

allelism of the entire tubes being affected only by the amount of divergence in radiating from the pulp cavity." Again (p. 464), "These lines are not equally conspicuous in every tooth; I have usually found them most so in the molars of the human subject, where without being regularly equidistant, they have presented intervals of about one hundredth of

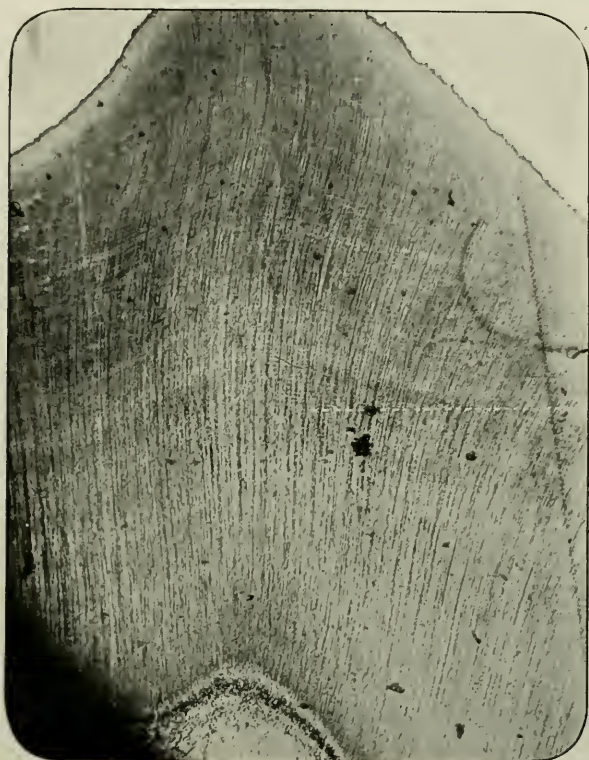

FIG. 61.—Contour lines of Owen in dentine. Vertical section of Human molar. Decalcified. Stained with Ehrlich's acid hæmatoxylene. Magnified 40 times. L. Owen's lines, running in a transverse direction.

an inch, commencing at thrice that distance from the periphery of the dentine."

With regard to the last-named histological formation, *i.e.*, the "dentinal cells," Owen remarks, "In many teeth, moreover, and especially in the tusks of the elephant, the secondary branches of the dentinal tubes dilate into intertubular cells along lines, which in like manner are parallel to the coronal

contour of the tooth; hence another cause of the appearance of concentric lamellæ, and of the actual decomposition of such teeth into super-imposed lamelliform cones." These dentinal or "calcigerous cells," as this distinguished author also designates them, form many layers having a certain amount of parallelism with the contour of the pulp cavity. He described them first in a Report to the British Association in 1838 (vol. vii., p. 144). They are not animal cells in the modern acceptance of the term, but in the interspaces of the tubes they include a "tubular structure." "The intertubular space is not cellular, but clear and structureless." To-day, histologists would prefer to think of them as representing merely the calcified outlines of what might have been interglobular spaces. Owen's contour lines were seen by Salter,¹ who, however, prefers to call them "incremental lines," as indicating more accurately the manner in which the tooth substance is built up.

(viii) *Lamellæ or Laminæ*

Occasionally, though seldom, vertical sections of roots or human molars, when ground, reveal very clearly certain markings in the periphery of the dentine. Ranged at right angles to the tubules, and running concentrically with the pulp chamber, these short straight strips are very numerous in some sections, sharply defined and bright when unstained, of variable length, and cross the tubes near their extremities. They are non-pathological in origin, and are not artificially made by the action of reagents. Most probably they represent marks of stratification during the development of the tissue.

A second class of laminæ is often seen in the matrix of mature dentine when decalcified in hydrochloric acid, and stained with hæmatoxyline. Vertical-transverse (labio-lingual) sections of molars, show over the cornua of the pulp, regularly arranged faint shadings, separated by brighter less-coloured lines; and in the cervical and radicular regions, rounded dots (which are probably the same as Owen's dentinal

¹ "Dental Pathology and Surgery," page 10, 1874.

cells¹) of darker colour near the pulp, and near the cementum long looped lines running in the direction of the tubes. These long lines or laminae are joined at their distal ends by delicate arcuate markings, the concavities of which always look towards the pulp.

Thus, lamellæ in dentine include two groups: the former, short, tube-like, straight; the latter, long wavy bands and spherical shadows, and lines joined by an arch.

These laminae are not due to staining, nor are they optical illusions. The first group obtains in natural conditions; while the others are evidently rendered more apparent by decalcification, and more striking by staining. They both certainly indicate the manner in which calcific deposition has taken place.

F. J. Bennett,² in a paper on "Certain points connected with the Structure of Dentine;" has described laminae in dentine which has been acted upon, for some length of time, by glycerine. In certain longitudinal sections the dentine bordering the margin of the pulp cavity "presented a ringed appearance, and was slightly laminated." This was due to "the dentinal tubes, in this situation, having lost their surrounding inter-tubular tissue, which left them clearly defined; but this removal of the matrix had not completely freed them. Their course appeared to be interrupted, at regular intervals, by layers of membrane having a general direction parallel to the surface of the pulp. The layers of membrane (laminae) bore a general resemblance to that seen in interglobular dentine; in this case, however, circular apertures and not solid globules occupied the surface of the membrane. Oval spaces were also found between the layers of membrane." Bennett put forward the following hypotheses, as being the explanation of such phenomena:

(a) The laminae might represent a part of the matrix of dentine, which, possessing a greater power of resisting the solvent action of glycerine than the rest, represents a new transitional stage or phase in its calcification; or

¹ Owen's "Odontography." Pl. xcv. fig. 2, also cxiii., fig. 2, and cxix., fig. 1.

² *Trans. Odonto. Soc. of Gl. Britain, Vol. xxi., p. 6, 1889.*

- (b) Unequal expansion or contraction of certain parts of the matrix, producing separation of the layers; or
- (c) Evidences of cell structure in the matrix.

SECONDARY DENTINE

Secondary dentine is a physiological product. In the strictest sense of the term, it should be used to designate every form of new tissue deposited in the substance or on the surface of the pulp, which occurs after full development of that organ and of the dentine. It has been hitherto used, however, for describing both physiological and pathological conditions. Salter's¹ patient and remarkable investigations in that particular portion of dental pathology which deals with degenerative changes in the dental pulp, led him to classify all forms of dentinal deposition as secondary dentine, and in a sense this was perfectly correct. But the term seems to require a more definite meaning; for he describes under this one heading three kinds:—"Dentine of repair," "dentine excrescence," and "osteo-dentine" or "intrinsic calcification."

It would be more correct in modern days, since so many varieties of pathological dentine have become known, to restrict the expression entirely to physiologically constructed dentine found, *e.g.* (i) in the incisive margins of the persistently growing teeth of *Rodentia*, etc., in Man (ii) in the accompaniments of old age, or (iii) the deposits sometimes found in long-retained deciduous teeth. Senile teeth constantly possess a complete mass of secondary dentine occluding the pulp cavity, the occurrence of this having been brought about in a physiological manner. As a non-pathological result of an active state of the pulp, secondary dentine may lastly be associated with (iv) attrition, abrasion or fracture of the teeth, when not complicated by caries of enamel or dentine.

¹ "Dental Pathology and Surgery," chaps. xi. and xii., 1874.

CHAPTER V

THE CEMENTUM

MICROSCOPICAL ELEMENTS: (i) Matrix; (ii) Incremental lines; (iii) Perforating fibres.

GENERAL CHARACTERISTICS

Definition.—The thin hard substance¹ situated immediately external to the dentine of the roots of teeth of Man and many animals.

Origin.—It is a product of the osteoblasts of the periodontal (alveolo-dental) membrane, *i.e.*, the thin inner layer of the dental capsule.

Distribution.—In the great class *Mammalia* cementum or *crusta petrosa*—a former appellation—forms the cortex of the radicular dentine: but also in the ox, horse, elephant, capybara, and other animals, it not only unites the roots of teeth, but before attrition has taken place, exists as the coronal integument.

In Man, it normally measures, in width, from 175μ to 250μ .

It is rarely found in the teeth of *Pisces* and *Reptilia*; and is normally absent from the roots of ankylosed teeth. Ovarian teeth also do not always possess it.

Macroscopical Appearances.—Whitish-yellow in colour, smooth, dull, line of junction with enamel pronounced and darker than rest of cementum.

HISTOLOGY

The structures calling for special microscopical attention in this the least important of all the hard dental tissues of man, are, (i) Matrix, or basis-substances; (ii) Incremental lines; and (iii) Perforating canals and fibres.

¹ The chemical composition of human cementum is unknown.

(i) *The Matrix*

The matrix or basis-substance makes up the greater part of the tissue. It extends as a narrow non-vascular lamina round the roots of teeth external to the homogeneous layer of dentine, beginning at the cervical region and covering over the apices of the roots, though like the dentine it is discontinuous at the apical foramina. Its relationship to enamel has already been alluded to; its relationship to dentine is such as

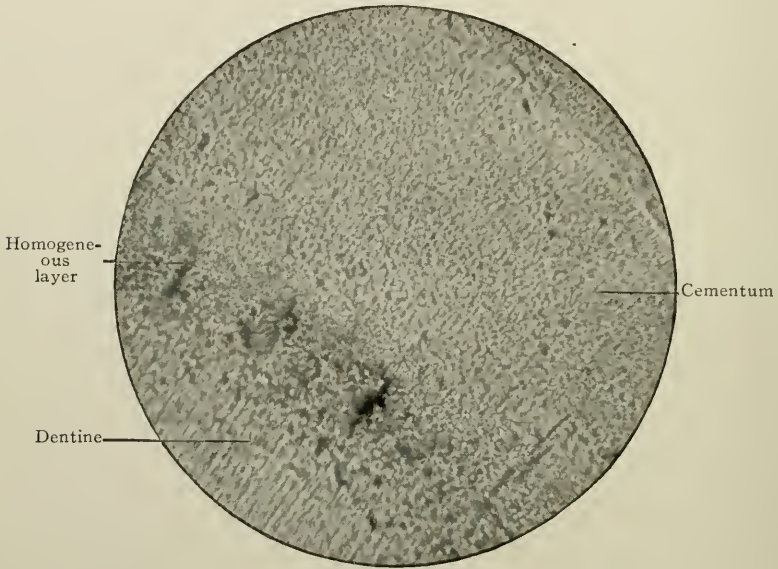


FIG. 62.—Granular appearance of cemental matrix. Magnified 1,000 times. (Photomicrograph by Norman Broomell.)

to make it difficult, if not at times impossible, to determine where the one begins and the other ends. Often no sharp line of demarcation—as in the case of enamel and dentine—exists.

The general appearance of this tissue varies very much—thus it may be hyaline, finely granular, or even made up of bodies of an amorphous type.

It is capable at times of being stained, especially at its outermost part. Normal cemental matrix in young and old subjects is therefore nearly structureless. Roots of simple teeth

unaffected by morbid processes show this thin layer, which maintains the same degree of thinness throughout its whole extent. In the case of bi-rooted premolars or molars, however, there is a tendency for it to become slightly thicker on their alveolar or inner aspects. In old age it is somewhat thicker (see Chapter III, Vol. II).

But in every section of cementum, faint shadings of a slightly different refractive index to other parts of the tissue can, on

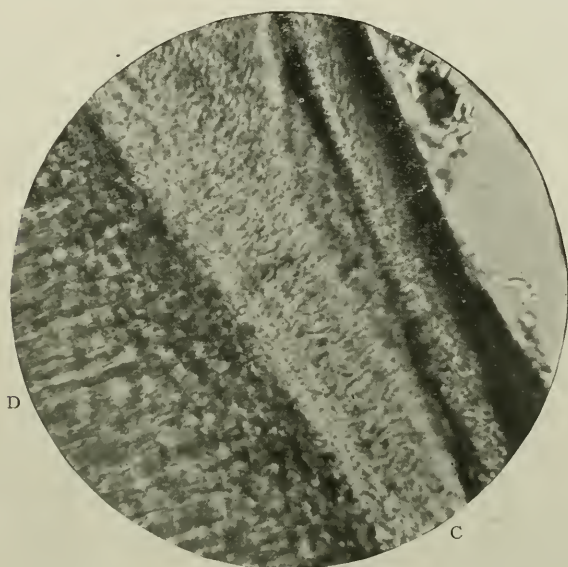


FIG. 63.—Same as preceding. Magnified 420 times. D. Dentine; C. Cementum.

careful examination, be clearly differentiated. Normally they are but feebly revealed. These shadings are arranged in two ways: The more pronounced run parallel to the periphery, and without doubt represent immature incremental lines: the others, which are very numerous, cross the first-named at right angles. Both classes can be observed in vertical as well as horizontal preparations (Fig. 66).

In thus describing the minute organisation of this tissue, the author would like to emphasize the fact, that in his opinion, formed as the result of the examination of many sections, the cementum of the teeth of man is usually free from lacunæ

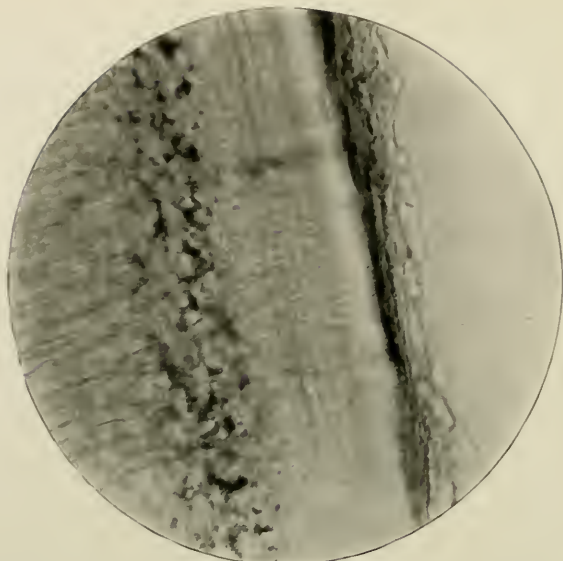


FIG. 64.—Incremental lines. Prepared by grinding. Unstained. Magnified 400 times.

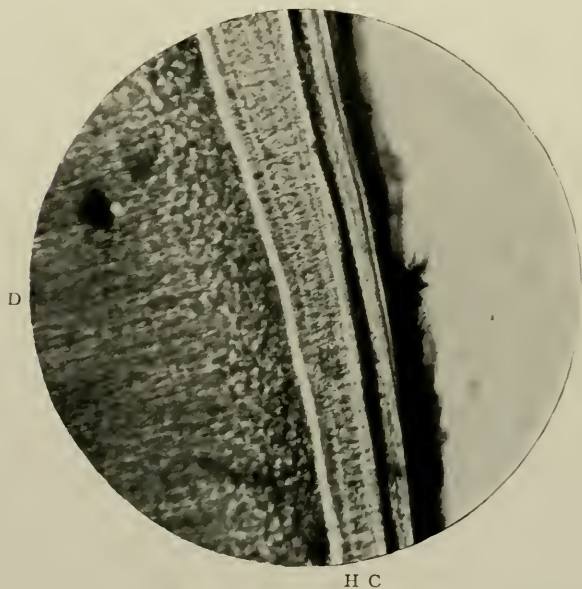


FIG. 65.—Perforating canals and fibres in cementum. Prepared by grinding. Stained with chloride of gold. Magnified 40 times. c. Cementum; h. The homogeneous layer of dentine; d. Dentine.

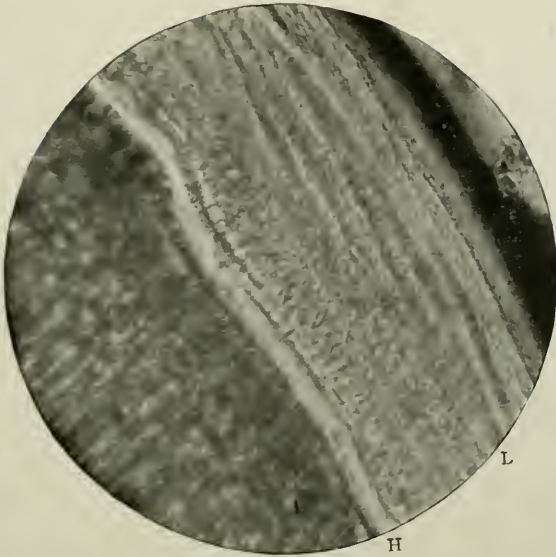


FIG. 66.—Cementum. Prepared as in last figure. Incremental lines and homogeneous layer well defined. Magnified 400 times. L. Incremental lines; H. Homogeneous layer.




FIG. 67.—Longitudinal lamellæ of cementum, showing numerous varicosities. Magnified 1,000 times. (Photomicrograph by Norman Broomell)

and canaliculi, being nothing more nor less than a dense, solid, nearly homogeneous band of calcified basis-substance, extending round the roots. The teeth of monkeys and sheep (root portions) have been inspected microscopically; and here, as in man, it exists as a thin strip almost devoid of histological elements, such as those characteristic of bone. In the opossum and certain other marsupials, however, a thick layer of cementum is found sufficiently often to be practically a

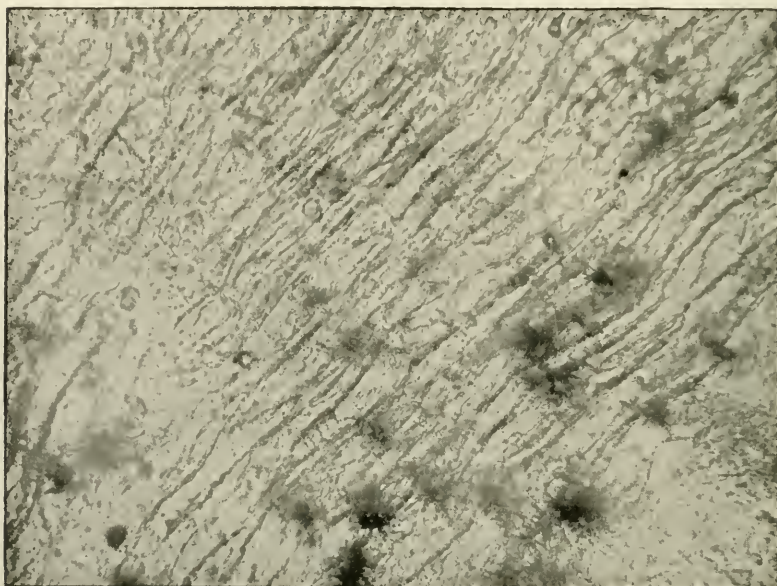


FIG. 68.—Striated cementum from radicular region of tooth, near apex, to show the complex character of the thicker tissue, viz.: "The longitudinal striae, transverse fibres, cement-corpuscles and zones of apparently unbroken granular matrix." Magnified 100 times. (Photomicrograph by Norman Broomell.)

characteristic of this class. The reader is referred to page 110 in this connection. This lack of lacunæ in normal cementum has also been observed by Otto Walkhoff (*op. cit.* pp. 142, 143) and figured by him in Plates v. and ix.: both statement and photographs having been brought to the notice of the writer since the preceding lines were penned.

But one of the after-effects of a morbid change or a series of morbid changes in the alveolo-dental periosteum—however

slight, is the stimulation of the otherwise quiescent osteoblasts, to deposit osseous material on the periphery of the tissue; and lacunæ are then formed, imprisoning the osteogenetic cells. A single lacuna may not infrequently be observed situated near the granular layer of Tomes; and this would



FIG. 69.—To show partial calcification of the incremental lines. Magnified 1,000 times. (Photomicrograph by Norman Broomell.)

indicate abnormal processes going on about the time the earliest deposited cementum is completed. There is, therefore, under healthy conditions, no chain of living matter joining the pulp to the periodontal membrane.

(ii) *Incremental Lines*

represent the marks of stratification during development. They look like sinuous unbroken lines placed in a fairly regular

and uniform manner one over the other. Sharply marked off from the rest of the matrix, at times, and running in a parallel direction to the long axis of the root, they give rise to a lamellated structure (Fig. 67).

In young cementum the lamellæ correspond in number over all portions of the root, the only difference being that they are

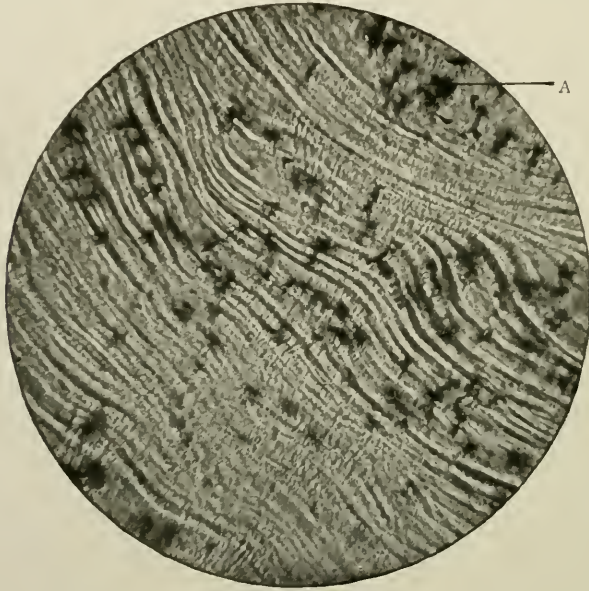


FIG. 70.—Transverse section of an adult premolar near apex, to show the varying disposition of the lamellæ. The incremental lines follow the surface of the dentine. "As the centre of the area is approached, this regularity is much interfered with, some of the lamellæ being discontinued, others greatly thickened, while the field, taken in its entirety, suggests anything but regularity in the laying down of the different strata. Magnified 60 times. A. Granular layer of Tomes. (Photomicrograph by Norman Broomell.)

much thinner at the cervical than at the apical region: in adult cementum their width is greater, and they are usually more numerous in the latter than the former situation¹ (Norman Broomell).

The term "Incremental lines" was introduced by Salter, ("Dental Pathology and Surgery," 1874), and includes the

¹ "The Histology of Cementum." *The Dental Cosmos*, Vol. xl., p. 706, 1898: also Broomell and Fischelis' "Anatomy and Histology of the Mouth and Teeth," p. 351, 1917.

laminations sometimes found in enamel (but not the brown striae of Retzius, or Schreger's lines), the contour lines of Owen in dentine, and the layers of stratification in cementum.

Stöhr ("Text-book of Histology," Würzburg, 1914) says that "Cementum contains typical bone cells enclosed in large lacunæ which connect with one another through canaliculi. In young teeth Haversian canals are absent, but in old teeth they occur in the outer layers near the apex of the root." These are altogether erroneous statements. And Sir Ernest Schäfer ("The Essentials of Histology," 1916) figures on page 303 a drawing after Sobotta, which gives an entirely false impression of the structure of normal cementum. There are no lacunæ in the normal tissue: the illustration is that of hyperplastic cementum.

(iii) *Perforating Canals and Fibres*

In close juxtaposition to the band of homogeneous tissue which borders the dentine, and running at right or acute angles to it, in adult normal cementum, there can be commonly seen thick bundles of connective tissue fibres and broad irregular canals. In this way the homogeneous layer is bounded internally by the granular layer, externally by groups of perforating canals and fibres. The former are few and irregularly curved in an outward direction, and may occasionally extend half-way through the thickness of the cementum. The author has found some of them supplied with tiny filamentous branches. The latter on high magnification are seen, in sections prepared by Weil's process, to consist of myriads of bundles of blackish strands. They are short and thick, and remind the observer of the odontogenetic fibres of dentine matrix. Their outer extremities may enter the canaliculi (Fig. 71).

Black considered them, and seemingly with sound scientific reasonableness, to be the calcified or semi-calcified remains of the "principal fibres," of the periodontal membrane.

Sharpey's fibres, penetrating from without, may be noted in some sections of cementum where the hard and soft parts have been prepared and preserved *in situ*. They are very short straight or slightly curved bundles of fibrils, the main

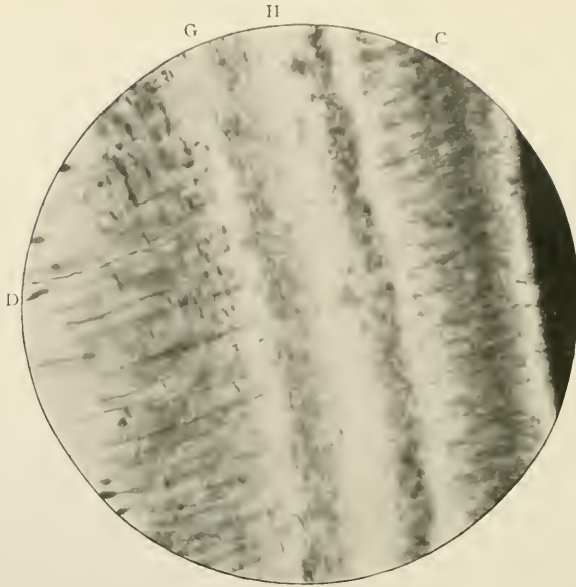


FIG. 71.—Longitudinal section of cementum. Prepared by Weil's process. Shows the perforating canals and fibres. Magnified 420 times. c. Cementum; g. Granular layer; h. Homogeneous layer; d. Dentine.

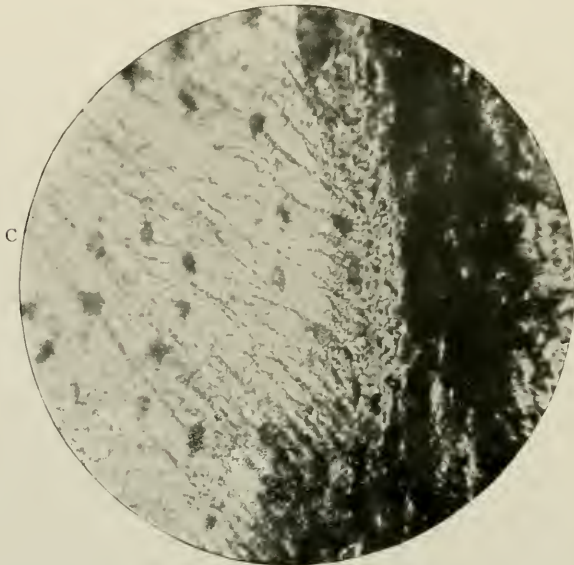


FIG. 72.—Sharpey's fibres of cementum. Magnified 800 times. Unstained. c. Cementum slightly hyperplastic.

characters of which agree with white fibrous tissue, while some may be of the nature of elastic tissue. They are identical with the perforating fibres in the lamellæ of bone. In cementum they occupy the interiors of slightly truncated canals.




FIG. 73.—Perforating fibres passing from the outer margin of the first-deposited cementum outwards "until the next incremental line is reached, at which point they gradually disappear, but recur in the succeeding lamellæ." Magnified 1,000 times. A. Primary or oldest layer of cementum. (Photomicrograph by Norman Broomell.)

As will be seen, Sharpey's fibres are entirely distinct structures compared to the perforating fibres described above.

Normal cementum is non-vascular; but there would seem to be, in the majority of cases, fine protoplasmic fibrils which traverse the boundary line between dentine and cementum.

Norman Broomell, in the excellent study already mentioned, would recognise in the tissue under consideration

three zones or layers, not always discernible but fairly constant. The inner, first-formed, is granular, unbroken, and continuous with the granular layer; the intermediate contains many lacunæ; and the outer or youngest exhibits many sinuous incremental lines. As the tissue becomes more fully calcified the lacunæ disappear, and the zone possesses many




FIG. 74.—Fibres passing in a direction almost parallel to the surface, and towards the apex of the root. Magnified 300 times. (*Photomicrograph by Norman Broomell.*)

of the histological characters of the oldest layer. Tomes describes this last layer in thick cementum as a “glassy film, denser than the subjacent portions,” and considers it closely similar to the globular formations characteristic of dentine in an early stage of development.

Underwood, in “Aids to Dental Anatomy and Physiology,” p. 49, 1902, said: “The outermost layer of cementum is structureless: . . . when young, globular forms may be traced in its substance.”




FIG. 75.—Fibres springing from the granular layer of Tomes, at regular intervals, and penetrating the cementum at right angles to the incremental lines. Magnified 500 times. A. The circumferential fibres of Broomell. (*Photomicrograph by Norman Broomell.*)

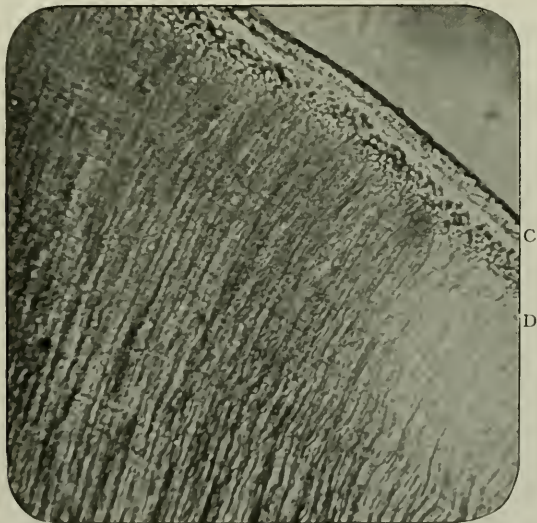


FIG. 76.—Structureless cementum of a deciduous tooth. Prepared by grinding. Unstained. Magnified 200 times. D. Dentine; c. Cementum.

It is, however, perfectly obvious that he still inclined to the belief that normally this tissue contains lacunæ and canaliculi.

Cementum in deciduous and supernumerary teeth is relatively thinner than that of the permanent series. It is nothing more than a very narrow, structureless band (Fig. 76).

CHAPTER VI

STRUCTURAL MODIFICATIONS OF THE ENAMEL, DENTINE AND CEMENTUM

MICROSCOPICAL ELEMENTS IN THE ENAMEL OF: (i) *Rodentia*; (ii) *Sirenia*. (iii) TUBULAR ENAMEL. (iv) PLICI-DENTINE; (v) VASO-DENTINE; and (vi) OSTEO-DENTINE. CEMENTUM.

Students of comparative anatomy need not be reminded that the subject is full of interest with regard to the modified forms of teeth, not only in number and shape but also in size and function. It is not surprising, then, that the minute structure of the masticatory organs of the lower vertebrates not infrequently differs very remarkably from that of man. As was hinted in Chapter III., enamel may be found, in some instances, clear and structureless, in others, presenting a most complicated pattern. Here will be briefly considered the chief variations in the histology of the enamel, dentine and cementum met with in the vertebrates. Tomes' "Manual of Dental Anatomy" will ever remain the standard work on the subject, and to this and to Sir Richard Owen's "Odontography" readers are referred for elaborated details.

ATYPAL VARIATIONS OF ENAMEL

Among *Mammalia*, the Order *Rodentia* supplies many instances of modification in structure of this tissue. These variations may be a provision on the part of nature to render the free surface and incisive margin of the teeth particularly strong. Taking the Families in their proper anatomical order, brief reference can only be given to the histology of the enamel of (i) the *Muridæ*, mice, rats, &c.; (ii) *Castoridæ*, beavers;

(iii) *Soricidae*, squirrels; (iv) *Hystriidae*, porcupines; and (v) *Leporidae*, rabbits and hares. In *Rodentia*, generally speaking, the large incisors are frequently pigmented a deep orange colour. According to Tomes, the colour is situated in the substance of the enamel itself.

Enamel invests the anterior and lateral aspects of the teeth and is thicker in the former than in the latter situation.

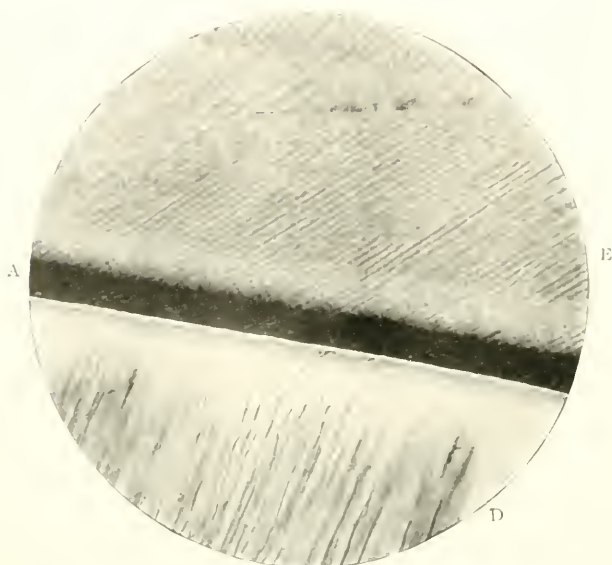


FIG. 77.—Vertical section of a persistently growing scalpriform tooth of a rodent. Prepared by grinding. Stained with borax-carminc. Magnified 240 times. Shows striation of enamel rods. E, Enamel; D, Dentine; A, Amelo-dentinal junction.

(i) In the *rat* the straight columns are arranged in a parallel direction, and are placed at an acute angle with the surface of the dentine. This is seen in the accompanying photograph (Fig. 77). Each rod is not only very striated but is also deeply indented, and by making serrations with its neighbours renders the tissue remarkably dense and difficult to fracture.

(ii) The enamel of the *beaver* exhibits a lattice-like arrangement of the rods. *Longitudinally* cut, the enamel rods are “inclined upward towards the apex of the tooth, at an angle of 60 deg., then, after passing through about half the thickness

of the enamel, they turn up abruptly again, so that they are approaching parallelism with the dentine, here making an angle little less than 30 deg. with it. It follows from this that no *transverse* section can show very plainly the direction of the rods in both parts of their course. The most instructive transverse section is one cut parallel with the layers near to the dentine; this will plainly show the successive layers passing to the right and to the left just as in the squirrel; but the yet-more-inclined fibres of the outer half of the enamel will then be cut across obliquely. . . . As regards the decussation of the rods of ultimate layers, it is similar to that of the *Soricidæ*, but it differs in the laminae being slightly flexuous instead of pursuing perfectly straight lines" (Tomes).

(iii) An apparent division into inner and outer portions is exhibited in the enamel of the *squirrel*. Here, the rods are continuous through all the thickness of the tissue, but, running in different directions when viewed either vertically or horizontally, produce a complex pattern.

"In the former they leave the dentine at right angles to its surface, and after traversing two-thirds of the enamel, suddenly bend, and form an angle of 45 deg. with their original course: in the latter, they are arranged in horizontal layers, each layer a single column in thickness. In alternate layers the rods pass to the right and to the left, crossing those of the next layer at right angles, and thus making a pattern of squares in the inner two-thirds of the enamel. In the outer third, where the rods bend abruptly upwards, those of superimposed layers no longer pass in opposite directions, but are all parallel; in fact, no longer admit of distinction into alternate laminae" (Tomes).

(iv) Individually, flexuous rods are found in the enamel of the *porcupine*, the courses of which are not confined to one plane. At the periphery of the tooth the rods run in a parallel direction.

(v) Parallel, slightly curved enamel columns are constant in the teeth of *hares*.

In the Order *Sirenia*, of which the *manatee* is an example, the enamel rods run in a perfectly straight course, and are not flexuous. This is therefore a very simple type.

Simpler variations still are found in *Pisces*. Some Families, e.g., eel, hake, etc., have a homogeneous type of enamel which exists as a tiny free structureless point on the dentine. The majority of fishes, however, probably possess a system of tubes which pass either partially or wholly through the enamel.

Tubular Enamel

GENERAL CHARACTERISTICS

Definition. As the expression implies, the enamel, instead of being a solid mass of rods and basis-substance, presents a tubular structure.

Origin.—The tubes are produced through the failure of calcification of the central zones of the rods formed by the ameloblasts of the enamel organ.

Distribution.—A class characteristic of Marsupials (except the wombat), but found also in some examples of *Pisces*, e.g., *Sargus*, barbel, porbeagle shark, and certain *Insectivora* (*Soricidae*) and *Rodentia*, such as jerboa, etc.

HISTOLOGY

The chief point of interest is the presence of a system of tubular canals in the substance of the tissue. These may be very extensive and numerous, or very short and few; and be confined to the inner or cortical aspects of the enamel or in its intermediate portions.

It has already been shown that in human enamel dentinal tubes often cross the amelo-dentinal junction, to end either cœcally or else in the enamel-spindles. But in addition to these, comparative anatomy furnishes many instances where other tubes occur. Dentinal tubes pass across the boundary and run into the enamel in marsupials (e.g., kangaroo).

In many fishes, the passage of these tubes from the dentine takes place, but the canals grow smaller in calibre as they approach the enamel cortex, which, however, they do not reach. Tomes describes and figures (*op. cit.* p. 56) enamel

from the tooth of a fossil shark in which the tubes pierce both the inner and outer zones. In *Sargus Ovis*, and *Cestracion* (*Heterodontis*) they likewise penetrate from the surface.

The tubes are found in the longitudinal axes of the enamel rods, not in the basis-substance; and their courses are generally

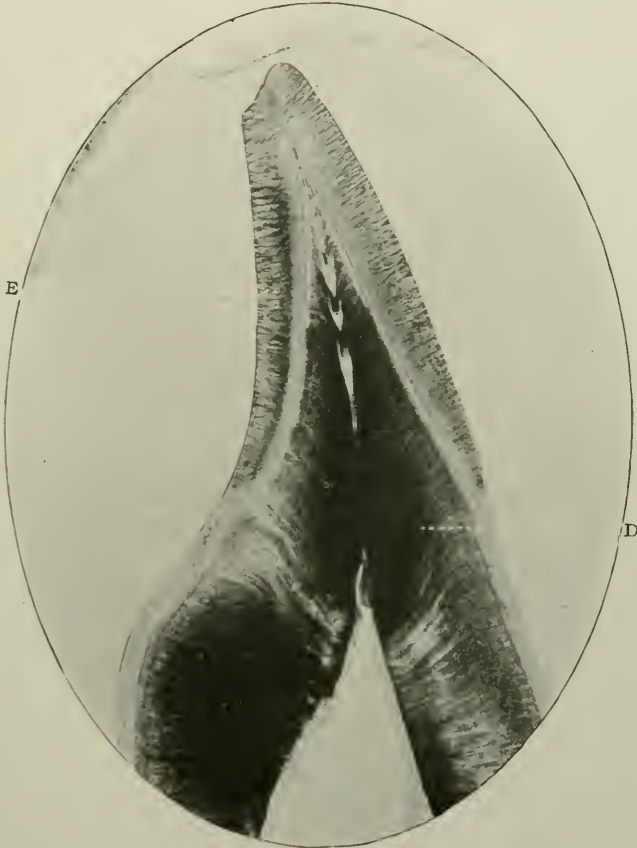


FIG. 78.—Sagittal section of incisor-like tooth of *Sargus Ovis*, showing tubular enamel. Prepared by grinding. Unstained. Magnified about 10 times. E. Enamel; D. Dentine.

fairly straight and parallel. In *Sargus*, nevertheless, after peripheral penetrations and running at right angles with the surface, they suddenly bend at an obtuse angle with their course (see Fig. 78).

It is difficult to offer a satisfactory explanation of the pres-

ence of these enamel tubes, but the opinion expressed by Tomes is, no doubt, correct.

Thus (p. 59) he writes: "If all enamel, in its development, passes through a tubular stage, then these are merely arrests of complete development and perpetuations of a stage which is transitory in placental mammals."

It is probable that tubular enamel is atavistic.

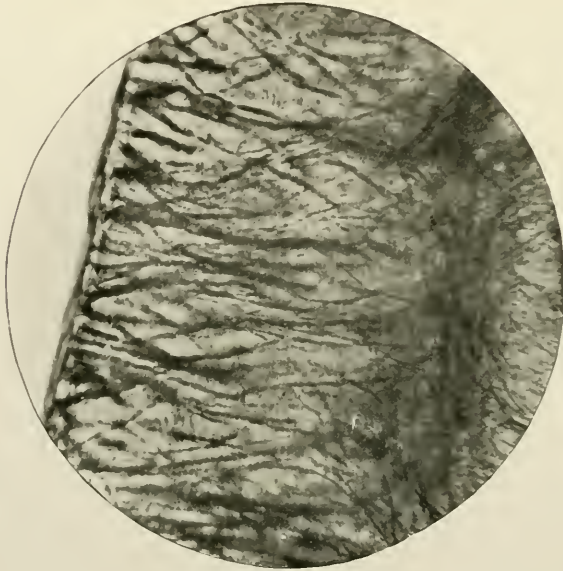


FIG. 79.—Same as preceding. Magnified 240 times.

Paul's views are not in accord with those of Tomes. In an article in *The Dental Record*, p. 496, 1896, this author observed:

"If we admit the general principle that all spaces or tubes in enamel are between and not within the rods, then the structure of genuine tubular enamel seems less difficult to understand. It is clear that any imperfect approximation of enamel cells must leave spaces between the rods which can only be filled with an indefinite intercellular substance, or possibly by further prolongations of dentine matrix, and in neither case is it likely that such intercolumnar matter would become calcified; because on the one hand, it is too

far removed from the influence of the odontoblasts, and on the other, because the calcifying energy of the ameloblasts is almost entirely expended upon their own internal petrification. I would therefore suggest that tubular enamel is an enamel in which there is an excessive amount of intercellular substance only imperfectly calcified, and much as it looks like tubular dentine, it is really formed on an exactly

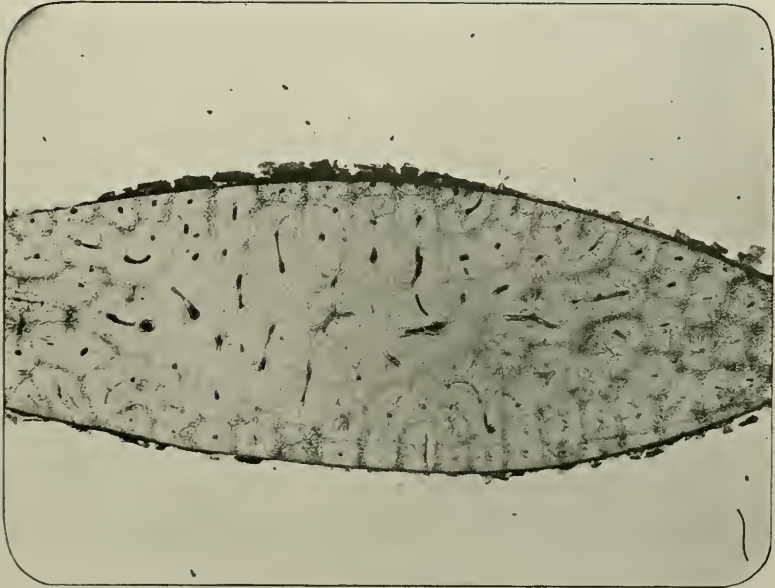


FIG. 80.—Transverse section of a rostral tooth of *Pristis*. Prepared by grinding. Stained with coloured collodion. Magnified about 10 times.

opposite plan. The one is a negative and the other a positive picture. In dentine the cells occupy the tubes, and the intercellular substance becomes the solid calcified matter; in enamel the tubes are represented by the intercellular substance, whilst the cells become the solid calcified matter.”

But it must be confessed that Paul's remarks seem hardly quite apposite in this connection, based as they are on the probably incorrect hypothesis that odontoblasts form dentine matrix. The syllogism he uses is faulty, inasmuch as the premises are not generally accepted, and are open to a dif-

ferent interpretation. In his studies of marsupial enamel, Howard Mummery's opinion coincides with those of Paul, who investigated the subject from the point of using the enamel of man. His conclusions (*Phil. Trans.* 1914) are that "The prisms (*sic*) are the first portions of the enamel which undergo calcification, that these prisms (*sic*) are arranged in layers corresponding to the rows of ameloblasts cells and that the spaces between the layers are calcified subsequently and cement the tissue together."

VARIETIES OF DENTINE

Tomes has classified Mammalian dentine as ortho-dentine (Hard, or unvascular dentine, sufficiently described in Chapter IV.), plici-dentine, vaso-dentine, and osteo-dentine. This is considerably more correct than that found in the writings of Owen, who somewhat confuses the two last-named varieties. Thus the older palæontologist described vaso-dentine as being composed of coarse channels containing cells, vessels, and nerves of the pulp—obviously the osteo-dentine of the latter author. By limiting the expression vaso-dentine to those forms in which blood-vessels *only* permeate the dentine, Tomes has cleared away many conflicting conceptions.

Plici-dentine

Definition.—"An ordinary dentine with its surface folded up and wrinkled into a greater or less degree of complexity" (Tomes).

Histologically considered, the dentine is hard, and unchanneled except by tubes which radiate, as usual, more or less at right angles to the pulp cavity.

If a pulp chamber be merely indented externally, or if portions of the dentine are somewhat invaginated, or the pulp itself, instead of being simple in outline, has several prolongations, no longer does a cylindrical pulp cavity result, but one with folded outlines.

This obtains in the teeth of the *Selache maxima* (Basking shark), or *Ichthyosaurus*.

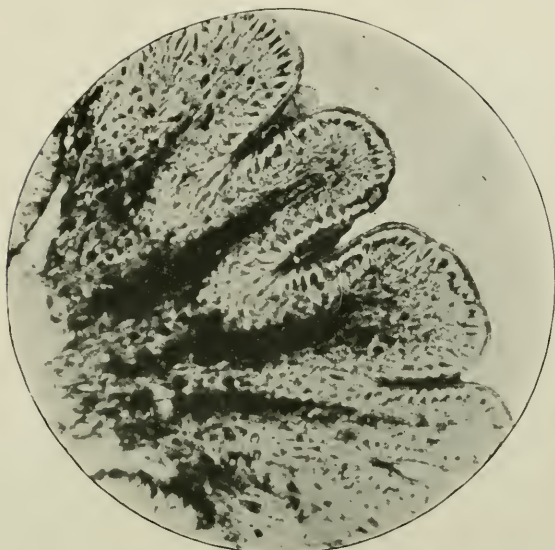


FIG. 81.—Transverse section near base of tooth of *Anarrhicas lupus*. Shows the plicated outlines of the dentine. Magnified 45 times. From a specimen in the collection of Sidney Spokes.

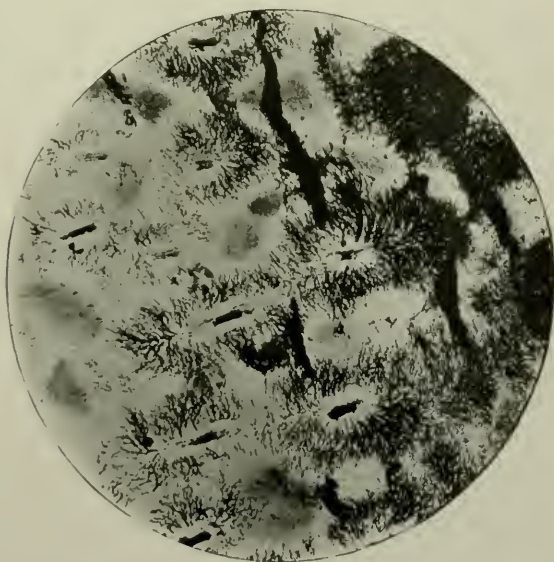


FIG. 82.—A form of Plici-dentine. Transverse section of tooth of an extinct crocodile (*Telosaurus*). Prepared by grinding. Unstained. Magnified 240 times.

In *Lepidosteus* the upper part of the tooth consists of a simple, single pulp chamber, with plicated walls, while at its base there are several pulp chambers running longitudinally, and variable in size, each always having radiating dentinal tubes. The peripheral pulp cavities run in straight lines in a centrifugal direction. And so also in *Anarrhicas lupus* (Fig. 81).

If these straight lines become twisted or curved or branched, a much more complex pattern is produced, as in the extinct

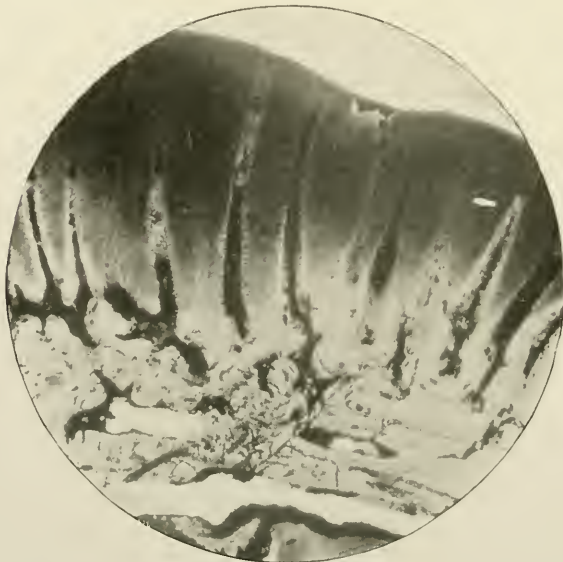


FIG. 83.—The same as the preceding. Longitudinal section. Magnified 240 times.

reptiles *Labyrinthodon*, *Leptognathus*, and *Dendrodus Biporcatus*; also an extinct Crocodile *Teleo-saurus*.

Many teeth are composed of groups of vertical denticles or primary pulp canals with radiating dentinal tubules. The periphery of each system occasionally blends almost imperceptibly with those of neighbouring denticles. Thus a regular pattern is seen in both horizontal and vertical sections. The teeth of the rostrum of *Pristis*, of an extinct hippopotamus, *Myliobates*, *Zygobates*, and others reveal this. In the first condition each dentinal system is permeated with fibrils from

the central pulp. The dentine is hard and unvascular, but not plicated.

Vaso-dentine

Another variety of this dental tissue, in which, broadly speaking, there are no tubules as such, is vaso-dentine. As

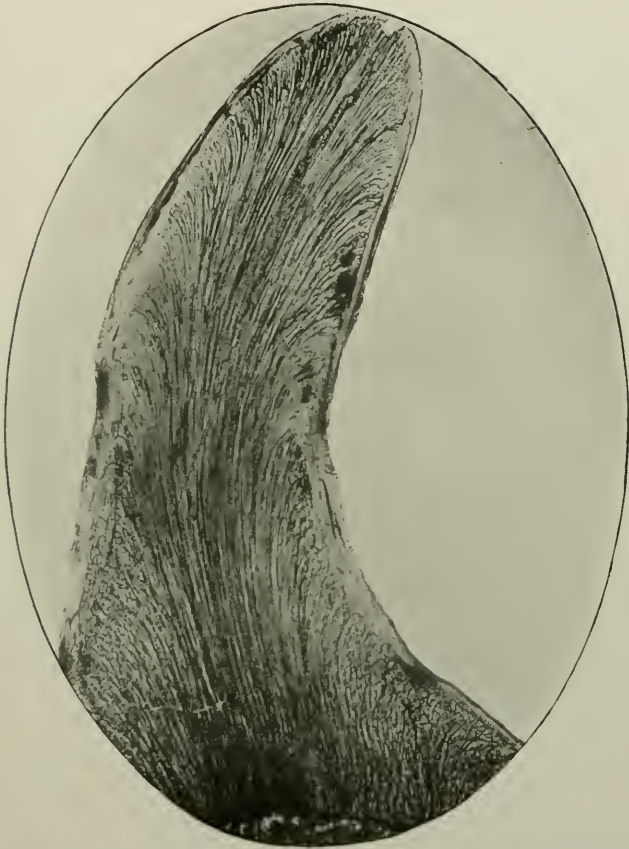

FIG. 84.—Sagittal section of an intermaxillary tooth of *Anarrhicas lupus* Prepared by grinding. Unstained. Magnified about 10 times. The mass of tooth is occupied by vaso-dentine.

the term implies, it is a vascular dentine. Extending outwards through the matrix is a series of moderately sized canals or channels of nearly uniform calibre throughout, each filled with a capillary from the pulp.

The channels run in the same direction as the tubes in hard dentine—that is, radially. A little below the free surface of the tooth their distal extremities are formed by loops, the convexities of which are outwards. Dried sections sometimes show thorn-like processes, running laterally from the vascular canals (see Fig. 85).

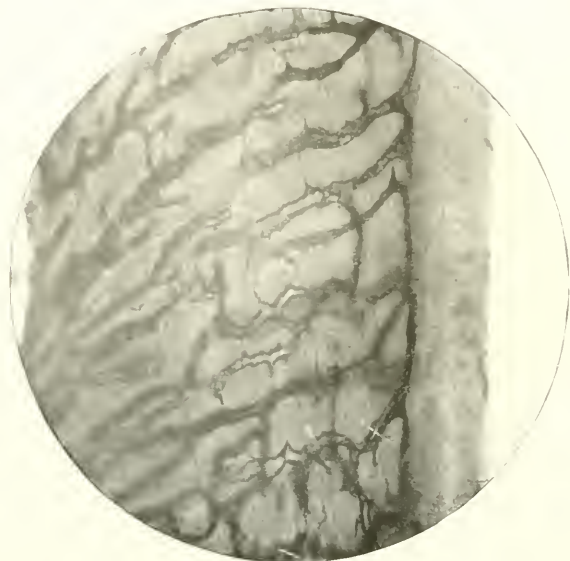

FIG. 85.—Vertical section of tooth of *Merluccius vulgaris* (Hake). Prepared by Weil's process, with the substitution of Golgi's method of staining. Magnified 250 times. Shows the vascular channels in the dentine, with their so-called "thorns," and the laminated matrix of the dentine.

The matrix of the dentine itself is slightly laminated.

Vaso-dentines are found in many fishes—hake, cod, *Sargus*, flounder, haddock, &c., in the former of which the canals are numerous, in the latter scanty. The dentine of the first-named is tubeless. The teeth of manatee and *Megatherium* possess vascular canals as a normal characteristic.

Osteo-dentine

In its general histological configuration, osteo-dentine closely approximates to that of compact bone, but the interstitial and peripheric lamellæ are wanting. Its irregular

spaces are analogous with the medullary canals of compact bone. They contain, however, in this case, not medullary tissue, but

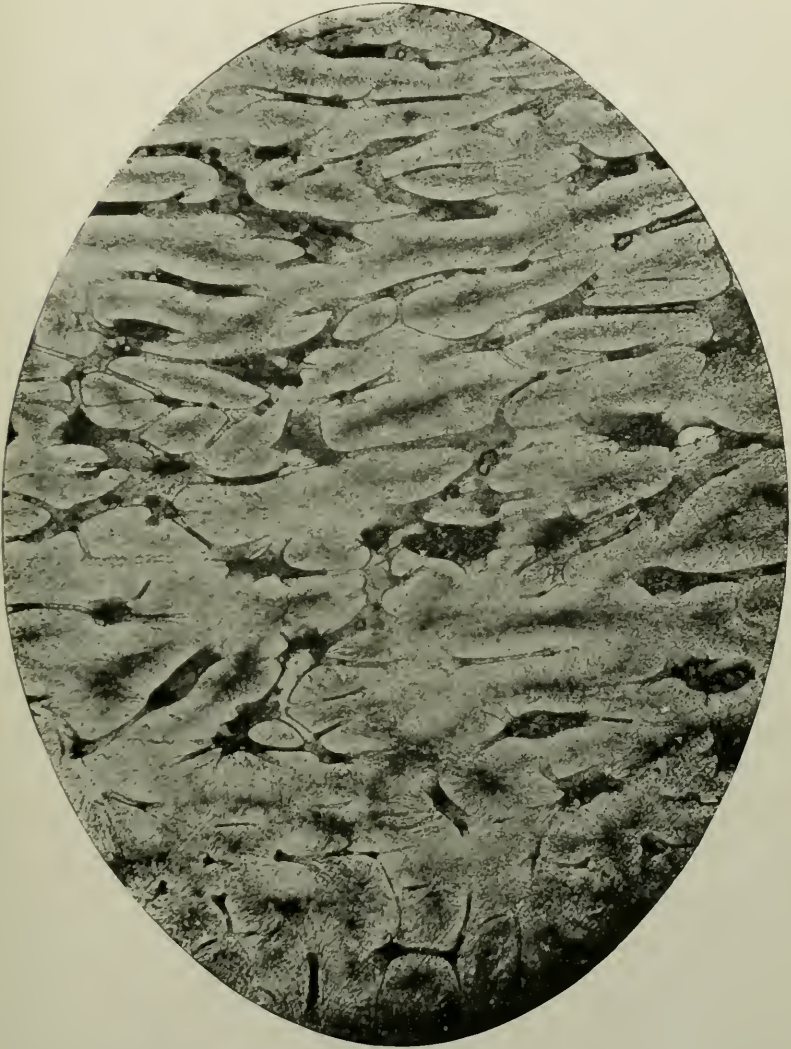


FIG. 86.—Vertical section of base of tooth of *Carcharias*. Osteo-dentine. Magnified 50 times.

pulp with round osteoblastic cells lining the walls in young developing specimens.

Osteo-dentine is found in the teeth of fishes, of which it may form the whole or part, as in the photomicrograph (Fig. 86).

In typical instances, when longitudinally cut, it is made up of more or less parallel trabeculæ, which extend through the

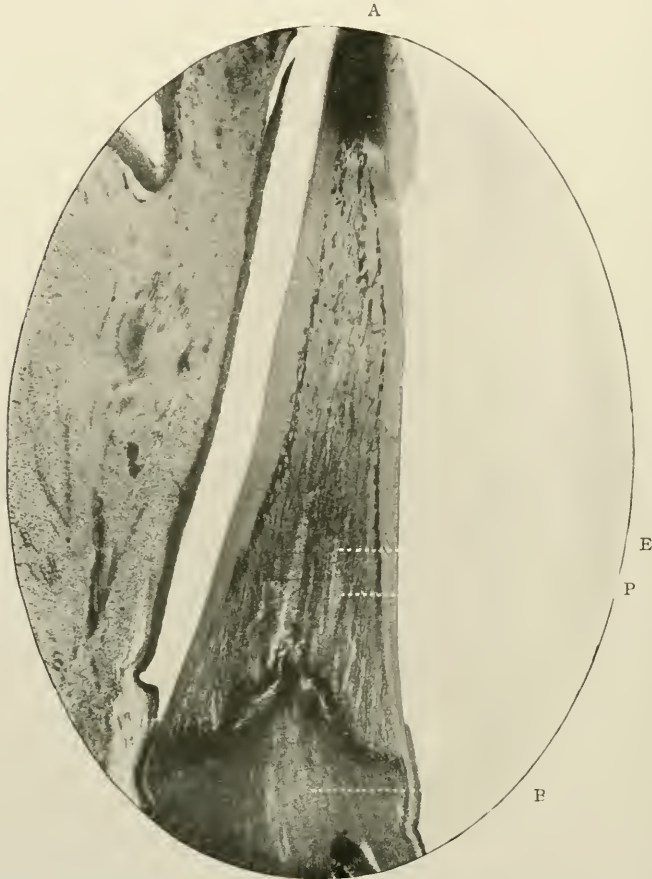


FIG. 87.—Longitudinal section of ankylosed tooth of *Esox lucius* (Pike). Prepared by the Author's process. Stained with Ehrlich's acid hæmatoxyline. Shows osteo-dentine. The full growth of the osteo-dentine is incomplete, a few elastic rods remaining in the centre of the tooth. Magnified about 10 times. A. Apex of tooth composed like the periphery of the dentine; B. Bone of attachment; E. Elastic rods, or uncalcified trabeculæ; P. Pulp *in situ*; M. Soft tissues of the mouth.

substance of the tooth, traversing the pulp tissue and dividing it into great numbers of pulp cavities. There is no very regular tube system, otherwise the result of this sub-division

into minor pulp cavities would be a flat form of plici-dentine in which the denticles are placed side by side in a regular and uniform manner.

In the osseous matrix lacunæ are sometimes found, and the

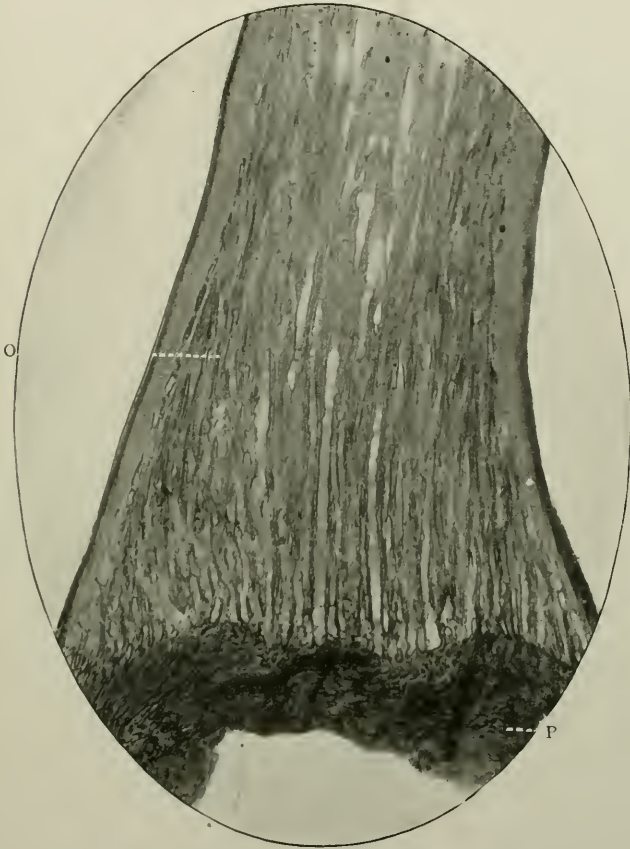


FIG. 88.—Vertical section of tooth of *Esox lucius*. Prepared by decalcification. Pulp tissue not retained *in situ*. Stained with borax-carmin. Magnified 40 times. O, Osteo-dentine; B, Bone of attachment.

dentine is more or less permeated by minute canaliculi. Many variations from this type exist. The structure of the teeth of *Lamna* (Porbeagle shark) may be cited as an example. Tomes (*op. cit.* p. 99) describes it as follows: "In an osteo-dentine medullary canals of varying size run, with a direction, roughly speaking, parallel to the long axis of the tooth, anastomosing

with one another; and from their sides wavy bundles of fine tubes radiate but do not run far; that is to say, its dentinal tubes do not radiate from any one central pulp chamber, but from an indefinitely large number of canals."

Recent Classification of the Varieties of Dentine

Röse has recently attempted a new classification of Dentine, and his communications to dental science, in these as in other matters, are always interesting. Thus he distinguishes:—

- (i) Pure or Ortho-dentine, a term suggested by von Kupffer,
- (ii) "Trabecular," or rod-like dentine,
- (iii) Osteoid dentine,
- (iv) Bone dentine.

(1) *Pure dentine* is a hard tissue with a smooth surface, of unilateral growth, being developed under an epithelial sheath or enamel organ.

This includes the following sub-divisions:—

- (a) *Tubular dentine*, *i.e.*, normal tissue containing the canals for the reception of protoplasmic cell processes,
- (b) *Vitro-dentine*, *i.e.*, tubeless and structureless, with no protoplasmic filaments whatever,
- (c) *Vaso-dentine*, *i.e.*, containing blood-vessels.

(ii) *Trabecular dentine*, corresponding to the "osteo-dentine" of Tomes, is a new term introduced by Röse, who defines it as "a hard tissue with numerous short protoplasmic-bearing dentinal canals, capable of increase of growth in all directions, but *not* growing immediately beneath, or in dependence upon an epithelial sheath."

This variety is probably formed similarly to intra-membranous ossification of bone. Thus, in the interior of the pulp cavity, at an early period of development, arise rod-like tracts of closely aggregated round cells. Within these tracts or columns, the first rudiments of structureless dentine are laid down exactly after the manner of the formation of the first layers of compact or cancellous bone. Single columns grow and increase in length and diameter. They thicken at the expense of the pulp tissue, become fused in places, and ex-

hibit fine-tubed dentinal systems. Ultimately with the completion of the growth of the tooth, instead of there being one pulp cavity, there are many wide tubular canals containing pulp tissue radiating in every case in a centrifugal manner.

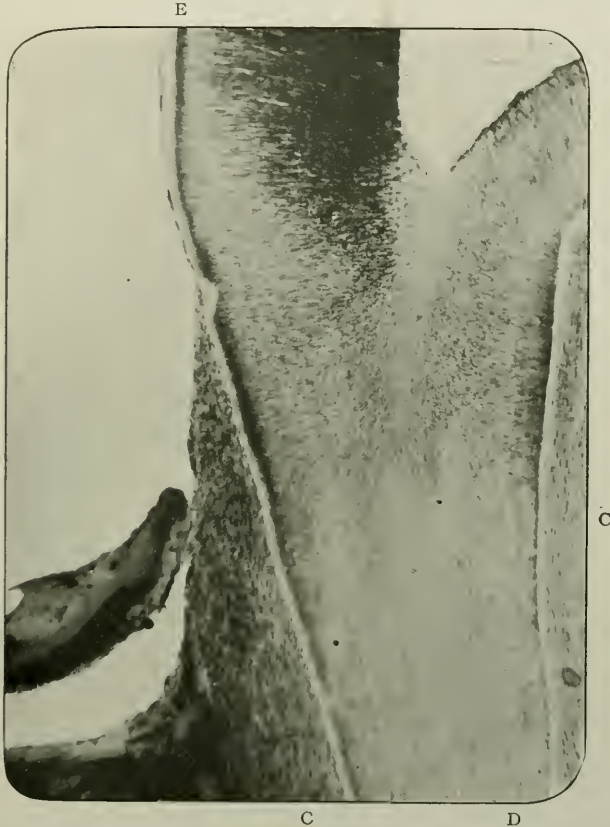


FIG. 89.—Vertical section of the cervical region of a molar tooth of *Didelphys Virginiana* (Opossum). Prepared by grinding. Unstained. Magnified 45 times. D. Dentine; E. Enamel; c. Normal lacunated cementum.

The first formed parts of the rods are structureless, and these are designated by this author as *Vitro-trabecular dentine*.

(iii) *Osteoid dentine* is a hard tissue growing in all directions; contains no protoplasmic enclosures; sometimes forms pure bone tissue and sometimes trabecular dentine.

(iv) *Bone dentine*, or *Osteo-dentine*, is a transitional form, between bone on the one hand and dentine on the other;

contains both bone corpuscles and dentinal tubules, each carrying a protoplasmic fibril.

MODIFICATIONS OF CEMENTUM

Little need be recorded about this. It is sufficient here to point out that the normal cementum of some of the Marsupial mammals (*e.g.*, the opossum, see Fig. 89), does contain prominent well-shaped lacunæ and canaliculi. Not only are the spaces of fairly uniform size, and the canaliculi of regular calibre and length, but the arrangement in layers or series is regularly parallel. Deposition of the tissue with inclusion of cemental corpuscles has, doubtless, proceeded without deviations from the original and earliest formed layer. The cementum, therefore, forms naturally a thick coating to the roots of the teeth, and comparison with the lacunated hyperplastic cementum of the teeth of man cannot fail to have a striking and convincing effect on the mind of the astute and experienced observer.

CHAPTER VII

THE DENTAL PULP

MICROSCOPICAL ELEMENTS:—(i) Odontoblasts; (ii) Pulp cells proper; (iii) Fibrous stroma; (iv) Basal layer of Weil; (v) Arteries, Veins, and Capillaries; (vi) and Nerves.

GENERAL CHARACTERISTICS

Definition.—The soft, vascular, and sentient organ which occupies the central portions of teeth, being naturally bounded, on all sides, by dentine, which thus constitutes its cavity.

Origin.—In Man and *Mammalia* it is the ultimate formation of the dentine papilla, which is itself derived from the stomodoeal parietal mesoderm (somatopleur).

Distribution.—All the calcified teeth of fishes, reptiles, and mammals have pulps.

Macroscopical Appearances.—A soft, thin, flattened, whitish organ, with, occasionally, lines of pink running in a longitudinal direction if removed from its bony cavity before *post-mortem* changes occur.

Its measurements in upper permanent adult teeth are as follows:—

Greatest average width, sagittally and midway between apex of root and incisive or occlusal edge: First incisors, 1.5 mm.; canines, 2.5 mm.; first premolars, 3.5 mm.; second premolars, 3.8 mm.; and molars, 5 mm.

Greatest average length: First incisors, 19 mm.; canines, 19.5 mm. (in a coronal direction, 23 mm.); first premolars, 17 mm.; second premolars, 15 mm.; molars about 15 mm.; third molars, 11.5 mm.

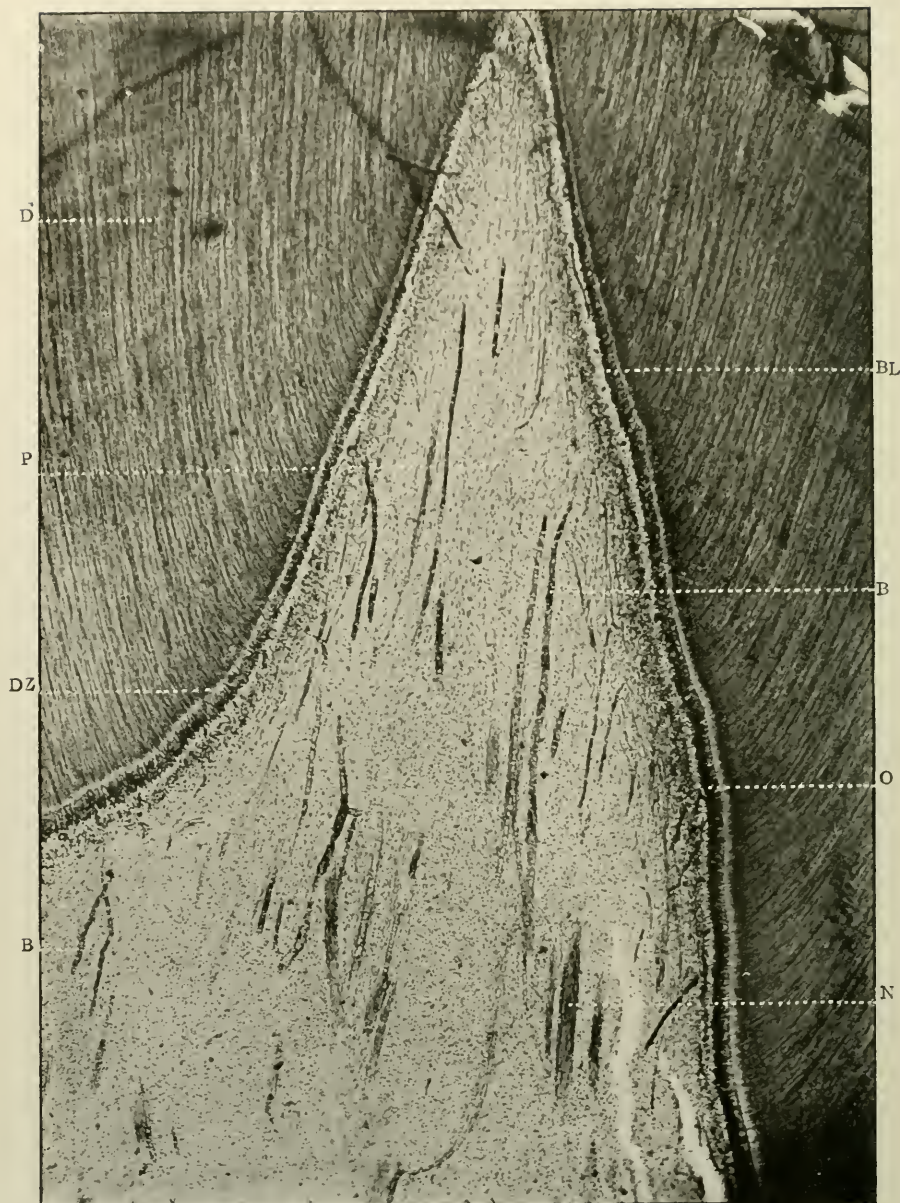


FIG. 90.—Longitudinal section through the corneal region of a young adult molar, the dentogenetic zone of which is on the point of calcification. The pulp is *in situ*. Prepared by the Author's process. Stained with Ehrlich's acid hæmatoxyline. Magnified 80 times. D. Dentine; P. Pulp tissue in cornu of tooth; D.Z. Dentogenetic zone; O. Odontoblasts; B.L. Basal layer of Weil; B. Blood-vessels; N. Nerve bundles.

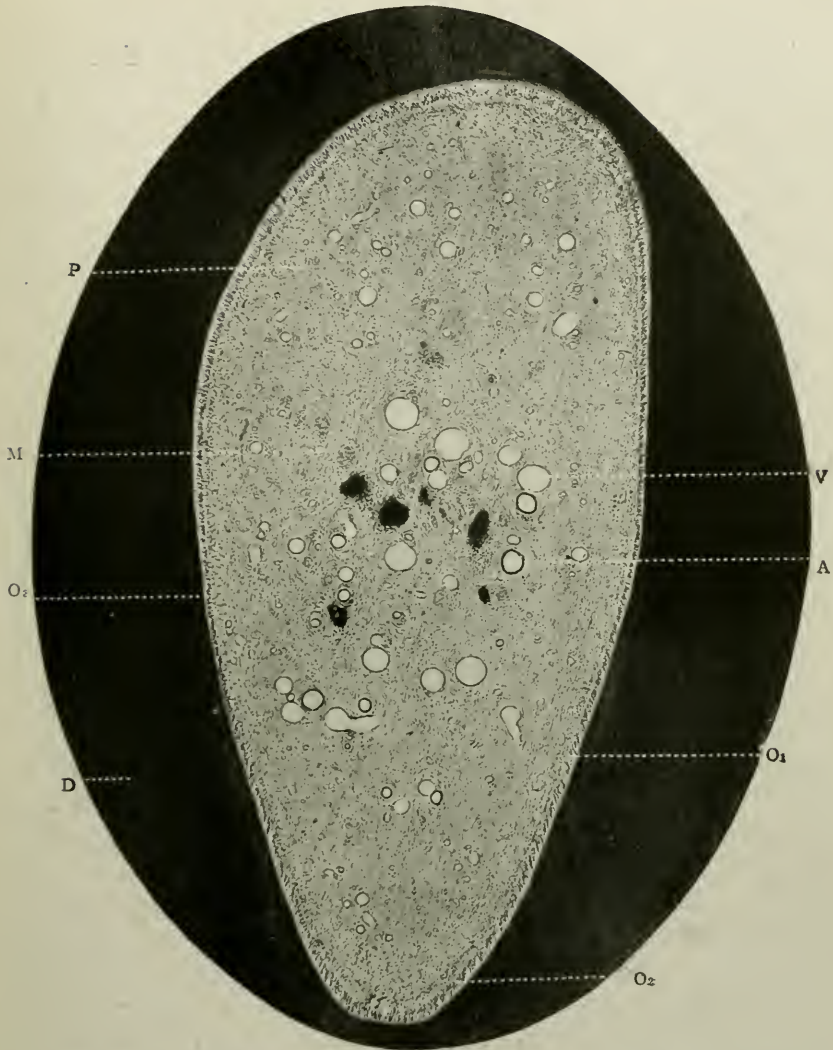


FIG. 91.—Transverse section of an adult canine, with the pulp *in situ*.¹ Prepared by the Author's process. Stained with rubine. Magnified 45 times. D. Dentine; P. Pulp tissue proper; O₁. O₂. O₃. Odontoblast layer; A. Artery; V. Vein; M. Myelinic nerve bundle.

¹The narrowest diameter of the pulp in the section of which Fig. 91 is a photomicrograph, measured 1.5 mm.; the widest diameter 3.35 mm.

For purposes of description it is advisable and convenient to arbitrarily divide the pulp as well as the pulp chamber into the (i) coronal region—the most distal portion which

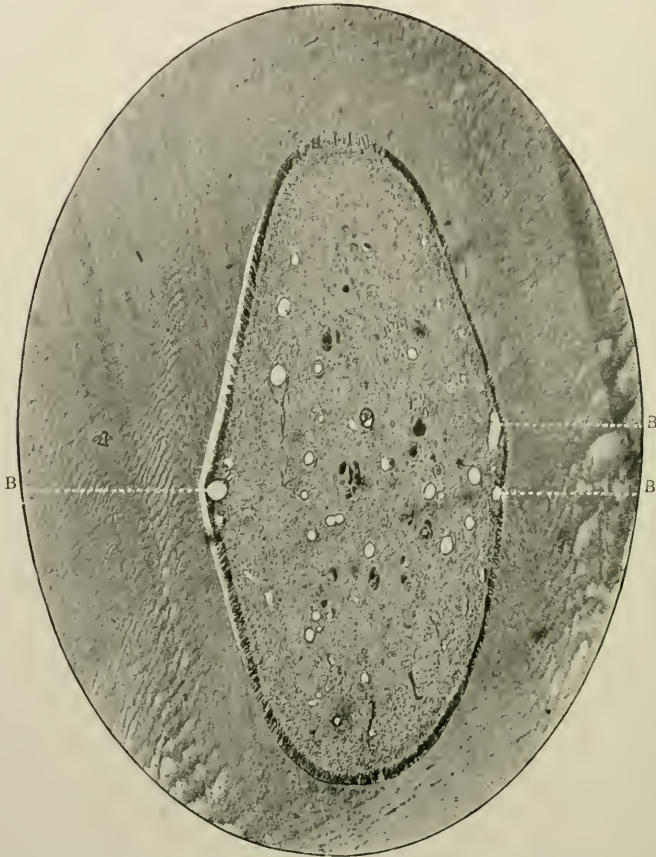


FIG. 92.—Similar to the preceding figure, but stained with Ehrlich's acid hæmatoxyline. Magnified 45 times. B.B.B. Blood-vessels in the basal layer of Weil.

projects into the crown of the tooth; (ii) the corneal region indicating one of the pointed or rounded extremities of the coronal region, (iii) the cervical; and (iv) the radicular regions—that is, at the neck and in the roots of teeth respectively.

HISTOLOGY

The dental pulp is a delicate connective tissue¹ consisting of ramified cells imbedded in a slightly fibrous stroma and granular transparent basis substance, and is plentifully supplied with blood-vessels and nerves.

Examined microscopically the several parts of the dental pulp of man exhibit objects of profound interest and importance—of interest because so many debatable and debated theories circle around the cells and nerves, and of importance because on its integrity depends the life-history of the tooth. To systematically study them, the subject may be divided into descriptions of (A) its cellular elements, (B) its connective tissue stroma or framework, (C) its vascular supply, and (D) its nervous system.

A

The Cellular Elements

The cells of the dental pulp fall naturally into two classes: of these the former is the more important when full growth of the organ has taken place; the second during its developmental periods. A cursory examination of an adolescent or adult pulp shows that two kinds of cells stand out clearly distinct from each other—the peripheral prominent layer, the so-called odontoblasts, and the central, smaller, less conspicuous pulp cells. The *latter* should be termed “Odontoblasts,” inasmuch as it is their function to build the matrix of dentine; while the *former* might be known as “pulp corpuscles,” signifying different work. See footnote on page 50, also the Appendix (page 327).

As bearing upon this point the statement of Röse may be recalled. He says (*loc. cit.*): “The odontoblasts of pure dentine have, like the formative cells of ‘trabecular’ dentine, quite the appearance of osteoblasts. If one wishes further to distinguish odontoblasts from osteoblasts, and chooses not to

¹ It is said to be similar to the jelly-like connective tissue of the early embryo, which in the case of the umbilical cord persists, and is called the jelly of Wharton.

make use of the commonly employed term 'scleroblasts' introduced by von Klaatsh, new and concise definitions must be introduced. It would be commendable in the future to define only those dentine-forming cells that range themselves along an epithelial sheath as 'odontoblasts,' quite indifferently, whether one refers to multangular cells below or cylindrical cells above. Hence the word 'odontoblasts' belongs only to those formative cells of true dentine. The formative cells of 'trabecular' dentine and bone tissues, which have never had any connection with an epithelial sheath should, on the other hand, be defined as osteoblasts."

(1) *The Cells of the Membrana Eboris of Kölliker or the Odontoblasts*

All along the periphery of young or mature pulps, arranged like a palisade in a single row two or three cells deep, is a collection of large, columnar epitheloid cells. This layer is most marked at the coronal portion of the pulp, and becomes appreciably less distinct at the cervical portion, while in the region of the root it is practically invisible. It is most clearly seen in the developing teeth of kittens and other embryos, as well as in complete sagittal longitudinal sections of young and adult human pulps, although in the latter the columnar character of the layer has disappeared. In transverse sections, too, this layer is visible, and it is not difficult to say with accuracy from which portion of the pulp the particular section has been taken. A closer inspection reveals the fact that the *membrana eboris* is composed of cells—the so-called odontoblasts, a term suggested by Waldeyer in 1870, and generally adopted since that time. In young pulps it consists of a single row of cells; in adult specimens several rows. These cells are of the utmost interest and moment. They will be described with regard to shape, size, relationships, structure, processes, and analogies.

(α) An odontoblast, generally speaking, in its very earliest phase of development, is represented by a large oval nucleus,

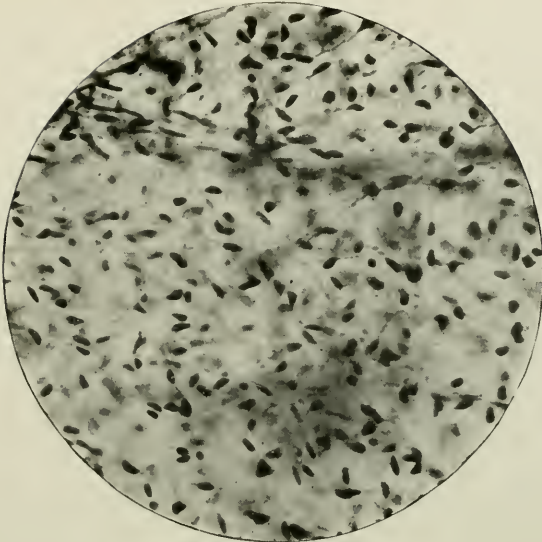


FIG. 93.—The structure of the pulp tissue. Prepared by Weil's process Magnified 250 times.

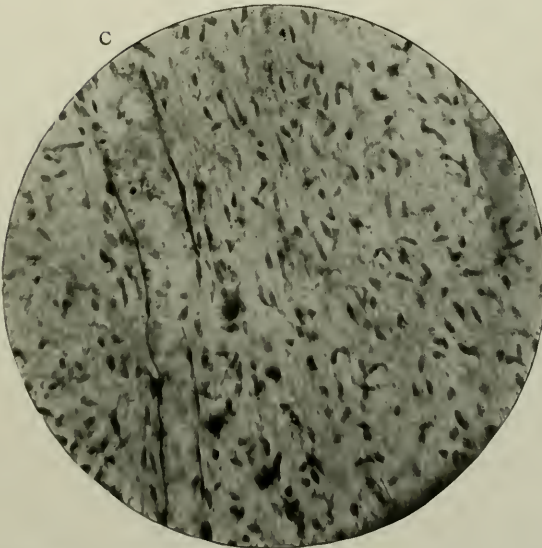


FIG. 94.—Same as the preceding. Prepared by the Author's process. Magnified 250 times. c. A Capillary.




FIG. 95.—Odontoblasts on the surface of the pulp. Prepared by fixing and hardening in formalin and alcohol, and cutting on an ether-freezing microtome. Stained with chloride of gold. Magnified 250 times. To show the enormous length of the dentinal processes of the cells.




FIG. 96.—Young odontoblasts from a developing tooth germ. Magnified 250 times. o. Odontoblasts.

devoid of visible protoplasm (Paul).¹ It may be recognised without difficulty, when about one-fourth its normal size. "It then consists of a large oval nucleus situated at its extreme base, with a short pyramid of protoplasm reaching towards the surface, and displacing the fibres of the surface pulp cells on either side. At this time it possesses no dentinal fibre, merely ending in a blunt point, though no doubt some delicate invisible protoplasmic processes are given off."

Later on, but while still young, and during its period of greatest activity, an odontoblast is a large bipolar, nucleated, epitheloid cell, more or less columnar in *shape*. This varies considerably in the same specimen, and ranges from that of a mere thin cord with bulbar terminations to that of a pear or banana, as Underwood² has likened it. Many cells are carrot-shaped, many caudate. Some are short and thick, some long and thin; some have, as is well known, square dentinal ends, others rounded extremities. But it would appear that those found in fully grown pulps are more or less pyriform in shape, while those in older specimens are reduced often to a thin fibrous bundle. A point worthy of notice is the fact that cells in the same plane—the same section—differ much in conformation. Where the pulp is constricted or flattened laterally, there the odontoblasts are thick and short; in the place where the pulp is broadest, however, they are long and thin. Moreover, in the latter situation, in adult pulps, they have enlarged extremities, that near the dentine sometimes presenting a stellate appearance, with the processes leaving the cell from the points of the star. Most probably this has been occasioned by shrinkage of the cells through the action of reagents. Often this dentinal extremity is triangular, often rounded. The central portion or body of the cell is very considerably attenuated and cordlike (see Fig. 97).

In teeth having cylindrical pulp cavities this diversity in shape is scarcely appreciable, and probably does not exist.

It may be said that the same remarks apply also to the pulps of fully formed deciduous teeth.

¹"A Contribution to the Histological Study of Dentine." *Trans. Odonto. Soc. of Great Britain*, p. 129, 1899.

²"Aids to Dental Anatomy and Physiology," p. 25, 1902.




FIG. 97.—Similar to Fig. 91. The odontoblasts marked o_2 in that photograph. Magnified 750 times. To show the peripheral processes extending into the dentinal tubes as the dentinal fibrils.

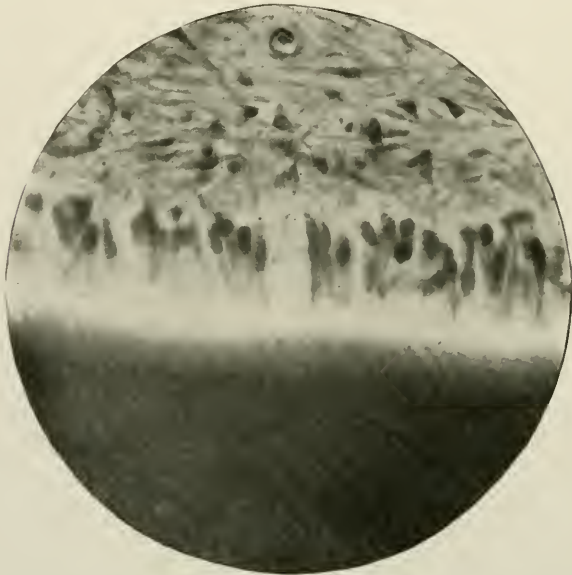


FIG. 98.—Similar to Fig. 91. The odontoblasts marked o_3 in that photograph. Magnified 750 times.

An odontoblast is said to have no limiting membrane.

Pathological conditions, such as inflammation, suppuration, or calcareous degeneration of the pulp do not seem, at first, to affect the shape of the odontoblasts: this rule obtains in all normal and abnormal examples. But later their forms become profoundly altered.

(β) With regard to *size*, odontoblasts vary considerably, the coronal cells being larger and more marked than the radicular cells of the pulp. This change in size corresponds in a measure to the length and width of the tubules, with which they are closely associated. The largest cells in an embryonic tooth-germ—viz., those under that part of the dentine which is covered by enamel, and called, for the sake of brevity, the coronal part of the pulp—have a diameter of 10 to 15 μ , and if they be compared to adult cells in the same situation, the latter will be found to vary from 25 to 30 μ in length, with a breadth of about 5 μ . Waldeyer¹ gives the size of adult odontoblasts, but does not compare them with developing cells—a point of importance which seems to have been overlooked.

It seems reasonable to suppose that this diversity of size would account for the increase of calibre of the fibril (and therefore tubule) as it approaches the pulp. Paul (*loc. cit.* p. 134) mentions that at the period of time when the dentinal matrix has reached a depth of $\frac{1}{20}$ mm., the odontoblasts are very long, but remain about 7.7 μ in width. In the ox they may attain the length of 50 μ . According to Kölliker, the stratum of the *membrana eboris*, in an adult pulp, measures from 41 μ to 83 μ in thickness; the odontoblasts themselves being 25 μ long, and 4 μ to 4.5 μ broad.

(γ) *Relationships* to surrounding structures:—

The author, in a paper written in 1889, showed that these cells are not packed closely together, but are separated by wide visible spaces, which in certain cases are filled with a “homogeneous substance, and small, round, and angular cells.” It is necessary to add that this is the case in developmental pulps, there being only a slight amount of intercellular tissue in most adult specimens. There are visible also in many

¹ Stricker's *Histology*, Vol. 1, 1870, p. 476.

instances, fine delicate spiral fibrils of connective tissue stretching into the dentine between the odontoblasts, in addition to the already mentioned structures. These fibres are not nerves, but form what may be termed the "supporting fibres" of the pulp. Reference to this point will again be made later on (page 130).

The long axes of the odontoblasts are approximately in the same direction as that of the tubules—a fact well brought out in transverse sections of pulp cut *in situ*, and best observed in its narrowest part.

In some sections, the cells are separated some distance by a gap, in which a capillary loop may lie quite close up to the dentine, and also pulp matrix—viz., delicate intercommunicating fibres. And in young pulps, in which dentine matrix is still being produced, many of the cells have attached to their distal ends lines of "transitional tissue" which Paul calls "collars." An odontoblast "collar" or shoulder is thus often seen, and was described by the earlier investigators as a lateral or median process of the cell. Mature cells do not possess it, only those of earlier stages of growth exhibiting it. A "collar" nearly always adheres to the dentine matrix, but very often to the cells themselves; is more highly refractile than any other part of the cells, and is the only portion in which they are in mutual contact. It is important to notice, however, that a "collar" is not part and parcel of the odontoblast. It is pierced by its dentinal process. It is probably derived from the pulp matrix, and really consists "of a delicate network of pulp fibrils woven about the necks of the odontoblasts upon which the secretion of the latter is poured and solidifies to form the dentine matrix." This is the interpretation supplied by Paul; but while the author agrees with the histological appearances just described, he cannot see his way clear to accept Paul's exposition or statement as to the lime-bearing functions of the odontoblasts.

(δ) In *structure*, the cytoplasm of the odontoblasts possesses a coarse degree of granularity, which does not disappear on the addition of a weak acid, and is apparently unaffected by glycerine, and certain other chemical re-agents. The distal ends

of the cells *when young* are apparently clear and homogeneous, the granularity being confined to the lower four-fifths. In transverse section, this granularity is due to either (i) a coarse, deeply staining reticulum or spongioplasm, (ii) metaplastic inclusions, or to (iii) the presence of numerous translucent globules (? of first-formed calcoglobulin). The author has failed to see the clear zone in adult odontoblasts, and considers that the spongioplasm becomes coarser through thickening of the nodes of the spongioplasm as time goes on, and the amount




FIG. 99.—Section of tooth germ before the surface cells of the pulp have undergone any differentiation. Magnified 250 times. (*Photomicrograph by Paul.*)

of the hyaloplasm is proportionately diminished. Hence he again differs from Professor Paul in his belief that the clear zone is due to calcoglobulin.

The nucleus of an odontoblast is large, ellipsoidal, and prominent, and is situated at the basal extremity of the cell. Its wall is well-defined, and its karyoplasm pronounced. Occa-

¹ In this connection a remark by Professor Schäfer (*"Quain's Anatomy"* vol. I., part II., p. 174, 1898), is of profound significance: "It would seem that the presence of certain inorganic substances, and especially calcium, is essential to the life, and therefore to the functions of protoplasm; but in what manner the lime may be combined with the organic basis of the living material, remains as yet quite undetermined."

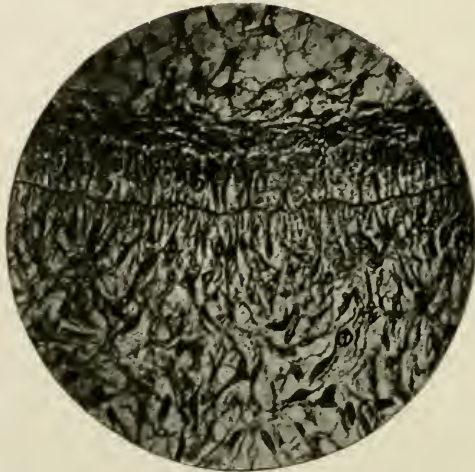

FIG. 100.—A later stage than Fig. 99. Shows surface pulp cells becoming arranged in a fairly regular layer, with their chief processes directed towards the ameloblasts. Magnified 250 times. (*Photomicrograph by Paul.*)

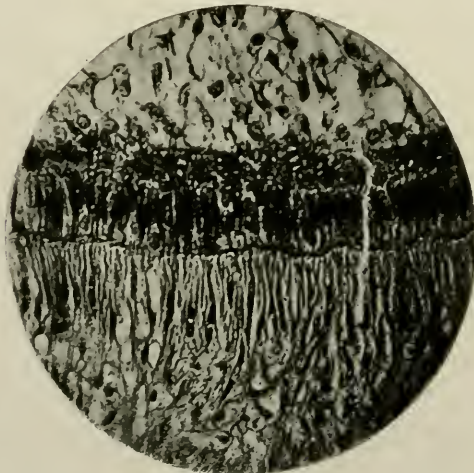

FIG. 101.—Shows complete evolution of surface pulp cells. They have produced a superficial fibrous layer, and their nuclei are now in a "resting" state. The odontoblasts have not yet appeared. Magnified 250 times. (*Photomicrograph by Paul.*)

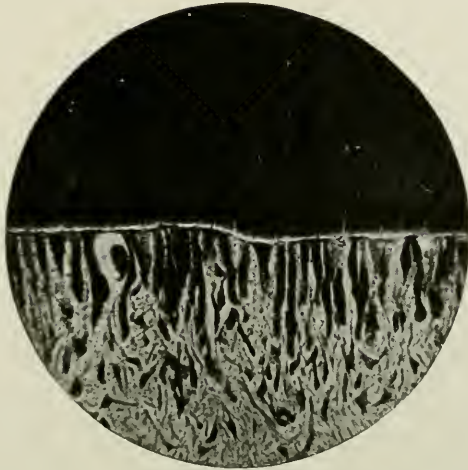

FIG. 102.—Shows the line of "transitional tissue" along the top of the odontoblasts. At one place it stretches across a gap between two cells caused by the intervention of a blood-vessel undergoing degeneration. Magnified 250 times. (*Photomicrograph by Paul.*)

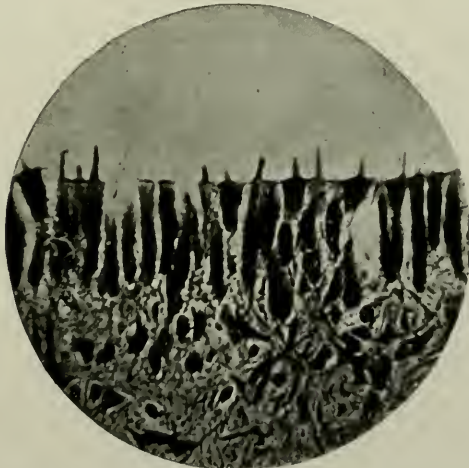

FIG. 103.—A very thin section of odontoblasts, showing the pulp fibres investing them, and ending in the "transitional tissue" forming the shoulder or collar of each cell. Magnified 340 times. (*Photomicrograph by Paul.*)

sionally nucleoli may be found. The nucleus is usually placed at the centripetal end of the cell as has been already stated; but Paul has shown that it may be found in the middle, and occasionally quite at the distal end, where its long axis lies transversely to the cell. In this latter case, however, it must not be forgotten that the odontoblast itself is very short, or has been cut obliquely so as to appear short. If a cell was lying a little out of the level plane of its neighbours, in a vertical section, the nucleus would probably appear higher in the body of the cell than usually obtains. Paul thinks that it exhibits an exhausted condition, and has ceased to grow. An odontoblast may have two nuclei in the same cell, a "condition by no means uncommon," and, rarely, atrophied nuclei have been observed by Paul in the dentinal fibril, just beyond the transitional tissue. These appearances are interpreted by him as being due to coalescence of two odontoblasts, the lower cell reinforcing and rehabilitating the degenerated upper odontoblast.

(e) The *processes*.—These cells are remarkable for their polar offshoots, which may be classified as (i) central or basal; and (ii) peripheral or dentinal.

Of these, the first named are most easily observed in sections when ordinary stains are used, but the latter cannot be so clearly demonstrated unless special methods of staining with hæmatoxyline or gold chloride are adopted. Carmine and rubine and a few aniline dyes show them also.

(i) The peripheral poles of the odontoblasts, extend into and enter the tubules of the dentine, and are here called dentinal fibrils. In some cases they are bifurcated: several fibrils may emanate from one cell; and nothing else can be seen entering the tubule. Boll¹ has counted as many as six processes belonging to one cell.

The length of a peripheral process of an odontoblast may measure 4 or 5 mm. It thus may measure in extent one hundred and fifty times the length of the cell body. This fact alone raises an odontoblast to a much higher level than the usual cells of a mesodermic tissue. As a matter of fact, the dentinal

¹ "Untersuch. der Zahnpulpa." *Archiv. für Mikrosk. Anat.*, p. 73, 1868.

fibril issuing from an odontoblast renders this cell one of the most extraordinary in the body. In the human economy no more remarkable cellular units are known microscopically than the cell bodies of certain neurones, which may possess, as processes, axones extending to a distance varying from 3μ or 4μ to one metre in length. Second to these are the truly marvellous odontoblasts whose processes—the dentinal fibrils—may measure 4 mm. There can be no doubt whatever that these wonderful cells possess high functional possibilities.

(ii) It is no difficult task to demonstrate the basal offshoots of the odontoblasts. They are exceedingly thin and may intercommunicate with each other. This, however, is not at all satisfactorily proved. They present no varicosities of surface, are not swollen or twisted, and take the stain less deeply than other portions of the pulp tissue. They are invisible in young developing cells. Special stains, such as Golgi's, Stroebe's, or methylene blue have failed up to the present time to trace back these central poles to the terminations of the nerves of the pulp.

According to Magitot,¹ the basal processes of the odontoblasts are continuous with the branches of large reticulate cells, situated as a layer, beneath them. These latter cells are placed in direct line with the nerve terminations (see diagram, Fig. 127). In this manner, the sensibility of the dentinal fibril might be accounted for. Recent workers have not, however, corroborated Magitot's views, and his deductions, in the light of more modern research, would seem to be incorrect.

In the dental pulp of the ox, these basal processes assume a large size. If an incisor is removed from the jaw of an ox, immediately after the animal has been slaughtered, and then broken longitudinally in a vise, the basal poles may be demonstrated in a few minutes, while still fresh. A small piece of the *membrana eboris* is removed and teased in salt solution; while carmine or chloride of gold clearly stains the long processes.

Aitchison Robertson² has studied these offshoots in the ox, and

¹ *Journal de l'Anatomie de M. Charles Robin*, Paris, 1881.

² "On the Relation of Nerves to Odontoblasts, and on the Growth of Dentine." *Trans. Roy. Soc. of Edinburgh*, p. 323, 1891.

he reports that "odontoblasts were seen which had become separated from the other cells, and had drawn out along with them their internal or root process. This was in some cases of great length, and could be traced for some distance into the pulp. In other cases, part of the dentinal fibril still remained attached to one extremity of the separated odontoblasts, while

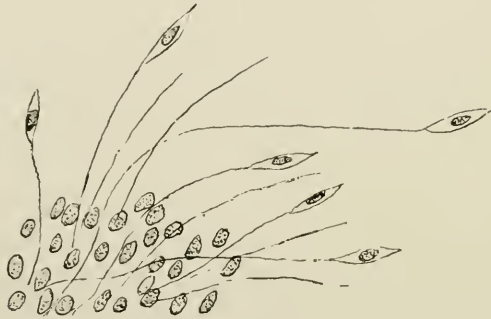


FIG. 104.—Portion of surface of the pulp teased in potassium anhydrochromate solution. Shows the very long central process belonging to each odontoblast and entering the substance of the pulp. The odontoblast has fallen off in many cases, and leaves the central process projecting like a fine hair or nerve fibre. (After Aitchison Robertson.)

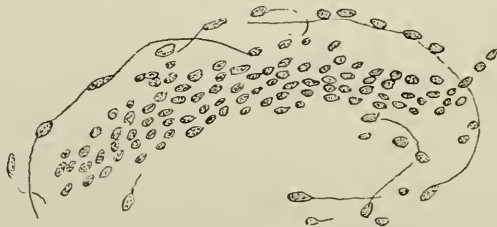


FIG. 105.—Apparent direct continuation of the root process of the odontoblasts with the axone of a nerve. (After Aitchison Robertson.)

from the other extremity, the long internal root process was seen extending into the pulp." The processes sometimes measured even twelve times the length of the odontoblast cell, and in some instances passed into groups of nerve fibres, amongst which they apparently ran for some distance before they acquired a myelinic sheath. This author significantly observes: "I am convinced that the central processes of the odontoblasts become continuous with the nerve fibrils. . . . The long central process seems to become the axis-cylinder of a

nerve fibre, which gradually acquires a primitive sheath in which the medullary or white substance slowly accumulates, till an ordinary medullated nerve results. . . . It is very difficult to say whether all the odontoblasts send in their long processes to join the nerve fibres."

It is a histological fact that odontoblasts possess processes running towards the pulp; but it has not been proved, in spite of Robertson's work, that they are the direct continuation of the pulp myelinic nerve-fibres.

Their existence is doubted by Hertz ("Untersuch. über den feineren Bau und die Entwicklung der Zähne," in Virchow's "Archives," Bd., 37, 1866) and by Paul.

(5) There is a certain amount of *analogy* existing between the odontoblasts, and certain epitheloid cells, found in the olfactory regions of man and animals, in the ganglionic layer of the retina, and the auditory cells of the *macula lutea* of the membranous labyrinth. Their processes are somewhat similar, their structure identical, their shape modified only by the mutual apposition of neighbouring cells.

(2) *The Other Pulp Cells*

The cells of the pulp proper, viz., those situated in the central portions of the tissue, differ in size and shape during the various stages of the growth of that organ. In developing teeth they are large, and have rounded angular or spindle-shaped outlines. In short, they partake of the nature of embryonic cells generally. Their nuclei are large, prominent, oval or lenticular, contain karyosomes and chromatin, and are devoid of nucleoli. Near the superficial portions of the pulp they are very loosely held in the reticulum by the connective tissue stroma; and here, more spindle cells are visible.

In adult teeth, the pulp cells are chiefly stellate or angular in shape, with numerous branches. Their number is greater, as a rule, than the ordinary round cells; but cells of any description are comparatively few. The branches are long and multiplied, and interlace with one another, giving the pulp somewhat the appearance of a mucoid tissue. Fewer cells exist in the radicular region of the organ. A few insignificant-

looking odontoblasts are found; but the mass of the pulp seems composed of bundles of thick and thin connective tissue fibres and cells running in all directions.

The morphology of the individual cells is best studied in fresh pulps which have been teased-out in physiological salt solution, and suitably stained.

B

The Connective Tissue Stroma

Extending throughout the pulp in every direction, like an exceedingly minute net, is the connective tissue stroma or scaffolding in which the cells are imbedded. This framework serves two purposes, as an imbedding material for the pulp cells, and as a support to sling up the soft delicate organ in its bony casing, in much the same way as marrow is supported in the medullary cavities of bone. The fine fibres appear sometimes to enter the dentinal tubules, but they are most often seen attached to the free margin of the matrix of the dentine, where, most likely, they are in reality the odontogenic fibres. The author in 1893 was the first to draw attention to those "supporting fibres" of the pulp. They are generally recognised by their spiral appearance, and have recently again been studied by Von Korff (*Archiv. für Micros. Anat.*, 1907) and Studnicka (*Anat. Anzeiger*, 1907). It is probable that these connective tissue fibres are considered by Howard Mummery (*Proc. Roy. Soc. Medicine*, 1912) to be the terminations of the myelinic nerve fibres of the pulp.

In the sub-odontoblast region of the pulps of adult teeth the basal layer of Weil is seen. This, first described by the late W. A. Weil, of Munich,¹ in his monograph on the Dental Pulp, consists of a distinct clear layer of fibres with a great scarcity or even absence of cells. In describing it, he wrote: "The layer contains no cellular elements or nuclei; it appears rather as a web of extremely fine fibrils, which do not run perpendicularly through the layer, but running obliquely towards the deeper layers, interlace with one another in a crosswise direc-

¹"Zur Histologie der Zahnpulpa." Leipzig, p. 55, 1887.

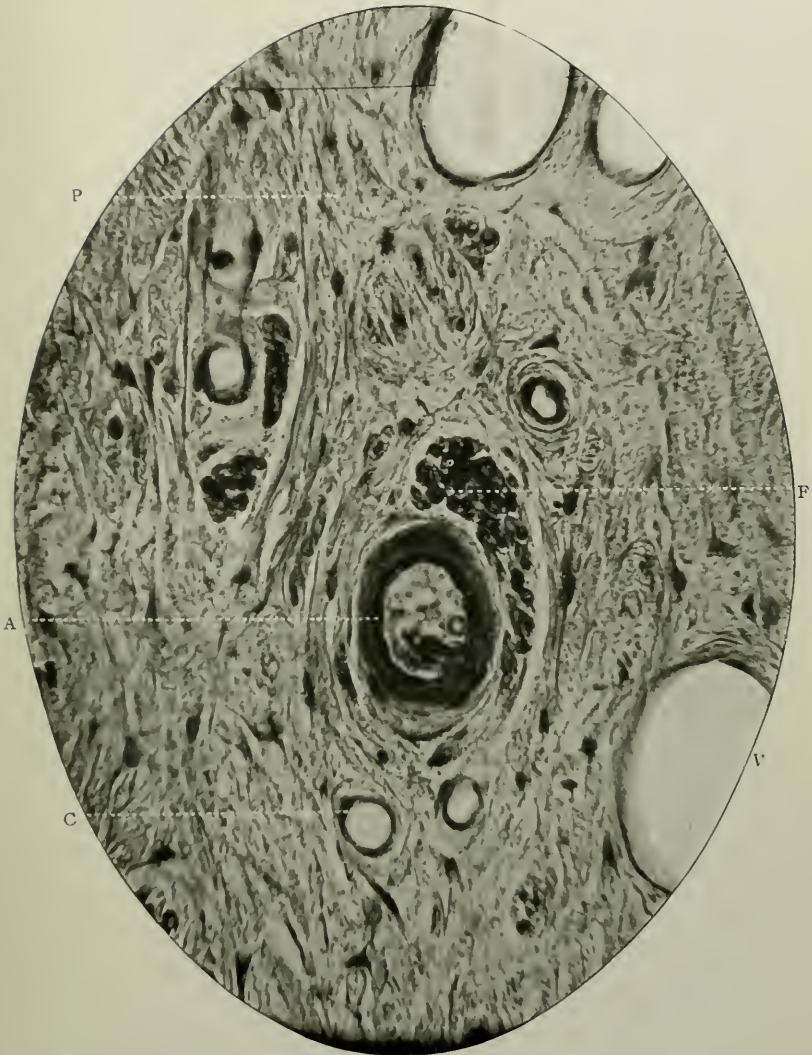


FIG. 106.—The dental pulp. Prepared by the Author's process, and stained with Ehrlich's acid hæmatoxylenec. Magnified 750 times. A. Artery; C. Capillary; v. Vein; P. Pulp tissue proper; F. Fasciculus of myelinic nerve fibres.

tion. . . . It may be said, with perfect security, that they arise from the projecting basal ends of the odontoblasts. It is, however, surprising that these offshoots do not follow the axial directions of the odontoblasts, but turn sideways to one direction or another, and thus form the crossings."

The basal layer measures at the coronal part of the pulp 0.025 mm. in diameter, and gradually becomes diminished in size, until it no longer exists in the radicular region.

This statement is corroborated by Partsch,¹ of Breslau, and deserves great attention.

Further, Howard Mummery² refers largely to this in a recent paper, where he says:—"According to my experience the layer is not visible in young teeth in the situation of the rapidly depositing dentine at the open, uncompleted end of the root." And it may be added, that the author has repeatedly observed it in the mature pulps of deciduous and permanent teeth as well as in certain pathological conditions; but never in young growing teeth. Professor Paul has, however, noticed "a clear zone of tissue just beneath the most actively growing young odontoblasts." He declares:—"It seems to me, after many careful examinations, that the appearance is not due to the presence of a specialised tissue, but is simply owing to a rarefaction of the pulp preceding the active extension of the odontoblasts, which are of course progressing inwards through the pulp matrix."

Regarding the exact nature of the basal layer, it is a difficult matter to decide. It is certainly fibrous; but whence the fibres come and go, and whether the whole layer is an artificial product or not is as yet undecided.

Weil himself considered that the fibres were undoubtedly continuous with the odontoblasts, and might thus be a means of communication between them and the nervous system of the pulp. He never was able to prove, however, that these delicate fibres were amyelinic nerves. Repeated attempts at differential staining to ascertain if they were of a nervous character have failed. A stray capillary may cross the layer

¹ *Deutsche Monatsschrift für Zahnheilkunde*, p. 322, 1892.

² *Journal of British Dental Association*, p. 779, 1892.

and get into the spaces between the odontoblasts. Howard Mummery does not believe that all the fine fibres are in continuity with the odontoblasts; many of them penetrate through the layer and enter the dentine matrix.

Its existence as a true histological structure is doubted by Ebner and Röse.

von Ebner says:—"The odontoblasts are attached to the dentine by means of the dentinal fibrils—they cannot, therefore, when the inner portions of the pulp shrink up (through

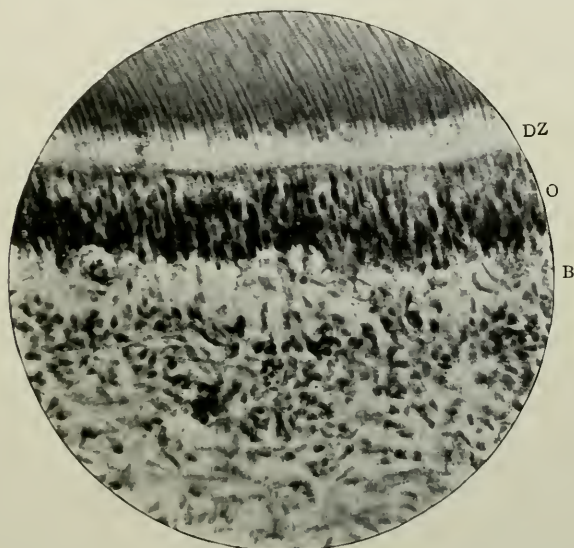


FIG. 107.—The pulp *in situ*. Prepared by the Author's process, and stained with Ehrlich's acid hæmatoxyline. Magnified 250 times. B. The basal layer of Weil; o. Odontoblasts; d.z. Dentogenetic zone.

the action of reagents used in the Koch-Weil balsam process) be very well torn away; but the layer immediately under the odontoblasts will seek to approach the centre of the pulp, and before it comes to a rupture, the tissue elements which form the connection of the odontoblast layer with the pulp lying beneath, will be very strongly stretched. These tissue elements are chiefly fibres, and in this way a layer of fibres can be artificially produced which before was non-existent. . . .

Dr. Weil shows that from the tissue of the pulp, rich in cells, which is found beneath the *membrana eboris*, numerous fibres

penetrate toward the odontoblasts. But that these fibres, in life, exist as a special basal layer cannot be proved by Dr. Weil's method."

And thus also Röse.

But Howard Mummery considers that the facts of the non-distortion of blood-vessels in the layer, as also its absolute disappearance at the growing extremity of the roots of teeth with large apical foramina must be taken into account, and disprove the theory of shrinkage of the pulp.

C

The Vascular Supply

The pulp is freely vascularized by branches which are derived from the Posterior Dental, Infra-orbital and Mandibular divisions of the Int. maxillary artery.

They enter the teeth through the apical foramina of their roots, generally as one large trunk, or as three or more small ones. Shortly after their entrance into the pulp, the vessels branch repeatedly, become smaller in calibre, until near the surface they form a simple capillary network which may measure 8μ to 12μ in width. It may be stated in general terms that there is no collateral circulation in the pulp. In this respect the condition resembles that which obtains in the terminal blood-vessels of the brain, the *arteria centralis retinae* of the eye, and in a lesser degree also in the walls of the heart.

During the period of development the vascular system covers a large area of the dentine papilla. The main arterial trunk, proceeding in a longitudinal direction through the centre of the tissue, decreases in diameter very gradually, till near the edge of the dento-genetic zone, when it almost suddenly and rapidly becomes narrower, and is ultimately lost in a dense capillary plexus. The branches have the peculiarity that very often they issue at or about right angles with the main vessel (see Plate I).

In adult pulps, this angular method of division is not so

evident; the larger vessels are located chiefly in the axial portion, whence numerous branches pass in all directions.

In the corneal regions many anastomatic capillary loops have their convexities directed towards the dentine. As a rule, these capillaries extend as far as the basal layer of Weil; but occasionally, as has been already mentioned, one or more may cross, and pass between the odontoblasts (Fig. 92).

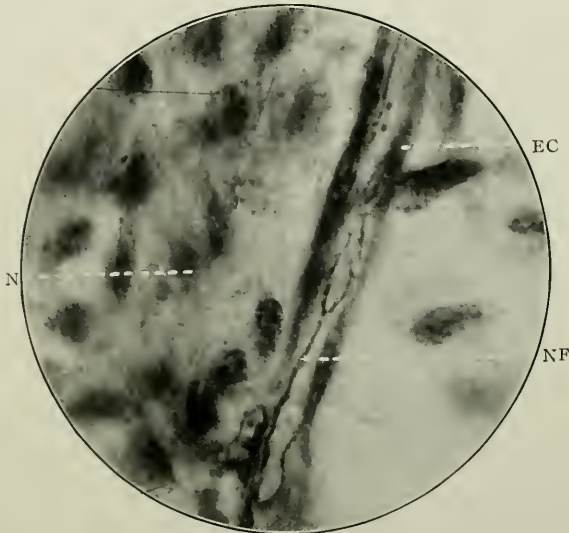


FIG. 108.—A sympathetic nerve fibre running along the wall of a capillary of the dental pulp. Highly magnified. N.F. Nerve fibre; E.C. Endothelial cell of capillary wall; N. Nucleus of pulp cell. Preparation and photomicrograph by Dr. H. Box, Royal College of Dental Surgeons, Toronto.

The arteries vary in size, in different pulps, but a main trunk may measure about 83μ in width, while the diameter of the lumina of the capillaries is roughly about 8μ .

The former are accompanied, not only by their respective veins, but also by fasciculi of myelinic nerves, which run side by side, sometimes so closely that nothing but a few connective tissue fibres and cells intervene between the outermost portion of the external coat, or *tunica adventitia*, of the artery, and the perineurium of the latter.

By selective staining it is possible to demonstrate the sympathetic nerve fibres which are distributed to the middle and outer coats of the vessels.

Properly stained horizontal sections of pulps reveal in a most beautiful manner both the approximate number of blood-vessels and also their differences in structure. In typical canine pulps, cut crosswise through the cervical region, the author has counted 10 of the former. The typical veins, several of which were just macroscopically visible, exceeded this number by 14, while the capillaries were practically countless.¹

Histologically considered, the vessels of the pulp differ very considerably.

The Arterioles.—Structure.—The wall of each small artery consists of three coats, viz., the *tunica intima*, *media* and *adventitia*, the first-named being indistinguishable, except under high magnifications, and the *media* being very marked.

(i) *Tunica intima.*—Here is found, forming the lining of the lumen of the vessel, a flattened layer of thin, singularly elliptical endothelial cells, each having a round or oval nucleus. When the blood corpuscles have not been retained *in situ* in the section, the cells may be sometimes seen to project into the lumina. External to the endothelial lining is an attenuated double wavy line, continuously circling the artery. This is known as the elastic layer of the inner coat, and it is made up of numerous longitudinal, closely arranged yellow elastic fibres. (ii) The *Tunica media* is composed mainly of plain muscular tissue, which makes this coat the thickest and most prominent of all. It is arranged circularly round the vessel, and its component parts are made up of unstriated muscle fibres with elongated nuclei. The elastic tissue of the larger arteries is wanting in this coat in the vessels of the pulp. (iii) The *Tunica adventitia*, consisting of areolar or connective tissue fibres and cells, with nuclei placed in the long axes of the cells, represents the outer coat of the artery. These fibres and cells, too, run circularly round the vessels and blend intimately with the connective tissue fibres of the pulp.

¹ These figures are introduced in this connection, in order to supply the reader with some idea as to the numbers that may be computed, *i.e.*, to demonstrate that the arteries of the pulp are not counted in hundreds, but in tens. It is obvious that the numbers given are never constant.

Nervi vasorum are present in this coat. They belong to the sympathetic nervous system.

The Veins differ from the arteries in the fact that the size of the middle coat is greatly reduced, and the endothelial cells are shorter and broader. Otherwise they resemble the arteries. In sections, they are easily differentiated from the other blood-vessels in having a very much greater diameter. They are non-collapsible in the pulp, have no valves, and retain the rounded outlines of their walls. This is doubtless due to their strong support by means of the stroma which permeates the pulp tissue.

The walls of the *Capillaries* are exceedingly delicate, being formed by a single layer of endothelium, which is a continuation of the endothelial lining of the arteries, on the one side, and the veins on the other. The smallest capillary walls may consist of only two or three of such cells, which, in this case, are curved to form the interior of the tube. The nuclei are marked and the karyoplasm pronounced (see Fig. 106).

There are no traces of any organized lymphatic system in the dental pulp. That is to say, evidences of the existence of endothelially-lined lymphatic capillaries or vessels are wanting. Pericellular and intercellular lymph spaces or tissue spaces are everywhere apparent, as also are those around the blood-vessels and nerve bundles. The pulp is saturated with lymph which is derived from the blood plasma, as an exudation from the capillaries. It permeates the pulp tissue and exudes into the dental tubules around the odontoblast processes. It, however, does not pass into lymphatic vessels, and does not leave the pulp by any such channels. Yet Schweitzer, in an elaborate article (*Arch. f. mikr. Anat.*, 1907) claims that, by careful injection, he has succeeded in demonstrating tufts of lymphatic capillaries in the coronal portion of the pulp, which collecting the lymph of that neighbourhood, conveys their contents into one or two wide lymphatic vessels which issue from the apical foramina of the teeth in company with the blood-vessels. The dental pulp is one of those few parts of the body which is devoid of any lymphatic system.

D

The Nervous System

As eliciting the closest attention on the part of many thinkers and writers, as presenting a truly fascinating and profoundly interesting field of speculation, as affording ample opportunities for most brilliant work in original research, the study of the nervous system of the dental pulp may claim to be, of all dental histological subjects, of the first importance, instruction, and

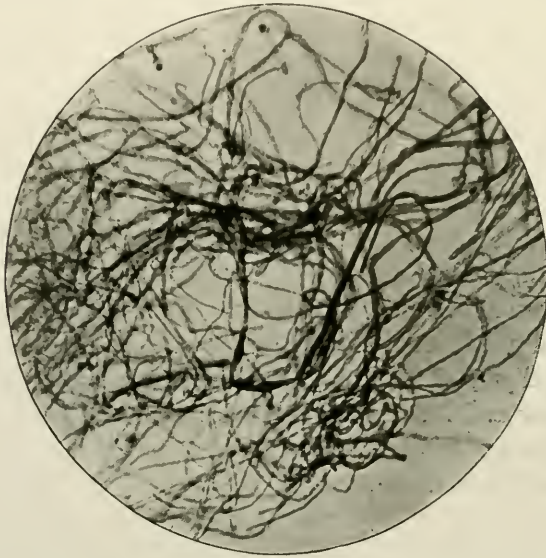


FIG. 109.—The plexus of Raschkow, teased out, and stained with chloride of gold. Magnified 250 times.

value. One is completely astonished at the mass of literature, old and new, which has been devoted to it. Its bibliography is manifold, and in itself would furnish, if gathered in one volume, most illuminating reading. Yet in spite of the earnest labours of one half-a-century, it is amazing to recall the fact that while so much is known about it, so much is still unknown—the actual methods of the peripheral distribution of the myelinic (medulated) nerves being buried in obscurity. True, that some of the earlier histologists solved most carefully *in suo modo* this particular and difficult problem; true, that modern

methods of preparing the hard and soft tissues for microscopical examination have shed new light on it; it still remains to be noted that the anatomical data and physiological principles involved in the phenomena which give rise to pain in the teeth—the whole innervation of the pulp—the direct

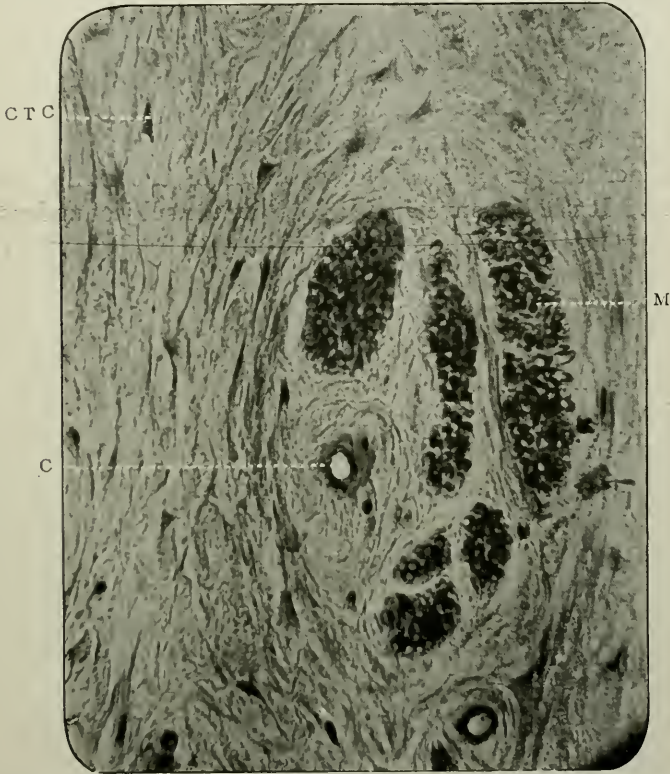


FIG. 110.—Similar to Fig. 106. To show six nerve bundles cut transversely. Prepared by the Author's process. Stained with rubine. Magnified 750 times. c.t.c. Connective tissue fibres and cells; c. Capillary; m. One of the nerve bundles.

course by which sensation is conducted from the dentine or enamel to the cortical areas of the cerebral hemispheres cannot be considered satisfactorily determined. But its capability of solution is unquestionable.

Here an attempt will be made to describe the chief recognised facts, and some arguments in this nebulous matter. The nervous system of the dental pulp consists of the peripheral pro-

longations and terminations of certain cerebro-spinal ganglionic neurones emanating from the upper and lower sensory nuclei in the medulla and fourth ventricle, and passing through to the Gasserian ganglion. They are cellulipetal, and while constituting the peripheral axones of receptive afferent neurones, they are essentially the distal telodendria of the peripheral sensory neurones. They terminate structurally like the telodendria of the other ordinary sensory nerves, and probably arborize about the odontoblasts on the surface of the pulp and do not penetrate the dentinal tubules. The blood-vessels of the pulp are under the trophic control of fibres of the sympathetic system. It will be convenient to consider the subject under the following headings: The myelinic nerves, their (i) method of distribution, (ii) structure, and (iii) terminations in (a) fishes, (b) reptiles, (c) mammals.

(i) *Method of Distribution*.—Emerging from the “indifferent tissue” of the periodontal membrane, in company with the main arterial trunks, and entering the apical foramina of the teeth, the bundles of myelinic and sympathetic nerve fibres pass collectively into the pulp, in lines directly corresponding to its long axis. There are thus several *funiculi* colligated into sheaves; and without undergoing much appreciable diminution in numbers, they extend into the soft tissue, and maintain a more or less parallel direction with the outlines of the dentinal walls. The nervous trunks pass, like long, straight or very slightly wavy lines, in this way, for some considerable distance, and then begin gradually, as they approach the parieties of the pulp, to break up into smaller fasciculi; until, when close to the basal layer of Weil, the original bundles are represented only by two or more nerve fibres running side by side. In many instances, the bundles stretch up to the sub-odontoblast region, and then, according to Röse and Gysi (“Portfolio of Microphotographs of Dental Histology,” 1895) very suddenly burst forth in myriads of minute scopiform strands. The result is the formation of an interlacing of fibres—the plexus of Raschkow (see Fig. 109).

In every case the chief nerve fasciculi run alongside the larger blood-vessels, and in their areas of distribution follow them closely, and, in the case of the sympathetic fibres, penetrate their external coats.

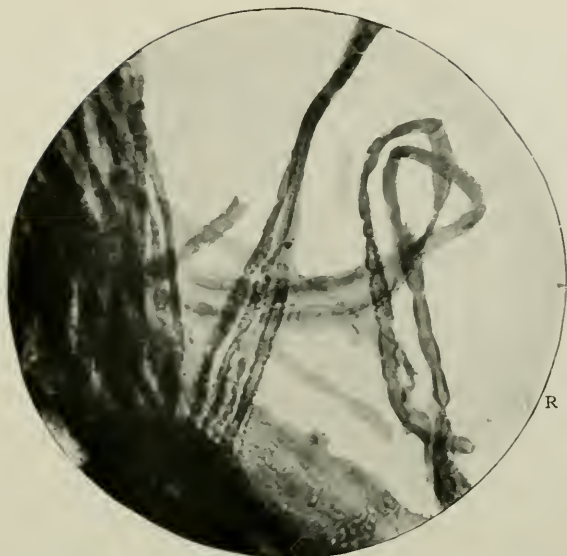


FIG. 111.—Myelinic nerve fibres, teased out. Stained with osmic acid. Magnified 850 times. R. A node of Ranvier.

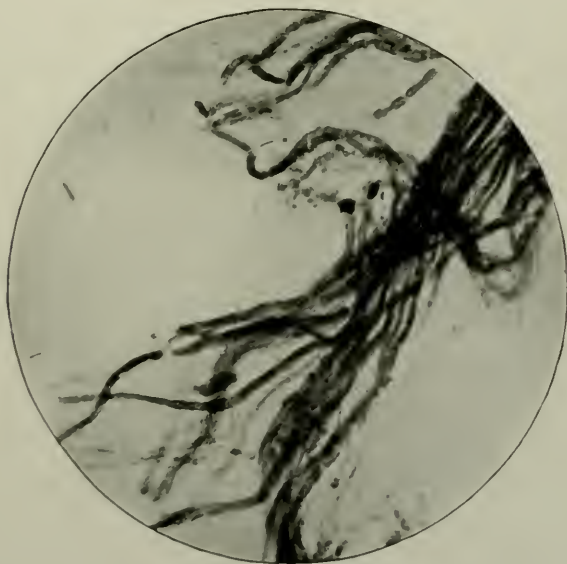


FIG. 112.—Similar to the preceding. Magnified 800 times.

Towards their distal arborisations they become in places lobulated or varicose, a condition which, according to Schäfer,¹ is occasioned by pressure or traction on them, causing the soft matter "to accumulate at certain points, whilst it is drawn out and attenuated at others." In addition to these occasional dilatations, and near their peripheral distribution they divide into branches—each component part participating in the division. By oft-repeated sub-division the fibres become much smaller.

(ii) In *structure*, the myelinic or white nerve fibres correspond with those found elsewhere in the cerebro-spinal system of man, except in one particular, and that is with regard to size. The individual fibres in the pulp vary from 1.5μ to 3μ in diameter. Kölliker has measured them. His figures are: In diameter, the large trunks in the radicular part of the pulp, are 62μ to 8μ ; their constituent elements 3μ to 6μ ; and their primitive fibres 2.5μ to 3.4μ .

Each consists of (α) the axis-cylinder of Purkinje; (β) the medullated sheath of Schwann; and (γ) the primitive sheath or neurilemma.

(α) The axial fibre, or *axis-cylinder process*, or more shortly the *axone*, extends without interruption through the whole length of the nerve fibre, from its origin in the cell body in the cerebrum to its ultimate ramifications near the *membrana eboris*. It is to-day an almost certain fact that the axone is always a direct prolongation of a branch of a nerve cell, extending far away from its origin, but yet in perfect continuity with it. Max Schultze in 1837² observed that the axone consists not of a single cord or thread, but is a complex structure made up of many fibrils ("primitive fibrillæ") imbedded in fine granular material. Obersteiner told Gowers³ that he had counted as many as fifty such primitive fibrils in a single axone, each fibril having a separate and distinct path of conduction.

¹ "Quain's Anatomy," Vol. II., part I., 1912.

² Vide Stricker's "Histology."

³ "The neurone and its relation to disease." *British Med. Journal*, Nov. 6th, 1897.

(β) *The myelin sheath*, or white substance of Schwann, is easily identified in sections of the pulp when stained with osmic acid, the action of which is to render the fatty matter (which contains lecithin) of the myelin a dark grey or black colour.

The medulla is continuous, but presents here and there breaks in its continuity. These constrictions are known as the nodes of Ranvier. Occurring at nearly equal intervals, they divide the fibre into internodes. The white substance has undergone a certain amount of shrinkage at a node, and is quite transparent, but in addition there is present a finely granular stroma rendered evident through refraction by the fatty matters which are usually found in it (Fig. 111).

The nodes of Ranvier, when treated with various stains, exhibit other markings. In this way, a weak solution of silver nitrate reveals the crosses of Ranvier—in which the cement joining two internodes, and a small portion of the axone are affected, and also sometimes Fromman's lines—a cross-striation of the axone at the node; and a 1 per cent. solution of osmic acid, minute nodes on the primitive fibrils of the axone with the black constricting ring of Ranvier placed outside (van Gedoelst).

Further sub-divisions in the medullary sheath are found in the form of oblique slits passing outwards from the axone to the neurilemma. These are called "incisures," and are rendered apparent by the use of osmic acid and picro-carmin. They split up the internodal myelin into a series of short lengths or "cylinder cones," the bevelled end of one cone fitting accurately into the opposite similar end of the neighbouring cone.

In addition to these various histological structures in the myelinic sheath of nerves, there exist also, when suitably stained, radial virgate striations, as well as a more-or-less-coarse reticulum.

(γ) *The primitive sheath or neurilemma* forms the external covering of white nerve fibres. It is an exceedingly delicate homogeneous membrane which passes over every node of Ranvier, and possesses in the mid-distance of an internode a large flat nucleus. At a node, the neurilemma is probably

discontinuous with the axone, because of the intervention of the annular constricting band of Ranvier.

A horizontal section of the pulp stained carefully with osmic acid or hæmatoxyline or other stains displays the nerve bundles cut across. Collectively examined they show the endoneurium—fine connective tissue septa passing in between the individual nerve fibres, as processes of the perineurium which surrounds the fasciculus itself. Several fasciculi are invested by the epineurium. These coverings—endoneurium, perineurium, and epineurium—are continued to the ultimate terminations. In the finest branches they are reduced to a mere connective tissue sheath, the sheath of Henle.

The sympathetic nerve fibres—fibres of Remak—are the axones of neurones belonging to the sympathetic system, being distributed to the blood-vessels as vaso-dilators or vaso-constrictors. They are amyelinic, measure 1μ to 2μ in diameter, consist of axone and neurilemma, and terminate as telodendria composed of naked axones.

(iv) *Peripheral Terminations of the Nerves*

In order to pave the way to some knowledge of the anatomical distribution of the free extremities of the nerve fibres in the dental pulps of man, it will be expedient and instructive to note how the nerves end in the pulps of the teeth of fishes, reptiles, etc.

(α) *In Pisces*

Here the evidences as to the exact mode of the terminal arborization of the sensory nerve fibres are quite clear, thanks to the splendid labours of Gustav Retzius.¹ By Golgi's method of staining, he succeeded in positively demonstrating in the teeth of *Gobius* and *Gasterosteus*, anatomical conditions which agree in all essential points. Definite types of nerve-branching were observed.

¹ "Biologische Untersuchungen," Neue Folge, iv., v. and vi., 1892, 1893, and 1894.

The amyelinic nerve fibres arising from a dense plexus in the soft tissues in which the teeth are situated, pass into the pulp and spread out thickly to form free endings in that tissue, extending upwards towards the coronal region, and abundantly giving off lateral branches with free terminations. The extreme cornu of the pulp is not supplied with nerves. (For illustrations of this condition see Figs. 113 and 114.)

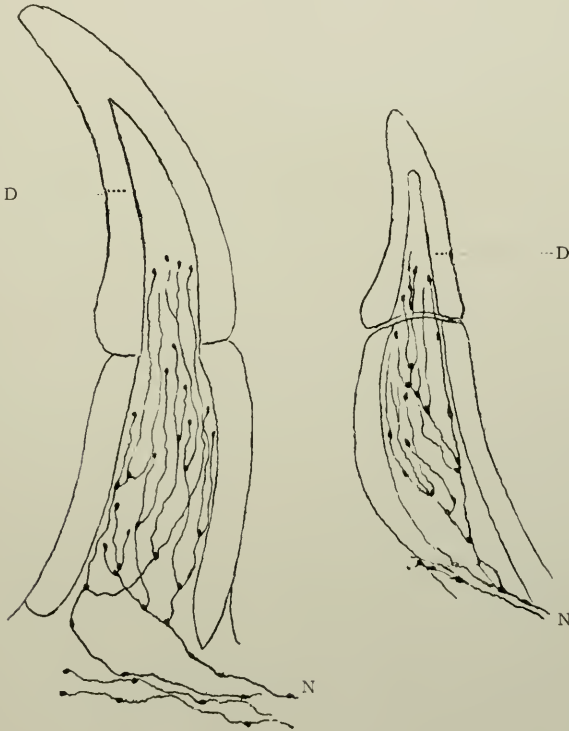


FIG. 113.

FIG. 114.

FIGS. 113 and 114.—Longitudinal sections of the teeth of *Gobius*. Golgi's stain. D. Dentine; N. Nerve fibres, ending in free terminations, close under the dentine. (After Retzius.)

(β) In Reptilia

Retzius was able here, to trace the nerves quite easily, still using Golgi's method. In *Lacerta agilis* he describes them as rising, in the first place, from the middle of the pulp. He writes (pp. 65 and 66, Vol. iv). "In the pulp may be seen the con-

nective tissue which also contains blood-vessels, a black thread apparently consisting of nerve fibres matted or closely pressed together. This thread rises upwards, and gradually gives off

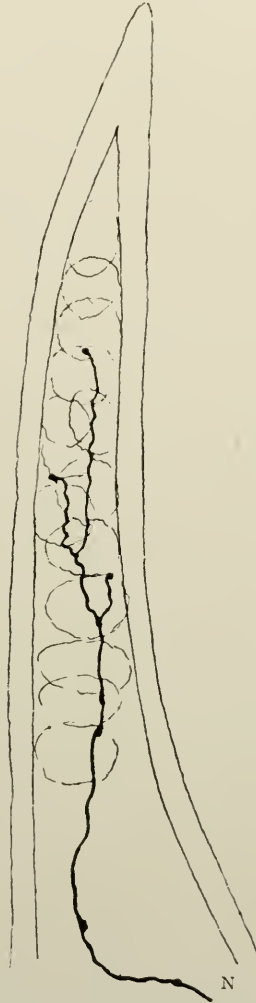


FIG. 115.—Longitudinal section of tooth of a larva of the *Salamander maculata*. Golgi's stain. N. Nerve fibre. (After Retzius.)

branches which extend partly towards the side, and partly upwards. These enter the odontoblast layer, and pass between the cells, as a rule, to the upper surface of the pulp, there to end

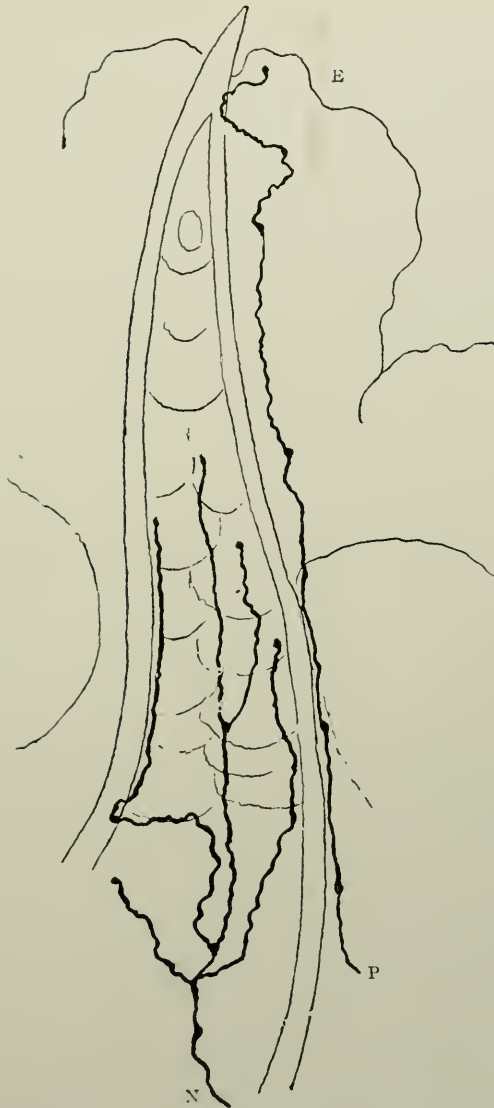

FIG. 116.—Tooth of larva of *Salamander maculata* with the surrounding oral mucous membrane. Golgi's stain. N. Amyelinic nerve fibre, branching and ending free in the pulp; P. Nerve fibre in the circumdental tissues, ending free in E. the surface epithelium. (After Retzius.)

directly under the dentine in free extremities, which here and there are swollen into knots. In transverse section these fibres penetrate the odontoblast layer, and reach the inner surface of the dentine, there to end free after a short ramification. The penetration of nerve fibres into the dentine was nowhere observed."

The larvæ of *Salamander Maculata* and *Triton Cristatus* provided suitable material for further tracing the amyelinic nerve fibres. In these preparations, after their entrance into the pulp, the nerves divide dichotomously, and, branching upwards, end partly in the side of the pulp tissue, and partly close under the surface of dentine. The fine varicose branchlets rise about half-way up the tooth, but never pass to the upper end of the pulp (p. 41, Vol. v.). "All branches end freely, spreading out in different parts of the pulp. Most of them apparently end close under the dentine or near its inner surface, but never penetrate into its substance or into its canals."

(γ) *In Mammalia*

The precise method by which the sensory nerves finally terminate in the pulp of the teeth of man, constitutes one of those histological puzzles which yet remain unsolved; and even to-day, it is absolutely impossible to give a clear and proved solution. As has already been hinted, the subject is too vast to do more than mention the chief modern theories connected with it.

1. In the teeth of *young mice*, Retzius in 1894 (*op. cit.* Vol. vi., p. 64) succeeded in staining the nerve fibres, not only everywhere in the pulp, from the beginning, near the blood-vessels, but also in tracing their branches into the odontoblast zone, and between these cells to the under surface of the dentine. "In vertical sections the fibres, like a string of tiny beads, stretch between the odontoblasts to the surface and there end free." They often bend round on reaching the surface, and run a little way tangentially. In a tangential section they can be partially traced under the dentine."

2. Franz Boll,¹ over fifty years ago, observed fine fibres (which he thought were nerves), by means of $\frac{1}{32}$ per cent. solution of chromic acid, in the pulps of *rabbits* and *guinea-pigs*.

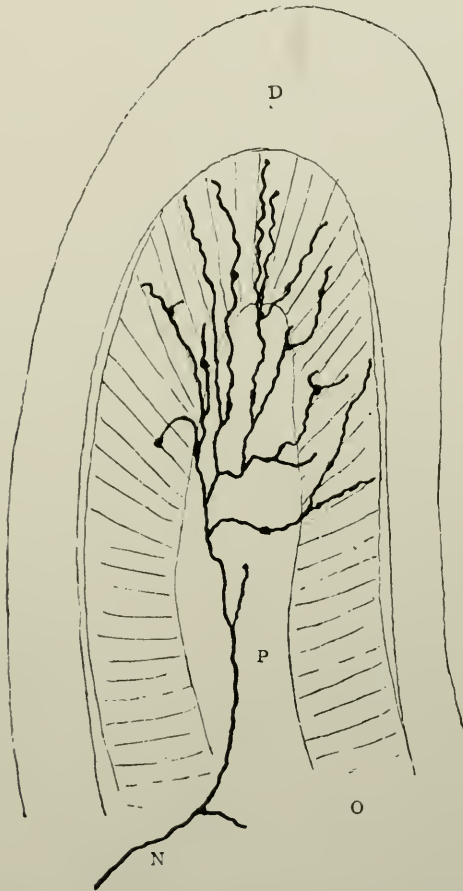


FIG. 117.—A vertical section through the tooth of *Lacerta agilis*. Golgi's stain. D. Dentine; O. Odontoblasts; P. Pulp with blood-vessels and N. Nerves which branch, penetrate between the odontoblasts, continue their ramifications to the upper surface near the dentine, and there terminate. (After Retzius.)

He used the persistently growing teeth. He traced them to places between the odontoblasts, and even between the dentinal processes of the odontoblasts which had been detached from the

¹ "Untersuchungen über der Zahnpulpa." *Archiv. für Mikroskop. Anatomie*, Vol. iv., p. 73, 1868.

dentine. Thus he believed that the nerve fibres extend into the dentinal tubules. The nature of the fibres first described by Boll was most uncertain, and did not present the gemmules or

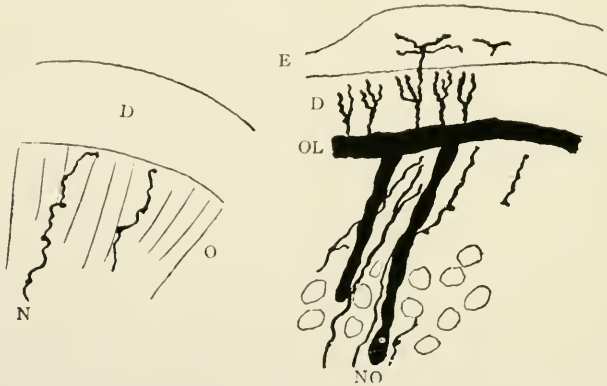


FIG. 118.

FIG. 119.

FIG. 118.—Transverse section of tooth of *Lacerta agilis*. Golgi's stain. D. Dentine; o. Odontoblast layer; N. Nerve fibre which passes free to the upper surface of the odontoblast layer and there terminates. (After Retzius.)

FIG. 119.—Vertical section of the upper part of a young tooth of a mouse five days after birth. Golgi's stain. E. Enamel with the ends of the dentinal tubes projecting into it; D. Dentine with stained dentinal tubes; o.l. Odontogenic zone; o. Odontoblast; N. Amyelinic nerve fibre passing between the odontoblasts. (After Retzius.)

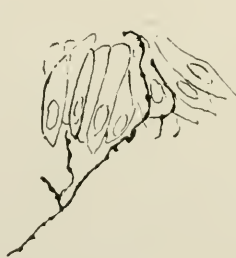

FIG. 120.

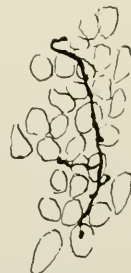


FIG. 121.

FIG. 120.—Vertical aspect of odontoblasts having between them two ultimate branches of a fine varicose nerve fibre. From the pulp of a molar tooth of a rabbit. Prepared by staining with methylene blue fixing in ammonium molybdate and mounting in balsam. (After Huber.)

FIG. 121.—Similar to the preceding figure. Odontoblasts seen end on. The nerve termination lies over the cells. (After Huber.)

beads which Golgi's and methylene-blue methods of staining depict upon the axones.

3. Carl Huber,¹ of the University of Michigan, made use

¹ "The Innervation of the Tooth-pulp." *The Dental Cosmos*, vol. xl., pp. 803 et seq., 1898.

of the mandibular canines and molars of *dogs*, *cats*, and *rabbits*. His most satisfactory results were obtained from the pulps of rabbits' molars. The method of staining he employed was 1 per cent. methylene blue in physiological salt solution injected into the common carotid during life. He describes the follow-



FIG. 122.—Amyelinic terminations of the nerves in the dental pulp of a dog. Stained with methylene blue. (After Huber.)

ing interesting histological revelations:—"The medullated, *i.e.*, myelinic, nerve fibres approach the lower portion of the pulp in one or several relatively large nerve bundles. On reaching the lower surface of the pulps, these larger bundles break up into numerous smaller ones, the latter consisting of eight to ten nerve fibres, although larger ones are frequently met

with. In the fibrous tissue membrane which covers the under surface of the pulp, and which is continuous with the periodontal membrane, these smaller nerve bundles form, as the result of frequent anastomoses, a plexus of medullated fibres. . . The smaller bundles of medullated nerves, coming off from the plexus, pass nearly perpendicularly up into the pulp, into which they may be traced as small bundles of medullated nerves, two to eight or ten in number, to all levels of the pulps, some to the very tip. . . . On approaching the surface of the pulp, the medullated fibres lose their medullary sheath: the non-medullated (*i.e.*, amyelinic) terminal branches, after repeated division, form a plexus immediately under the odontoblasts. They branch and re-branch into long, delicate varicose fibres." This plexus is that of Boll, and Raschkow, and others, but according to Huber, it is "a plexus only in so far that the varicose fibrils cross each other in various directions."

Huber's observations on the ultimate termination of the nerves corroborate those of Retzius. The fibrils given off from the plexus just mentioned as being present beneath the odontoblasts, pass up between these cells, and end, as fine beads, usually near the free or dentinal end of the odontoblasts. Sometimes they run tangentially. Huber says that they do not, in his opinion, make any connection with the odontoblasts, nor with any of the cellular elements of the pulp: and he scouts the idea of their entrance into the dentine.

4. Legros and E. Magitot¹ examined the dental pulps of the *calf, dog and cat*, and concluded that the terminal filaments are continuous with ramified cells, situated immediately below the odontoblasts, with which they are in immediate communication. "There is thus," according to these authors, "a direct chain of sensation transmitted from the nerve-ending to the dentinal fibril *viâ* the branched cells, and the basal processes of the odontoblasts, the bodies of these latter and finally their peripheral poles" (Fig. 127.)

The most careful search for such cells in the pulps of *Herbivora* and *Carnivora* (including man) has been attended only by negative results.

¹"Morphologie des follicle dentaire chez les Mammiferes." *Journal de l'Anatomie et Physiologie*, 1879.

5. Oscar Römer,¹ after a great deal of labour and experiment, and following on the lines suggested by Morgenstern, used the teeth of three-weeks-old *kittens*, and adopted the intra-vitam methylene-blue stain. He enunciated the following, *inter alia*:—

- (i) The nerves of the pulp penetrate, as non-medullated filaments, the spaces which intervene between the odontoblasts, reach the zone between these cells and the dentine, and here pass into the interior of the odontoblast processes, that is to say, in Kölliker's dentinal tubules.

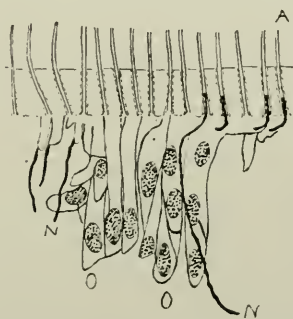


FIG. 123.—Diagram of a section through the tooth-germ of a kitten, three weeks after birth. Prepared by the intra-vitam method of staining with methylene blue; fixing in ammonium molybdate, formalin, and subchloride of platinum; decalcifying in acetic acid, and embedding in celloidin. Shows Römer's conception of the passing of the amyelinic nerve fibres into the dentinal tubules. A, Dentinal tubes; O, Odontoblasts; N, Fine nerve fibrils going upwards out of the pulp, between the odontoblasts to the dentinal tubules in the dento-genetic zone. (After Römer.)

- (ii) The chief mass of the nerve filaments radiate out of the cornua of the pulp into the dentine; while the other zones of the dentine of the crown appear to be poorer in nerve branches, and the dentine of the root entirely nerve-less.
- (iii) A greater part of the dentinal tubules widen out at the enamel-dentine boundary, into curious partly spindle-shaped, partly club-shaped formations which are chiefly arranged in very great numbers around the apices of the dentinal cusps, and in which, in well-preserved sections, small roundish or larger oval corpuscles are perceptible,

¹ *Loc. cit.*

which are often arranged in rosary-like rows, and, with gold chloride, take an intense stain; and

- (iv) The small corpuscles in the interior of the spindle-shaped enlargements of the dentinal tubes may be regarded, with great probability, as terminal corpuscles of sensitive nerves in the dentine, analogous to the terminal corpuscles of the sensory nerves of the skin and the papillæ of mucous membranes.

This writer, out of forty-seven drawings in his monograph gives, however, only two figures depicting the passage of nerves into the dentinal tubules. One is magnified 250 times, and the other an amplification of the first, 750 times (*vide* Tafel iv., Figs. 16 and 17). In spite of their measurements, (0.25 μ to 0.3 μ), of his indefatigable zeal, his earnestness and his precautions, the author is unable to agree with the interpretation placed upon the appearances presented by the sections, and must distrust the drawings accompanying the text. Moreover this writer, considering the processes of the odontoblasts as hollow, describes sensory nerve fibres as piercing or *passing into the interiors of these cells*. This is entirely erroneous, for nowhere in the body do nerve fibres penetrate the walls and mingle with the cytoplasm of cells! Similarly the work of Dependorf (*Deutsch. Monatss. f. Zahn*, 1913) can be at once discounted, for he describes and illustrates nerve fibres in the basis substance of the dentine!

6. Aitchison Robertson (*op. cit.* p. 823) in the pulps of the *ox*, when treated with 0.6 per cent. solution of potassium anhydrochromate for twenty-four hours, found long central processes to the odontoblasts, which he believed became continuous with the nerve-fibrils. He says (p. 324), "The long central process seems to become the axis-cylinder of a nerve fibre which gradually acquires a primitive sheath, in which the medullary or white substance slowly accumulates till an ordinary medullated nerve results." His drawings, reproduced in Figs. 104 and 105, unfortunately convey nothing to the enquiring mind, and certainly if they are correct, his assumption is still unproved.

7. Kölliker in 1860 (*op. cit.* p. 300) in the teeth of *man*,

observed that the primitive fibres, which are given off from a rich plexus, "form very evident loops," but he did not consider them the ultimate terminations.

8. In specimens of full-term fœtuses, presumably *Human*, Bödecker¹ using gold chloride, positively asserts "that an

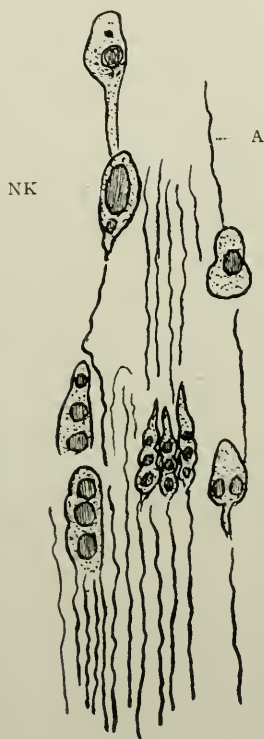

FIG. 124.

FIG. 124.—Longitudinal section of the dentine of a young Human tooth. Stained with osmic acid. A. Axon; N.K. Nerve corpuscle. (After Morgenstern.)

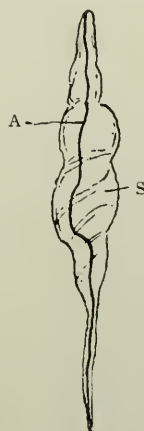

FIG. 125.

FIG. 125.—Nerve ending in enamel of a young tooth. s. Nerve corpuscle; A. Axon. (After Morgenstern.)

indirect connection of the two" (dentinal fibrils and nerve endings) "is established by the intervening reticulum of living matter."

It must not be forgotten, however, that this author believes that the dentinal fibrils arise *between* the odontoblasts, whose

¹ "The Anatomy and Pathology of the Teeth," 1894.

rôle it is to furnish the basis-substance of the dentine. But this, as well as many other matters of which Bödecker has written, must be accepted with the greatest caution. His views are so heterodox, and do not conform in any degree with the accepted hypotheses and observations of a great number of reputed histologists of various nationalities.

9. Morgenstern¹ describes in the teeth of *man*, bundles of axones surrounded by their medullary sheaths passing into the dentine or enamel. In the former tissue they traverse tubules, some of which are smaller and others larger than the ordinary tubules. Each canal has in it two axones and they terminate either (i) at the cortex of the dentine, or (ii) at the amelo-dental junction, or (iii) even pass into the enamel. In the first-named locality they end in knob-shaped structures which may be ellipsoid or pyriform in shape (Fig. 124). In enamel they may end variously, as in the dentine, in elongated nucleated structures where the axone (α) passes through the entire so-called nerve corpuscle to end at its periphery (Fig. 125), (β) terminate on a nucleus of the said nerve corpuscle, or (γ) traversing the entire nerve corpuscle, may wind itself round one or many nuclei, and end on the last or furthest-most nucleus.

His chief argument lies in the fact of the black colouration found in Golgi-stained preparations, and he has adduced no proof that what he has described as nerves *are* nerves. Thus he writes (page 383 *op. cit.*) "The nerves which appear in the dentine when treated by the silver method, show black filaments of very varied length and thickness. Their intense black colour, and different peculiarities—characteristic of nerves—leave no doubt of the identity of these fibres with nerve filaments. In regard to the wealth or number of nerves, probably no one part of the tooth is materially distinguished from another. There is, however, probably a distinction in regard to the mode of their division and termination. It is the dental canaliculi which for the most part contain the longer nerve

¹"Über das Vorkommen von Nerven in der härtern Zahnsstoffen." *Deutsche Monat. für Zahnheilkunde*, p. 436, 1892; also *Deutsche Monat. für Zahnheilkunde*, p. 111, 1895.

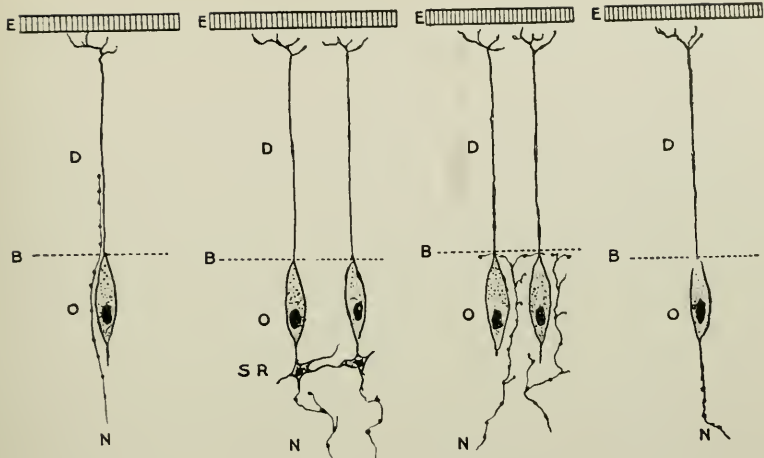


FIG. 126.

FIG. 127.

FIG. 128.

FIG. 129.

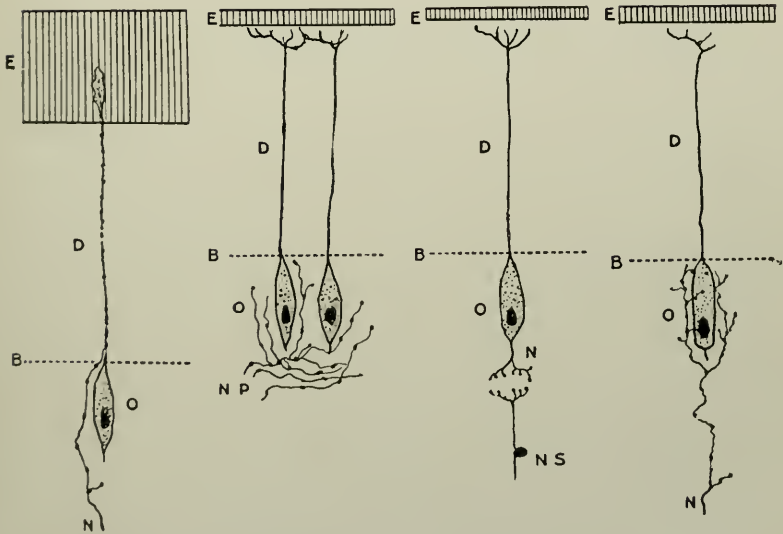


FIG. 130.

FIG. 131.

FIG. 132.

FIG. 133.

FIGS. 126 to 133.—To show in a diagrammatic manner the various conceptions as to the method of termination of the amyelinic nerve fibres in the pulp. Fig. 126, according to Boll; Fig. 127, according to Magitot; Fig. 128, according to Retzius; Fig. 129, according to Aitchison Robertson; Fig. 130, according to Römer; Fig. 131, according to Huber; Fig. 132, according to Pont; and Fig. 133, according to the author. e. Enamel; d. Dentine; b. Limit of pulp tissue; o. Odontoblast; n. Amyelinic nerve fibre termination; n.s. Neuron in spinal cord; s.r. Stellate cells connected with the odontoblasts; n.p. Nerve plexus of amyelinic fibrils.

filaments: there occur, however, many more nerve filaments than are in the dentinal canaliculi proper, which run between these, and in the same direction, in approximately the same direction, and in quite a different direction. The same direction as that of the dentinal canaliculi is observed chiefly in the crown portion of the teeth, it is therefore more difficult to distinguish nerves there from other fibril constituents than it is, for instance, in the root portions."

Inasmuch as this writer supposed that myelinic fibres entered the dentine in *special tubes*, and as these tubes are non-existent, his observations carry no weight whatever.

10. Schäfer¹ accepts Howard Mummery's conclusions but does not base his belief entirely on the microscopical appearances, but on *clinical grounds* also. But the sensitiveness of dentine can be explained in other ways than upon its supposed innervation.

11. Howard Mummery² has devoted much patient labour to the elucidation of the nerve terminations. His conclusions may be summarised in his own words, as follow:

(α). That, in actively growing teeth, there is a considerable supply of non-medullated or efferent fibres to the tooth pulp, which are derived from sympathetic ganglia and not concerned in any way with the sensitiveness of the dentine, their ultimate fibrils probably being distributed to the coats of the blood-vessels and the secreting cells of the pulp; whether any fibres of this system enter the dentinal tubes it seems impossible to determine;

(β). That at the cornua of the tooth pulp, the bundles of medullated nerve fibers lose their medullary sheath and neurilemma, and the axis cylinder expands into a spreading mass of neurofibrils, which can be traced directly to the dentinal tubes, which they enter;

(γ). That in young, growing teeth, these fibres at the cornua are very abundant, and have a wavy course; they appear to

¹ "Essentials of Histology," 1916.

² "On the Distribution of the Nerves of the Dental Pulp," *Philos. Trans. Roy. Society*, 1912; "The Nerve Supply of the Dentine," *Proc. Roy. Soc. Medicine*, 1912; "The Innervation of Dentine," *Dental Cosmos*, March, 1916, etc.

consist of bundles of neurofibrils in many instances, and these vary much in diameter, the further divisions of these bundles probably taking place in the tubes of the dentine;

(δ). That at the lateral portions of the pulp, the neurofibrils passing from the main nerve trunks enter into an intricate plexus beneath the odontoblasts, and are again collected into larger strands of neurofibrils, which mostly pass directly into

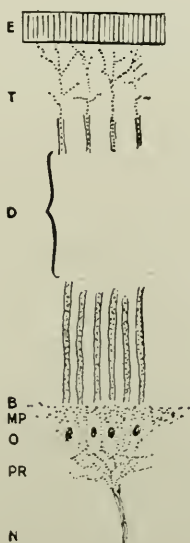


FIG. 134.—Diagram to show the method of termination of the amyelinic nerve fibres of the pulp in the dentine according to Howard Mummery. E. Enamel; D. Dentine; B. Limit of pulp tissue; O. Odontoblast; N. Amyelinic nerve; P.R. Plexus of Raschkow; M.P. Marginal plexus; T. Terminations in dentinal tubes beneath enamel.

the dentinal tubes. They (the preparations) also demonstrate the different appearances of these strands of fibrils, some being large and showing bead-like enlargements at intervals, other finer fibres having a minutely dotted appearance;

(ϵ). That where the pulp is separated from the dentine, the nerve fibres seem to be pulled out from the pulp and from the dentinal tubes, and stretch across the interval, evidently under considerable tension;

(ζ). That the nerve fibres enter the dentinal tubes in company with the dentinal fibril.

12. M. Pont in a contribution to the *Trans. of the IIIrd. International Dental Congress, Paris, 1900*, on "La cataphorèse en art dentaire et plus spécialement dans le cas de dentine

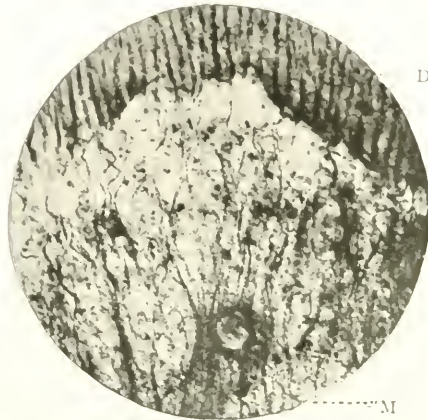

FIG. 135.—The cornu of the pulp of a fully formed human premolar. M. Myelinic nerve bundle dividing, inclosing the transverse section of blood-vessel; D. Dentine. Neurofibrils entering the tubules. Prepared and photographed by J. Howard Mummery.

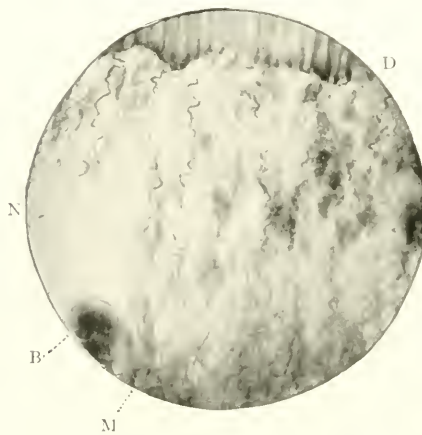


FIG. 136.—The cornu of pulp of erupting human premolar. M. Myelinic nerve bundles dividing; N. Neurofibrils; D. Dentine; B. Blood-vessel. Prepared and photographed by J. Howard Mummery.

hypersensible" says: "La description des odontoblastes rapelle absolument celle des neurones sensoriels périphériques, et nous croyons que les odontoblasts sont des cellules nerveuses

dont les prolongements périphériques constituent la voie centripète et les prolongements pulpaire la voie centrifuge." ("Odontoblasts resemble peripheral sensory neurones, and we believe that they are cells of the nervous system, whose dental processes constitute the centripetal poles and basal processes the centrifugal poles.")

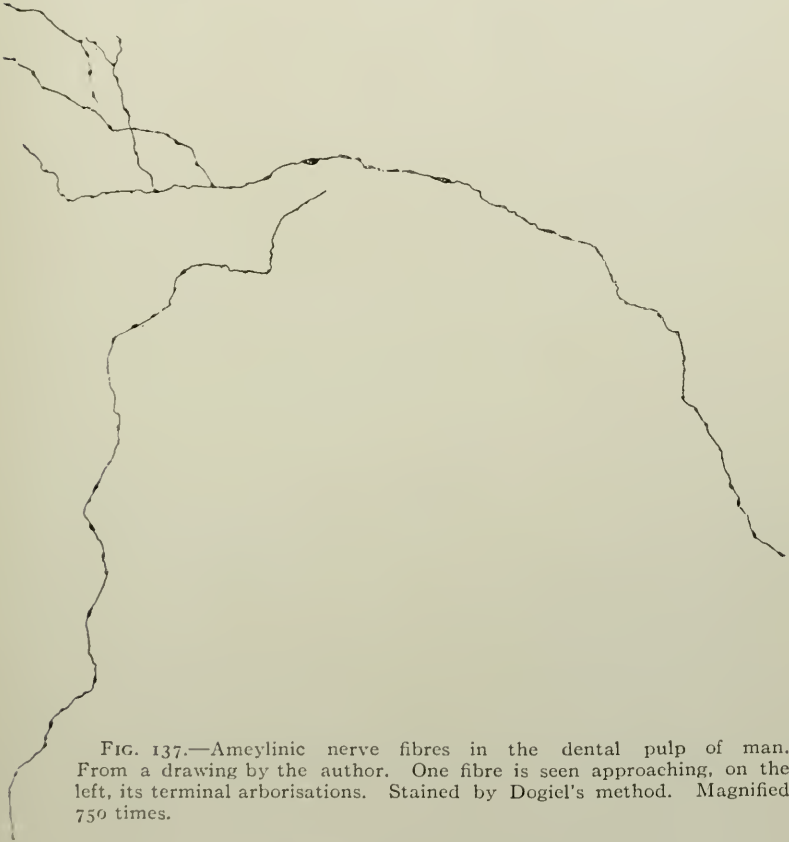


FIG. 137.—Amyelinic nerve fibres in the dental pulp of man. From a drawing by the author. One fibre is seen approaching, on the left, its terminal arborisations. Stained by Dogiel's method. Magnified 750 times.

13. For many years, the present author has endeavoured to demonstrate the ultimate ramification of these nerves. His then views were set forth at some length in the *Trans. Odonto. Soc. of Gl. Britain*, November, 1893. Some of the arguments are reproduced in the Appendix. Since that communication appeared, he has not confined his investigations to the pulps

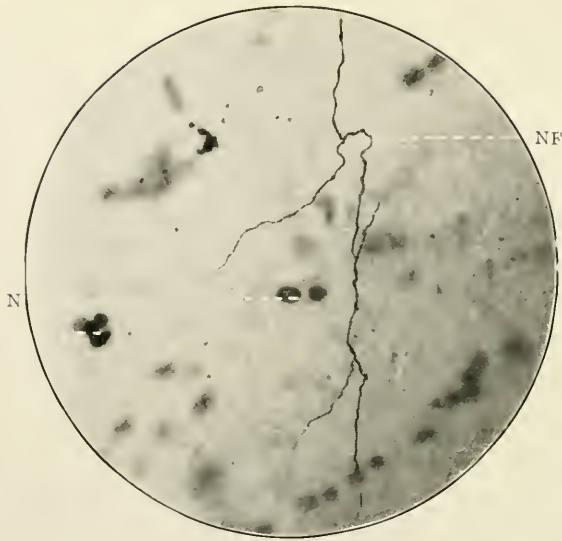


FIG. 138.—Amyelinic nerve fibre in the dental pulp of man. Stained by Dogiel's method. Magnified 750 times. N.F. Nerve fibre bifurcating into two terminal branches; N. Nucleus of pulp cell. Photomicrograph by Douglas Gabell.

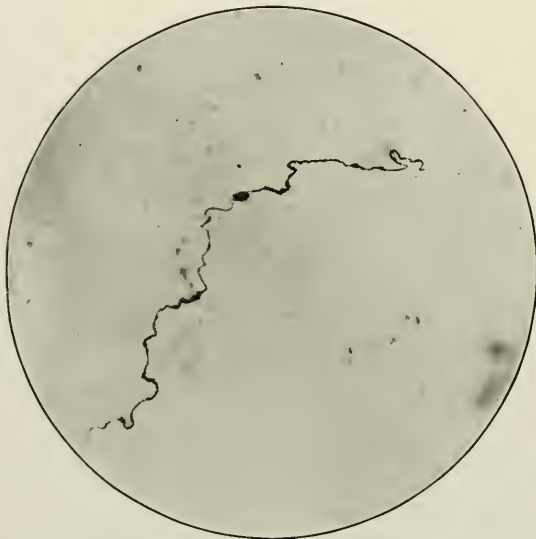


FIG. 139.—Similar to Fig. 138. The beaded appearance is well shown. Photomicrograph by Douglas Gabell.



FIG. 140.—Longitudinal section of the pulp of a human incisor tooth. Stained by Ford Robertson's modification of Heller's stain. Magnified 40 times. Shows the general arrangement of the myelinic nerve bundles. (From a section prepared by the late Storer Bennett.)

of the teeth of man alone, and has obtained abundant evidences in other vertebrates of the presence of amyelinic fibres at the periphery of the pulp. The photomicrograph Fig. 109 represents a teased preparation of the myelinic fibres, which go to form a component part of the plexus of Raschkow. It was made thus:—A recent tooth, unaffected in any way by




FIG. 141.—The same as the preceding. Magnified 250 times.

morbid influences, on being carefully split in the jaws of a vise, is found to have covering the inner surface of the dentine a moist, colourless, almost invisible film. Removal of this and staining with suitable reagents revealed a tangled mass of myelinic nerve fibres. The staining reagents used were not especially appropriate for amyelinic fibres. In other parts of the tissue numerous nerves of the latter class could be readily stained by using a $\frac{1}{16}$ per cent. physiological solution of methylene blue, "fixing" in picrate of ammonia, and mounting in glycerine.

As the result of his researches, the author has the strong conviction that these fibres terminate in a basket-work of varicose fibres embracing and often closely attached to the cell walls of the individual odontoblasts. The sensory currents are traced, in this way, from the amelo-dentinal junction through the dentinal fibrils, odontoblasts, arborisations of amyelinic telodendria to the myelinic nerve fibres of the pulp.

CHAPTER VIII

THE ALVEOLO-DENTAL PERIOSTEUM

MICROSCOPICAL ELEMENTS:—(i) “Principal” fibres; (ii) Connective tissue fibres; (iii) Blood-vessels; (iv) Nerves; (v) Epithelial masses; (vi) Osteoblasts; (vii) Osteoclasts; (viii) Sharpey’s fibres; (ix) Calcospherite spherules.

GENERAL CHARACTERISTICS

Definition.—The thin connective tissue with extensive vascular and nervous systems which intervenes between the external surface of the cementum of teeth and the *lamina dura* of the bone of their alveolar sockets. Its synonymous terms are:—“Periodontal membrane,” “root membrane,” “dental periosteum,” or “alveolo-dental ligament.” The expression “Periodontal membrane” is, for the sake of convenience, used here and throughout this work.

Origin.—It is derived from the outer layers of the dental capsule.

Distribution.—It exists in all teeth attached to the jaws by gomphosis articulation, viz.: those of man and most mammals, crocodiles, and a few uncommon fish. The teeth of the vast majority of fishes, and some reptiles, are fixed by either ankylosis, hinge, or membrane. In these the periodontal membrane is wanting.

The gingival portion of the periosteum, according to Stöhr,¹ is called the “annular dentinal ligament,” or the *ligamentum circulare dentis*. This is entirely incorrect, however: there are no tissues specially marked off from the others to form even a distant resemblance to a ligament. No constricting bands of strong connective tissue fibres exist at the cervical regions of the teeth.

¹ Stöhr, “Text-book of Histology,” Wurzburg; p. 112, 1914

Macroscopical Appearances.—A white dense membrane covering over the roots of teeth, it varies in thickness in different individuals, in different teeth in the same mouth, and at varying periods of life. It is thickest in childhood and thinnest in senility. In measurement, in adult age, it ranges from 350μ to 500μ in width, and from 8 to 20 mm. in length. These are average statistics: in the localities where it dips into bays or recesses of the alveolar process, the width is proportionately increased. Its microscopical nature is best studied when the tissue is retained *in situ*, easily accomplished in sections prepared by fixing and hardening the soft part first in formalin, or Müller's fluid, and afterwards decalcifying with hydrochloric or other acids, and finally cutting on an ether-freezing microtome.

HISTOLOGY

The several parts of the minute structure of the periodontal membrane may be described as follows:—(i) The fibrous elements; (ii) Cells; (iii) Blood-vessels; (iv) Nerves; (v) Calcospherite spherules.

1.—*The Fibres*

The fibrous elements are grouped into two separate and specific divisions, which, however, are indistinguishable anatomically:—(A) The "principal" fibres,¹ and (B) The ordinary and less important connective tissue fibres.

A

The principal fibres of which the greater part of the membrane is composed are of the white connective tissue variety, no elastic fibres whatever being present (Black). Many are fasciculi of delicate wavy fibrils gathered together to form coarse, strong bands; but more commonly they run in loose bundles. At the neck of the teeth they pass immediately outward from the cementum,—the fibres generally lying fairly parallel to each other,—to be inserted into the fibrous mass of gum tissue.

¹A term first suggested by Black in "Periosteum and Peridental Membrane," 1887, to whom a great deal of our knowledge of the histology of this tissue is due.

Nearer the radicular portion, the fibres merge into the connective tissue fibres of the periosteum of the alveolus, from which they cannot be readily distinguished. In the apical region they are very irregular, or may be almost absent, this portion of the socket of the tooth being filled with small cells, and few fine fibres (the "indifferent tissue" of Black), with abundant room from the passage of blood-vessels and nerves. The apical region

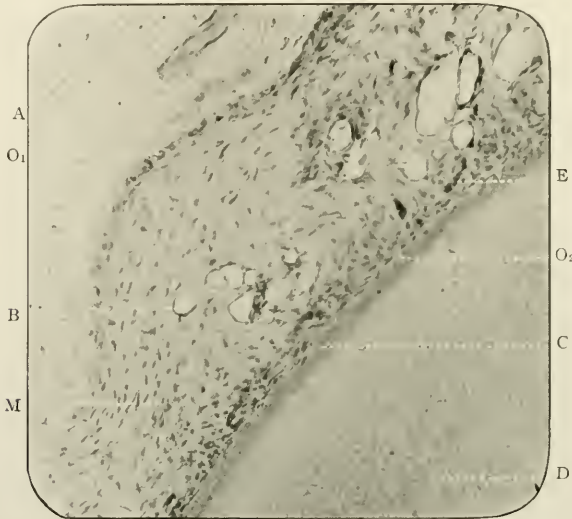

FIG. 142.—Transverse section of the periodontal membrane of man *in situ*. Prepared by the Author's process. Stained with Ehrlich's acid hæmatoxyline. Magnified 250 times. M. The root-membrane with its fibres and cells; B. Its blood-vessels; and E. Its epithelial gland-like bodies; D. Dentine; C. Structureless cementum; A. Bone of the alveolus; O₁. Osteoblasts on the wall of the alveolus; O₂. Osteoblasts on the surface of the cementum.

may measure 0.5 mm. in depth. At the surface of the gum the fibres course in wavy lines directly outwards, *i.e.*, at right angles to the long axis of the tooth, and then suddenly upwards to be inserted into the gum; at the neck of the tooth near the alveolar margin they are inclined root-ward, and are inserted into the bone or periosteum. At the mid-distance—otherwise the alveolar portion of the membrane,—they run squarely across; but near the apex of the root, they assume a crownward direction. At the apical region itself they radiate from the cementum to the bone.

The fibres which arise from the cementum are finer than those inserted into the *lamina dura*, and are continuous with Sharpey's fibres of the cementum; and the large ones, as a rule, break up into delicate bundles of fibrils.

They all pursue a rather sinuous course, being deviated from straight lines by the presence of the vascular and nervous zones in the central portions of the membrane.

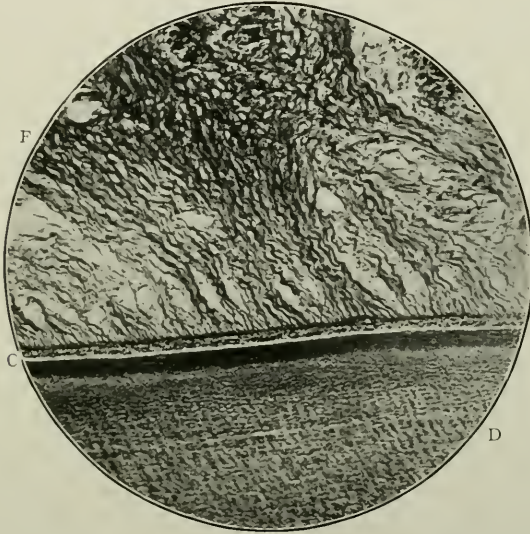


FIG. 143.—The fibres of the periodontal membrane. d. Dentine; c. Cementum; f. Fibres. Preparation and photomicrograph by Dr. H. Box, Royal College of Dental Surgeons, Toronto.

B

The ordinary fibres are found among the foregoing. They are the common type of connective tissue fibres with nuclei and tissue corpuscles. They are arranged diagonally to the principal fibres, and are usually difficult to distinguish, on account of their feeble staining properties.

2. *The Cells*

The cellular elements are of several varieties.

(a) The lamellar connective tissue corpuscles are spindle-shaped, nucleated, ramified, and very prominent. They are

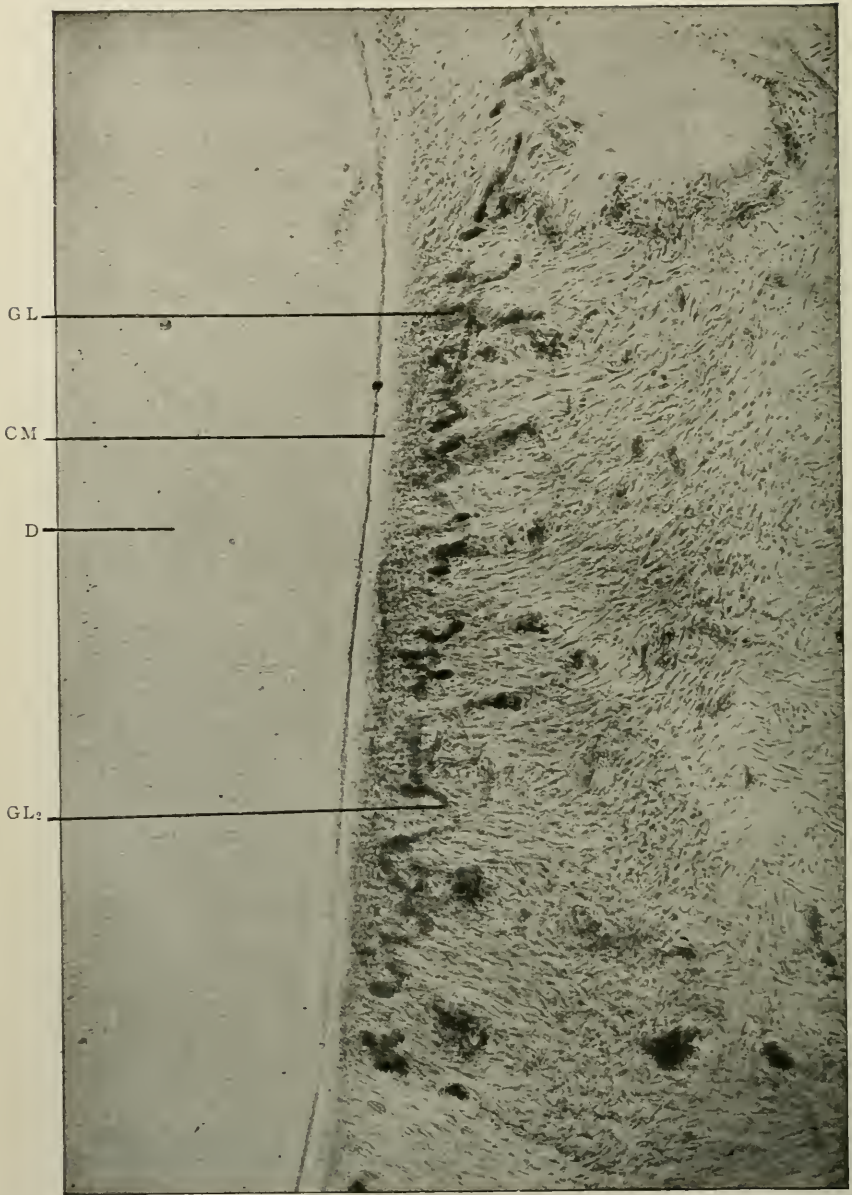


FIG. 144.—A small area of a transverse section of the root of a tooth, and a portion of the periodontal membrane, showing glands. D, Dentine; C.M. Cementum; G.L. and G.L.₂, Tubular glands (?) winding among the fibres of the membrane. (Photomicrograph by G. V. Black.)

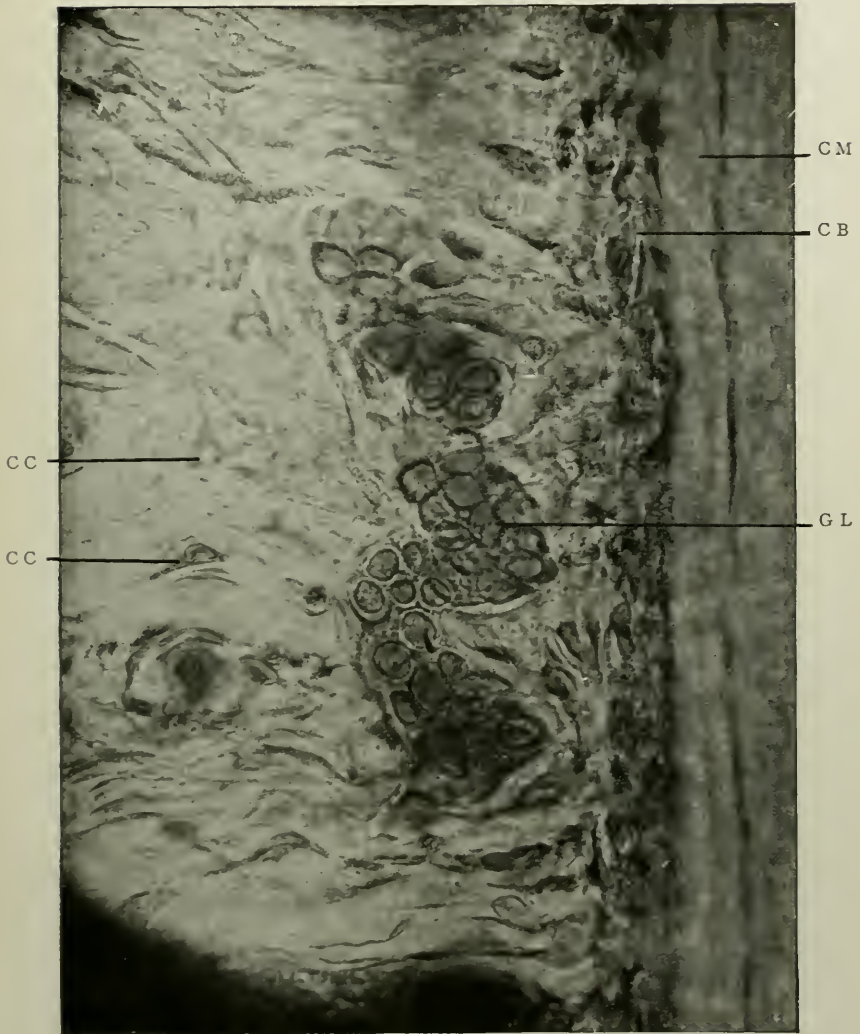


FIG. 145.—Epithelial bodies in the periodontal membrane. c.m. Cementum; c.b. Osteoblasts lying between the fibres of the membrane close to the cementum; g.l. Epithelial cells with nuclei; c.c. Connective tissue cells. (Photomicrograph by G. V. Black.)

called "fibroblasts" by Black. They are freely distributed to all parts of the membrane.

These cells, or corpuscles, differ in no essential particular from




FIG. 146.—Showing gland-like epithelial bodies lying between the large white fibres of the root membrane. D. Dentine; c.m. Cementum; c.b. Osteoblasts; GL₁; GL₂, Glands (?); F. Large white connective tissue fibres. (Photomicrograph by G. V. Black.)

the ordinary cells or corpuscles of connective tissues generally. Thus, they are nearly always of the *flattened* or *lamellar* pattern. They are frequently affixed to the surfaces of the peripheral fibres; may extend between several fasciculi; and are most com-

monly joined by means of branching processes, which in this manner form delicate reticula throughout the tissue between the principal fibres.

They are composed of clear granular protoplasm, and their nuclei are oval or fusiform in shape. They may be well shown by staining the membrane *in situ* with chloride of gold immediately after extraction, stripping from the surface of the cementum, and teasing-out pieces thus removed in a plane parallel to the periphery of the root.

(β) Osteoblasts are flattened, cubical, or irregularly shaped nucleated cells applied intimately to the external surface of cementum and bone. This irregularity in shape, in the former situation, according to Noyes ("American Text Book of Operative Dentistry, p. 144, 1901), is caused by these cells "fitting around the attached fibres of the membrane, so as to cover the entire surface of the membrane between the fibres." They are called "cementoblasts" by Black, Noyes and others; but no points of morphological difference can differentiate them from those ordinary osteoblasts which are found in the inner layer of the periosteum of the alveolar bone. This being the case, it is advisable to delete the word "cementoblast" from dental terminology.

(γ) Osteoclasts, or myeloplaxes, are multi-nucleated giant cells, oval in shape, being found where absorption of either bone or cementum is in progress. They measure 30μ in diameter, and are most frequently discovered in the bay-like recesses (the foveolæ of Howship) on the periphery of these hard tissues. In the periodontal membrane they lie in close contact with the surface, which they are about to absorb, and thus, while intervening in the interfibrous spaces, destroy or cut off the ends of the principal fibres, when they, as Sharpey's perforating fibres, are built into the bone or cementum.

(δ) Epithelial cellular bodies or "rests" are not infrequently observed in the inner portion of the periodontal membrane. They appear near the cementum, just outside the layer of osteoblasts, and are seen exceedingly well in horizontal sections. Very pronounced are they in the root membranes of the teeth of the sheep and pig, less so in man, except in the teeth of

the young. Attention was originally attracted to these masses by Malassez¹ in 1885; and Black described and figured them in "Periosteum and Peridental Membrane," 1887; but in ascribing to them the rôle of lymphatics, he was probably incorrect, as no true lumina have ever been discovered, and their connection, if any, with the hypothetical lymphatic system has never been traced. This worker has, however, modified his views on their functions and character in his latest addition to the literature of the subject (*The Dental Cosmos*, p. 101, 1899).

Most probably, whatever be their functions, they take their origin from scattered, unabsorbed, or unatrophied remnants of the epithelial sheath of Hertwig, as was first pointed out by von Brunn,² or from vestigial remains of the tooth-band, which have persisted after disappearance of that structure.

Under magnifications of 250 diameters, their histological characteristics can be easily discerned in suitably stained cases.³

Situated between the principal fibres, and running generally in an outward direction, they assume the form of cords or tube-like collections of epithelial cells, each of which contains in the centre a large oval nucleus. Surrounding each "rest" is, apparently, a very delicate basement membrane. Cut obliquely, there is some trace of what might be a lumen; but the glandular nature—or otherwise—of these bodies as described by Black requires more investigation and confirmation before dogmatic statements as to their real character can be expressed.

Regarding the so-called "gingival gland," Black writes as follows: "This is a small lobulated mass of connective tissue cells lying close to the attachment of the gum to the tooth at the gingival line. It is mostly included within the prolongations of the epithelium of the gingival trough, or that which covers the portion of the free margin of the gum lying next to the neck of the tooth. It has a strong glandular appearance. Its cellular elements are not epithelial, but are round connective tissue cells.

¹ "On the Existence of Masses of Epithelium round the Roots of Adult Teeth, in a Normal State." *Journal of the Brit. Dent. Association.*

² *Archiv. für Mikroskop. Anatomie*, 1887.

³ Hæmatoxylene is a useful reagent.

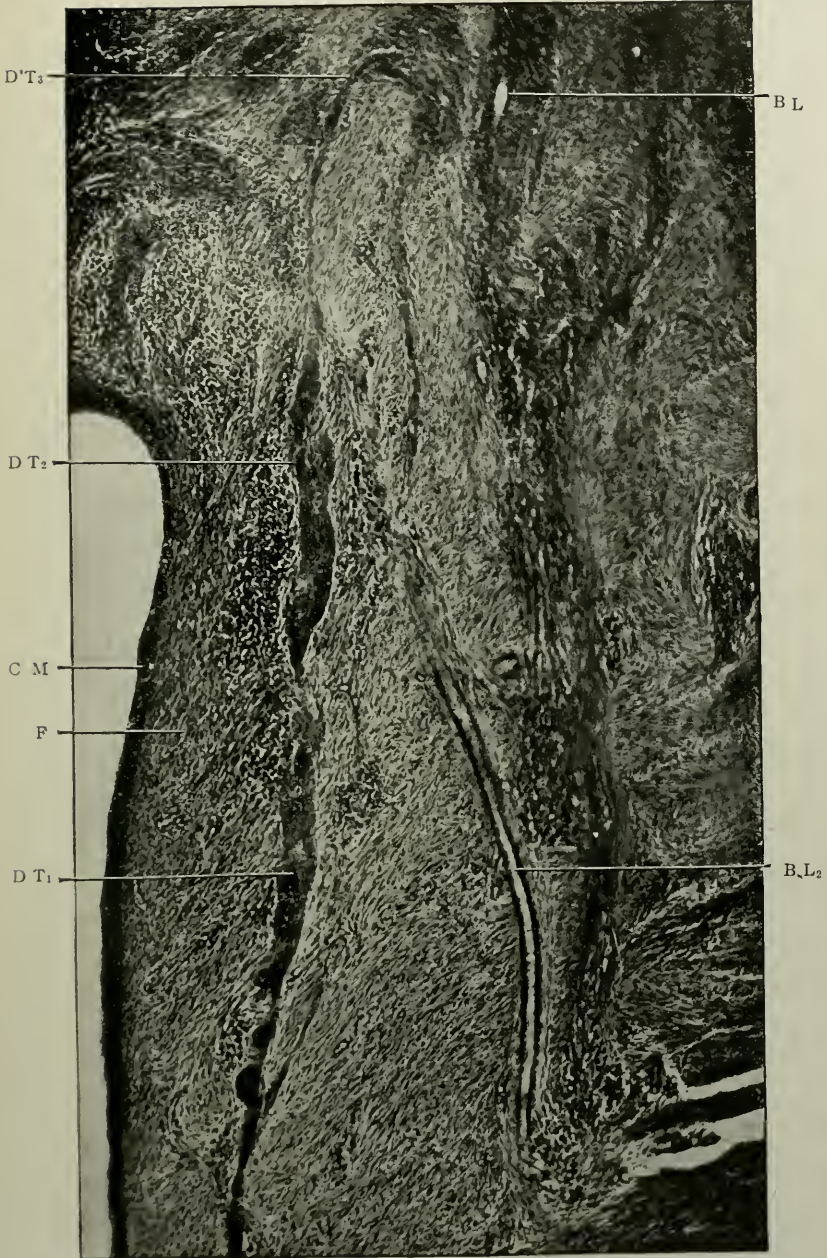


FIG. 147.—Supposed duct of glands of the root membrane, starting from a group of glands not shown in the field. C.M. Cementum; D.T.₁, D.T.₂, D.T.₃, Duct; F. Fibres of the membrane; B.L. Blood-vessels. (Photomicrograph by G. V. Black.)

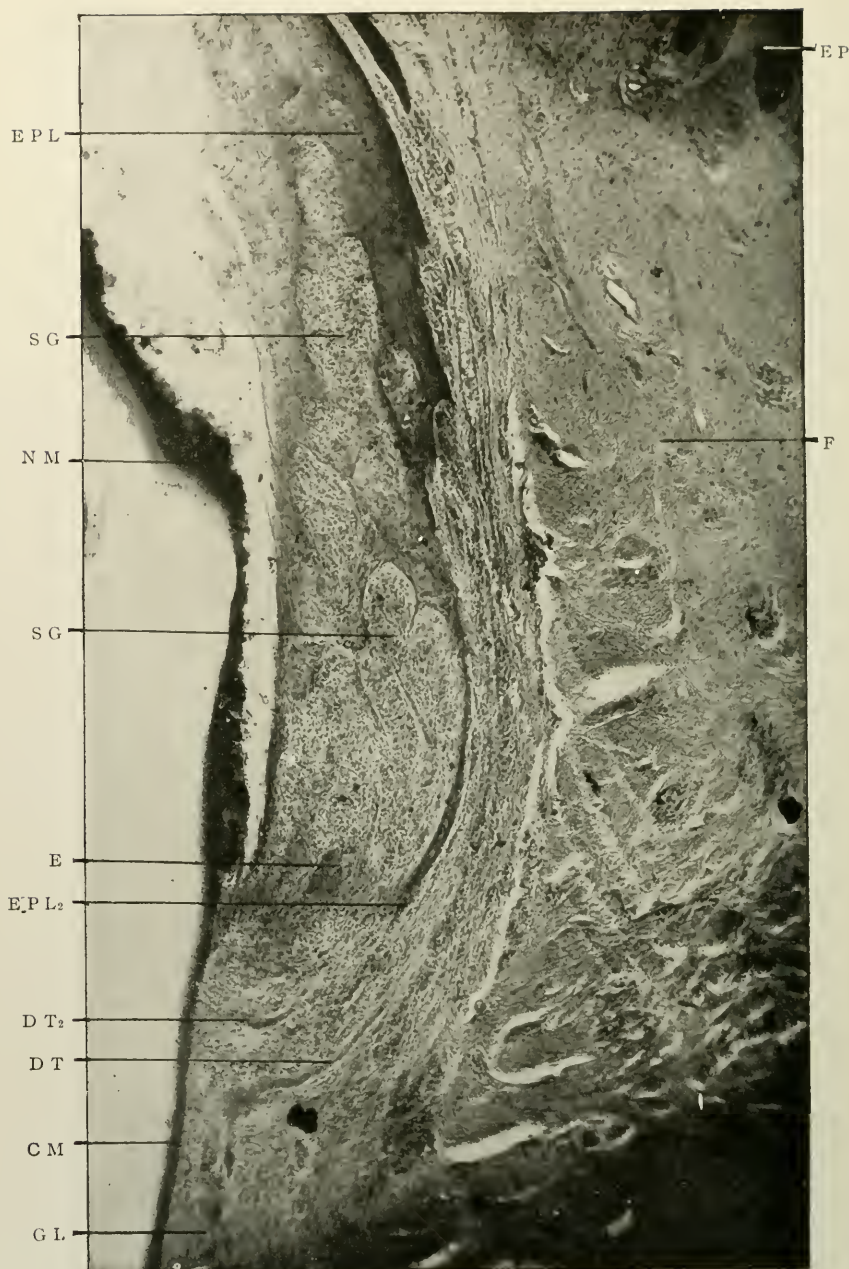


FIG. 148.—The so-called "gingival gland." S.G. S.G. Gland; C.M. Cementum parted from the dentine; N.M. Nasmyth's membrane separated from the enamel by the acid used in decalcification; E.P.L. Epithelial column dividing the gland from the surrounding tissues; except at its base; E. Epithelial cells; E.P. Epithelium of outer portion of free margin of the gum; G.L. Glands of root membrane; D.T. Duct leading from glands towards the gingivus; D.T₂. Small loop of second duct; F. Fibrous tissue of the gum. (Photomicrograph by G. V. Black.)

These are in lobules, divided in part by delicate hyaline membranes, which often appear double in sections, occasionally giving the appearance of ducts. But close studies of them indicate rather that they are duplicatures of the membrane envelope. In part, the lobules are divided by epithelial bands from the prolongations of the epithelium of the gingivæ. A strong epithelial band from the gingival epithelium encircles the whole mass and parts it from the neighbouring tissues except at its base. In cross-sections this epithelial band is seen to be a continuous sheet without break. Though definitely lobulated, this body does not seem to possess the character of a gland, and I should not suppose from an examination of this tissue that it had a glandular function. It encircles but a portion of the neck of the tooth, usually only the approximal portion, thinning away towards the buccal or lingual, so that in many of the lengthwise sections it may be very small or does not appear at all."

3. *The Vascular System*

This lies in the central zone of the tissue and is fairly abundant. Arterial branches having a common origin with those of the pulp pass towards the crown from the apical region. Running thence, they branch, divide, and subdivide and are freely distributed through the body of the membrane, meeting and inosculating with the vessels of the gum and periosteum, and even occasionally of the Haversian systems of the alveolar bone.

The capillary network is scanty, the blood supply of the membrane being chiefly arterial and venous. Of the former the largest vessels, in horizontal section, may measure 0.05 mm. to 0.1 mm. in diameter.

The veins accompany the arteries.

4. *The Nervous System*

The exact manner of the distribution and nature of the ultimate terminations or ramifications or anastomoses of the nervous supply of the root membrane is unknown: it is a branch of Dental Histology, which so far has been practically ignored.

According to Noyes, however, "six or eight myelinic fibres enter the apical region in company with the blood-vessels, and they receive other trunks through the walls of the alveolus and over the border of the alveolar process" (*Op. cit.* p. 155).

5. *Calcospherite Spherules*

Tiny, almost structureless, rounded masses of calcoglobulin, called calcospherite spherules, may occasionally be found near the epithelial bodies. They are more constant in inflammatory conditions of the membrane (*q.v.*).

Fig. A.

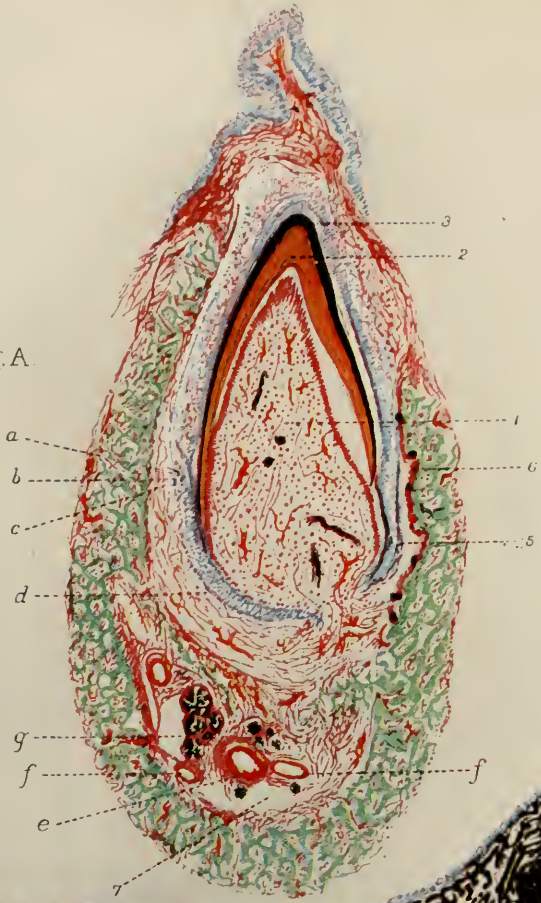
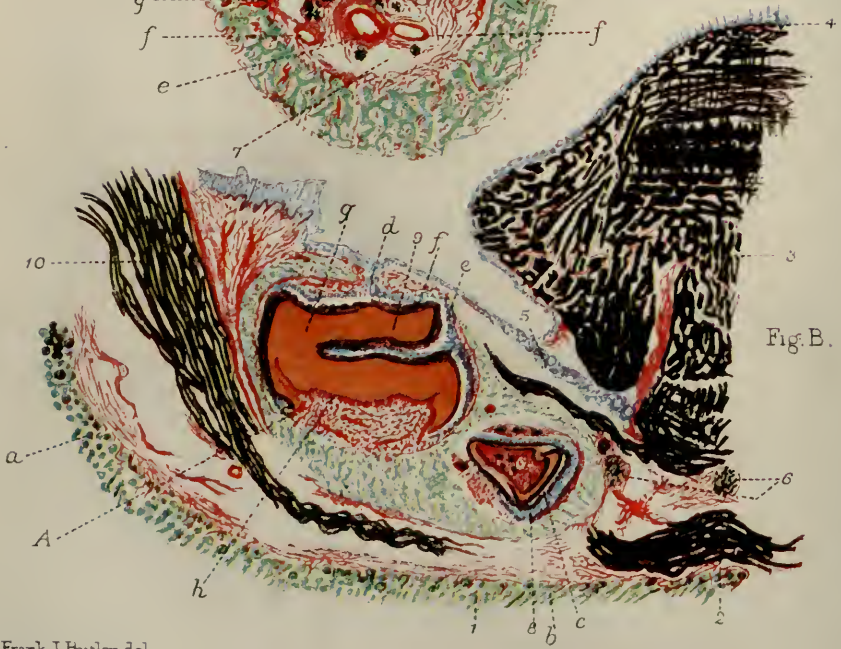

Fig. B.



Frank J. Butler del.

Two Phases of Dental Histogenesis in Mammalia.

DESCRIPTION OF PLATE II

FIG. A.—Sagittal section through the mandible of a pup at birth. Fixed, hardened and decalcified. Cut on an ether-freezing microtome.

1, Dentine papilla; 2, Dentine; 3, Enamel; 4, Enamel organ; 5, Part of dental capsule; 6, Alveolus of jaw forming the socket of the tooth; 7, Mandibular canal. A. Ameloblasts; B. *Stratum intermedium*; C. Stellate reticulum; D. External epithelium; E. Mandibular artery; F. Mandibular veins; G. Mandibular nerve.

FIG. B.—Lateral half of coronal section through mandible of a foetal rat. Prepared similarly to preceding Figure.

1, Dermal structures on under surface of jaw; 2, Muscle fibres; 3, Muscle fibres of tongue; 4, Lingual papillæ; 5, Salivary gland; 6, Nerve bundles; 8, Root of incisor tooth cut through; 9, Molar tooth; 10, Muscle fibres. A. Hairs cut transversely; B. Hairs cut obliquely; C. Enamel organ of incisor tooth; D. Tooth-band; E. Enamel organ; F. Enamel; G. Dentine; H. Odontoblasts.

PART II
THE ORAL TISSUES

CHAPTER IX

THE ORAL CAVITY AND ITS ACCESSORIES

MICROSCOPICAL ELEMENTS OF THE: (i) Lips and cheeks; (ii) Tongue; (iii) Salivary glands; (iv) Hard and soft palate; (v) Palatine tonsils.

THE LIPS AND CHEEKS

These consist for the most part of muscular tissue, which is freely supplied with blood-vessels and nerves. Loose areolar tissue, fat lobules, and great quantities of minute glands make up the rest of their substance. Externally they are protected by skin, internally by mucous membrane. This is studded everywhere with myriads of vascular papillæ of microscopic size. In many papillæ nerve-end-bulbs are found.

“Labial” glands (small racemose bodies) have the free terminations of their excretory ducts directed to the inner surface of the lips, “buccal” and “molar” glands to that of the cheek, while small sebaceous glands occur in the outer part of the red border of the lips.

The mucous membrane of the mouth generally is lined with epithelium of the stratified squamous variety, many “spiny” cells lying in the deeper layers.

THE TONGUE

The tongue is a large soft organ, flattened from above downwards, situated in the floor of the mouth.

It consists mainly of muscles, extrinsic and intrinsic, the latter being those placed entirely in its substance. The fibres—striated and voluntary—exhibiting the usual features of striped muscular tissue generally, run in various directions,

so that in any and every section, some are cut longitudinally, some vertically, others transversely, thus forming particularly attractive preparations for the microscope.

Greater interest than that of the histology of the muscles,

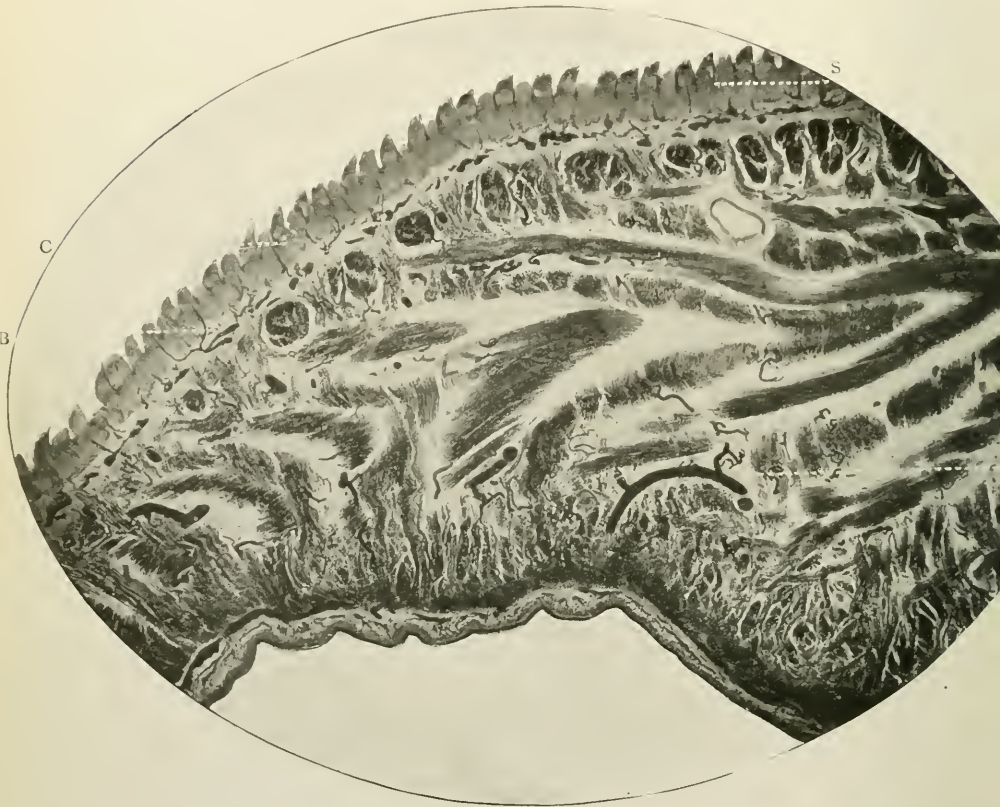


FIG. 149.—Coronal section of the tongue of a dog. Prepared by hardening in alcohol. Stained with hæmatoxyline and eosine. Magnified 12 times. s. Superior surface or dorsum of tongue; c. The epithelium of the filiform papillæ; b. Blood-vessels injected with carmine; i. Inferior surface of tongue.

however, attaches to the mucous membrane and its abundant supply of eminences or papillæ of varying size and shape.

The anterior two-thirds of the dorsum presents on its surface, tip, and sides, where the mucous membrane is thin and closely adherent to the muscular layer beneath, enormous numbers of papillæ known as “filiform,” “fungiform,” and

“circumvallate.” All are macroscopically visible, but microscopically of considerable interest.

HISTOLOGY

Each papilla is covered, like the rest of the oral mucous membrane, with multitudes of secondary papillæ closely embraced by the epithelium. Each contains a capillary loop, and plexus of nerves.

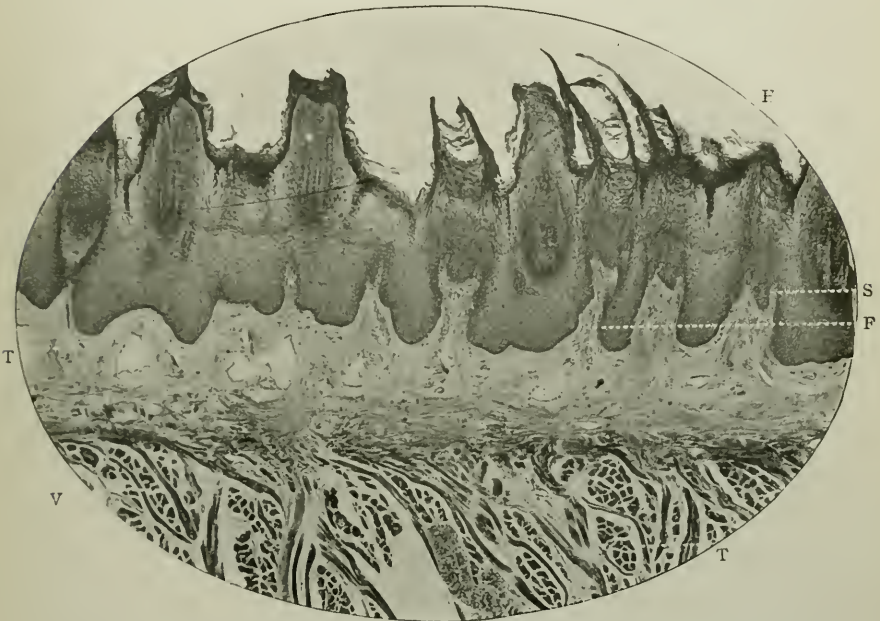


FIG. 150.—Vertical section of tongue of man. Prepared in the usual way. Stained with hæmatoxyline. Magnified 70 times. F. Conical papilla; S. Secondary papilla; H. Epithelium of laminated structure between the papillæ, and extended into ciliaform processes over it. L. Tunica propria; V. Muscle fibres cut vertically; T. Muscle fibres cut transversely.

As already stated, the papillæ are of three kinds:—

1. *The conical papillæ* abound all over the dorsum, but are absent from the base of the tongue. In shape they are tiny elevations with tapering or cone-shaped extremities. They are the smallest of the three varieties, measuring, in man, to the base of the mucous membrane, 0.9 mm. to 1.0 mm. in length. Their secondary papillæ are peculiar and unique in containing

great quantities of elastic fibres, and being clothed by special epithelium of a cornified nature, which "forms a separate horny process over each secondary papilla, greater in length than the papilla which it covers" (Schäfer).

When a bundle of these thread-like projections exists over the conical papillæ (which are often quite devoid of them), the term "filiform" is employed to designate the character of the papillæ. They are easily found on the surface of the tongues of cats and other carnivorous animals.

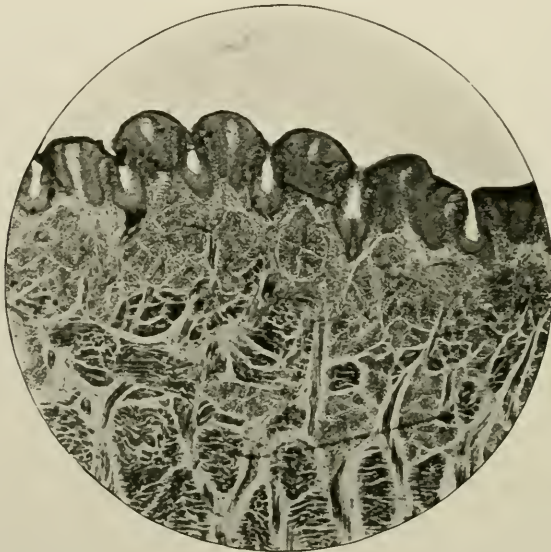


FIG. 151.—Fungiform papillæ with gustatory cells of tongue of rabbit. Stained with carmine. Magnified 30 times.

2. The fungus-shaped elevations which beset the middle and fore part of the tongue are called *fungiform papillæ*. In the recent state they are of a bright red colour. Possessing blunt rounded extremities, they are attached by narrow foundations.

3. Most interesting of all, are the *circumvallate papillæ*, so called from their environment. Each is placed in a poculiform depression of mucous membrane, and has a cone-shaped appearance, surrounded as it is by a trench or *fossa*, on the outer free margin of which is a slight elevation of mucous

membrane. This, completely circling the papilla, is the *vallum*, which is comparable to a rampart. Hence the name.

These papillæ are very few in number, sometimes not more than a dozen existing on one tongue. They are located on

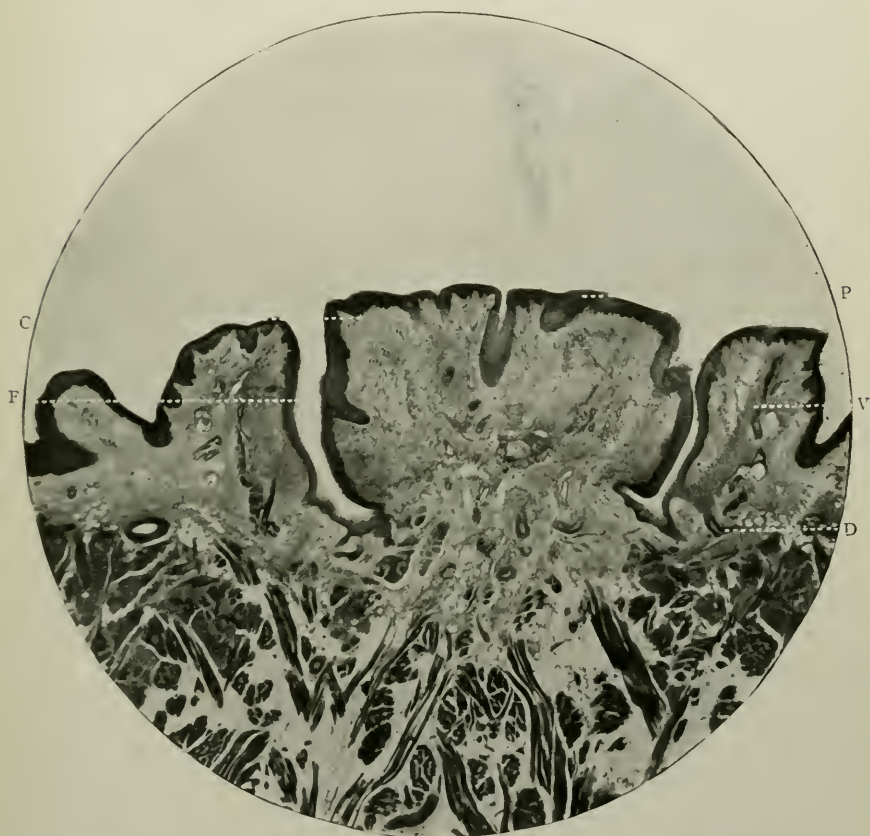


FIG. 152.—Circumvallate papilla of the tongue of man. Prepared in the usual way. Stained with hæmatoxylene, and counter-stained with eosine. Magnified 30 times. p. Circumvallate papilla (its epithelium); f. Fossa; v. Vallum; d. Duct of gland opening into base of fossa; c. Corium of papilla.

the posterior third of the organ, arranged in two rows, which meet together at a point, like the arms of the letter V. In width they may measure as much as 2.5 mm.; width inclusive of the vallum on either side 4.5 mm. In addition to the vascular and nervous supply of the corium, the stratified epithelium which is extremely thick, contains in it several "taste buds or

goblets," both on the sides of the papilla itself and in the mucous membrane of the *fossa*. At the base of the *fossa*, which may measure 1.25 mm. in depth, the openings of the ducts of one or more glands can be seen.

"Taste-buds" are oval in outline, and consist of a collection of narrow and fusiform gustatory cells, all enclosed by a single

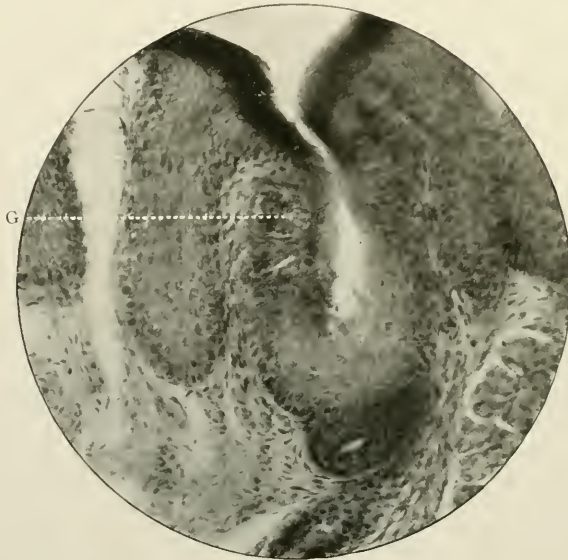

FIG. 153.—The gustatory cells in a fungiform papilla of the section photographed in Fig. 151. Magnified 300 times. G. Goblet or gustatory cells.

layer of broader fusiform cells, the *encasing cells*. A slight depression in the lingual epithelium over the goblet has at its base, a group of fine trichinous processes, which are the terminations of these gustatory cells.

The base of the tongue contains many lymph nodes scattered in diffuse lymphoid tissue in the *tunica propria*, (collectively named the "lingual tonsil"), and numerous mucous glands. The latter are large and broad, their dimensions, in man, being 1.4 mm. in width, and even 3.0 mm. in length. They possess the usual histological features of mucous glands generally (Fig. 162).

THE SALIVARY GLANDS

The parotid, sublingual, and submaxillary glands secrete saliva.

In man, the former is composed of acini of serous cells; the sublingual of mucous acini, and the latter of both, though the serous acini preponderate. According to its secretion, so do the histological elements of each gland differ.

HISTOLOGY

They are compound racemose glands (Fig. 158), consisting of an aggregation of lobules, each of which has a duct which, after branching, terminates, on the one hand in fine small branches into which the acini of the glands open, and on the other, in larger ducts which ultimately end by a free orifice on the surface of the mouth. Many blood-vessels ramify in a small amount of loose connective tissue, which forms the investment for the lobules, and for the gland itself. In the last situation, the capsule contains ordinary flattened cells, a few granular plasma-cells, lymph corpuscles, and occasionally a little adipose tissue.

Ducts

Histologists arbitrarily divide the ducts into an *intralobular part* and an *intercalary part*. The *intralobular portions*, larger than the rest, and near the free opening of the duct, are lined with epithelium of which the cells have the following characteristics:—They are large, columnar or conical in shape, with their truncated extremity directed towards the lumen: they have a centrally placed spherical nucleus: they are granular at their inner and finely striated at their outer extremities (see diagram, Fig. 159).

The fibrillated markings are well seen in the submaxillary gland.

The large ducts are covered with a coating of fibrous and elastic tissue, intermingled with a few small involuntary muscular fibres.

The *intercalary portions*, shorter and narrower than the preceding, extend to the acini, and are lined with clear flattened cells, possessing elongated nuclei, at their most distal part. As they approach the intralobular ducts, their lumina are lined

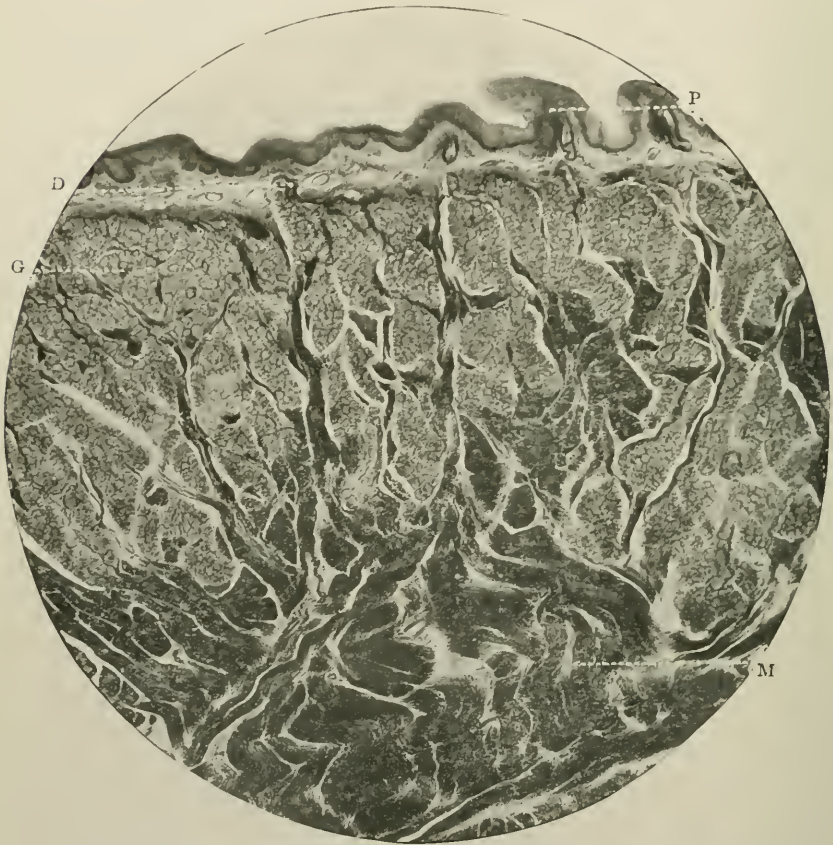

FIG. 154.—Vertical section through base of the tongue of man. Prepared by hardening in 3 per cent. nitric acid, and subsequently staining with methylene-blue. Magnified 25 times. G. Mucous gland; d. Duct of gland opening on to the surface; p. Conical papilla; m. Muscle fibres.

with cubical cells with small nuclei (see Figs. 159 and 160).

Acini

The acini constitute the secreting part of the glands, and are of two kinds: (A) mucous, and (B) serous.

A

Mucous Acini

Bounded by a delicate reticulated basement membrane, each acinus is lined by a single layer of true secreting cells. These vary according to their activity or passivity.

In the latter condition they are large, clear, granular, and spheroidal in shape, and nearly fill the whole of the acini. They take stains very indifferently. Each nucleus, somewhat

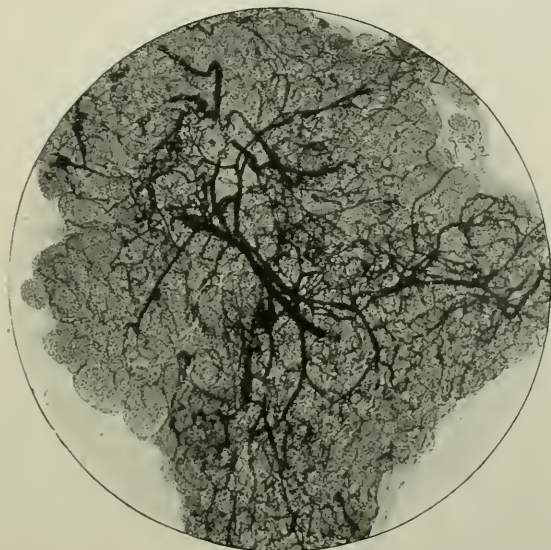

FIG. 155.—Transverse section of salivary gland of cat, stained with picric acid, blood-vessels injected with carmine. To show its abundant vascular supply. Magnified 30 times.

flattened, is placed near the basement membrane. The transparent appearance is due to the presence of mucin or mucigen.

In addition, there are also found certain marginal cells, the *crescents of Gianuzzi* (the *demilunes* of *Heidenhain* of some authors). They have semilunar outlines, are small, very granular, and stain deeply with the usual dyes.

In an active state, as the result of stimulation, the cells stain readily, become rather smaller and more granular, and the nuclei, now no longer compressed, occupy the central parts of the cells (see Figs. 161 and 162).

B

Serous Acini

At rest, these cells, when properly prepared and stained, are granular, with their nuclei in their centres completely

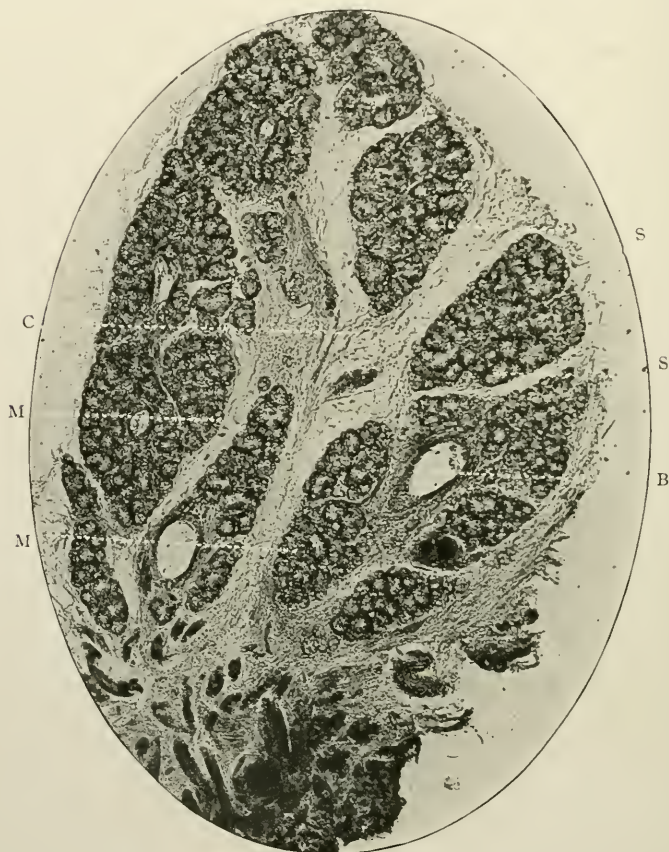


FIG. 156.—Submaxillary salivary gland of man. Prepared in the usual way. Stained with Ehrlich's acid hæmatoxyline. Magnified 20 times. Shows several lobules. s.s. Serous; m.m. Mucous; B. Blood-vessel; c. Connective tissue between the lobules.

obscured by the albuminous material in their protoplasm. The lumen similarly to that of a mucous acinus is frequently totally occluded.

During a period of prolonged activity, the cells appear to

be shrunken, a few granules have collected in their inner aspects, the nuclei are clearly revealed and easily recognised, and the lumen is large and patent. These changes are depicted in the accompanying diagrams (Figs. 163 and 164).

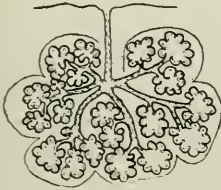


FIG. 157.—Diagram of a racemose gland.

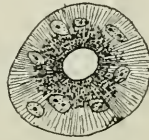

FIG. 158.—Intralobular duct.



FIG. 159.—Mucous intercalary duct.

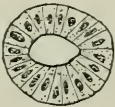

FIG. 160.—Serous intercalary duct.

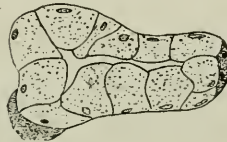

FIG. 161.—Acinus of a mucous gland during a period of passivity.

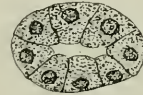

FIG. 162.—Acinus of a mucous gland during a period of activity.

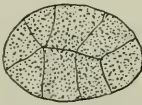


FIG. 163.—Acinus of a serous gland during a period of passivity.

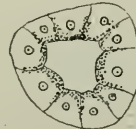


FIG. 164.—Acinus of a serous gland during a period of activity.

HARD AND SOFT PALATE

The histology of the osseous framework, and fibrous covering of the roof of the mouth requires but a brief survey, a description of its bony structure appearing in the following Chapter.

HISTOLOGY

The bone is covered with a thin layer of periosteum and mucous membrane. Of the former nothing need further be said, its character being similar to that of the periosteum of bones generally; the latter, however, thrown into folds (*palatal*

rugæ) exhibits the same characteristics as in other parts of the mouth, except that in these ridges, as well as in the *papilla palatina* or incisive pad, the cells are larger, coarser, and more multiplied than elsewhere.

The vascular and nervous supplies are scanty, as is also the number of mucous glands. Adipose tissue is present to a limited extent.

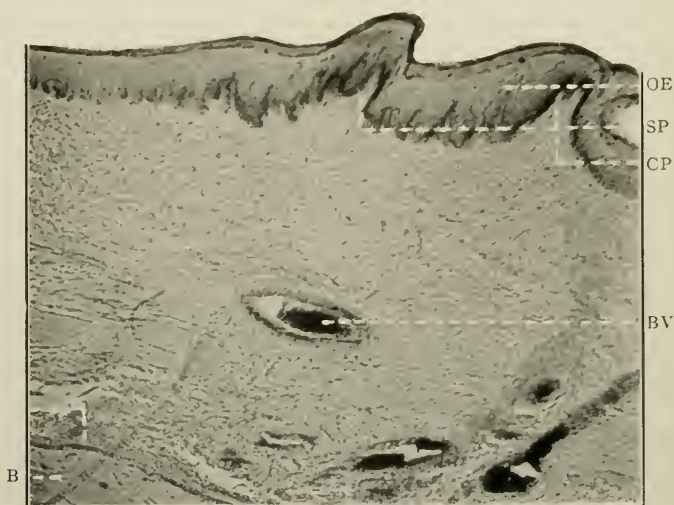


FIG. 165.—Vertical section of the hard palate. Stained with hæmatoxyline and eosine. Magnified 200 times. O.E. Oral epithelium, with surface projecting as rugæ; s.p. Simple papilla; c.p. Compound papilla; b.v. Blood-vessel; B. Surface of palate bone; P. Periosteum.

The soft palate consists of voluntary muscular fibres, and a great number of glands all clothed with mucous membrane, which is covered on the anterior surface with stratified squamous epithelium, and on the posterior surface with ciliated columnar cells. It measures approximately 10 mm. in thickness.

The uvula consists chiefly of voluntary muscle fibres and compound racemose glands, which abound in great numbers on the anterior surface of the soft palate where they form an almost complete layer under the squamous stratified epithelium.

THE FAUCIAL OR PALATINE TONSILS

The tonsils are soft, very vascular bodies placed between the anterior and posterior palatine arches or pillars of the fauces.

HISTOLOGY

They are composed of lymphoid tissue enclosed in a fibro-elastic capsule. Dense masses of lymphoid cells are collected here and there, and form the lymphoid follicles of the tonsil. The latter are large oval or round bodies having a breadth, in man, of 1.5 mm. and a length of 3.25 mm.

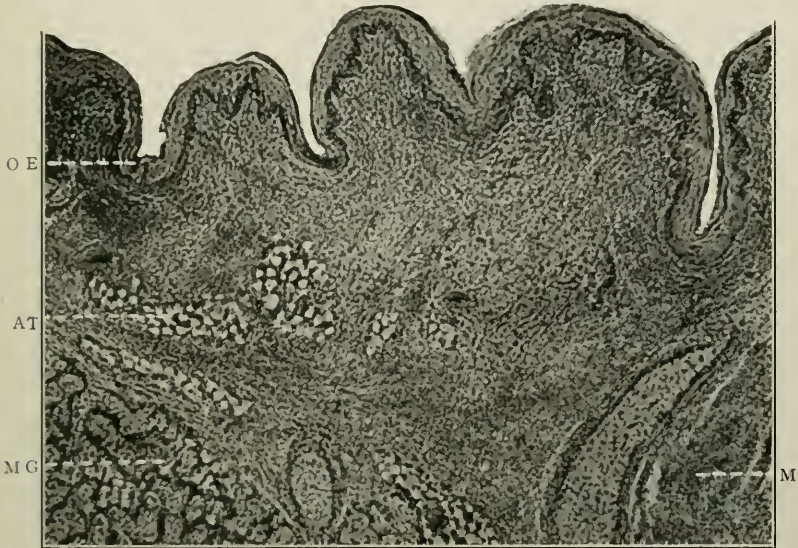


FIG. 166.—Vertical section of oral surface of the soft palate. Stained with hæmatoxylen and eosine. Magnified 200 times. O.E. Oral epithelium; M. Voluntary muscle fibres; M.G. Mucous gland; A.T. Adipose tissue.

The framework of the follicles is a delicate stroma of fine retiform connective tissue, similar to the white fibres of areolar tissue. Hence it contains no nucleated cells as such, but trabeculæ of fibrous tissue surrounded by an open network of fibres more or less densely aggregated.

The cells contained in these are lymphoid cells, which resemble lymphocytes. They differ, however, in the facts that they have less cytoplasm, and a relatively larger nucleus.

Stratified squamous epithelium extends over the exposed part of the tonsil. Opening on the free surface of the organ are numerous crypts or clefts into which the epithelium dips,

being continuous all over except at the tiny orifices of a few mucous glands, the ducts of whose acini open on to the surface of the crypts.

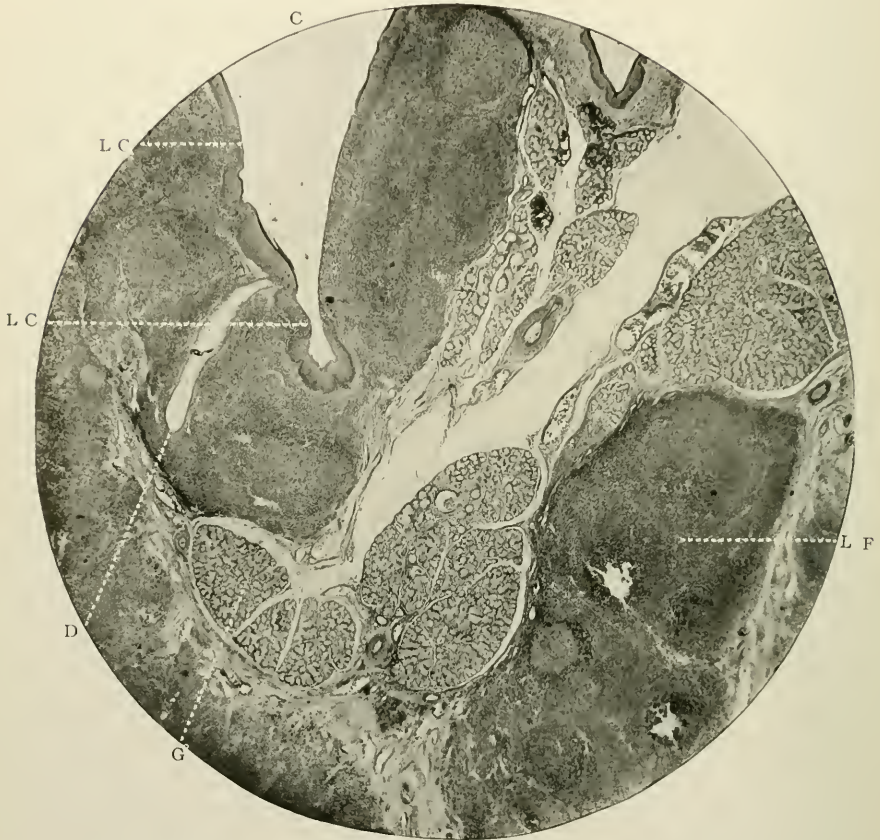

FIG. 167.—Vertical section of tonsil of man. Prepared by fixing and hardening. Stained with hæmatoxyline; counter-stained with eosine. Magnified 60 times. L.F. Lymphoid follicle; c. Crypt of tonsil; d.c. Lymph cells passing through the epithelium of crypt; G. Mucous gland; d. Duct of same, opening into the base of crypt.

Lymphoid cells pass through this epithelial layer of cells from the follicles; become free and detached on the surface; and mixing with the saliva, appear as the so-called “salivary corpuscles.”

CHAPTER X

THE HISTOLOGY OF THE MAXILLARY AND MANDIBULAR BONES

MICROSCOPICAL ELEMENTS IN: (i) Bone of Canine fossa; (ii) Interdental septa; (iii) Hard Palate; (iv) Wall of Antrum; (v) Angle of Mandible; and (vi) Alveolar process.

The hitherto published descriptions of the minute structure of the osseous framework of the lower face and jaw,—such structures as are, in a word, in direct anatomical relationship and continuity with the teeth of man,—have necessarily been given only very infrequently; but in addition to this, the descriptions which have appeared in text-books and journals have taken for granted that the histology of these particular bones corresponds with that of tabular and irregular bones in general.

To make this contribution complete, a few forewords are necessary and advisable.

GENERAL CHARACTERISTICS

Origin.—Each maxilla is probably developed from one centre of ossification as a membranous bone, at a spot which marks the site of the canine tooth germ, external to the cartilaginous nasal capsule. Each premaxilla is developed from one centre of ossification. Each half of the mandible, according to Low (*Proc. Anat. Soc. of Great Britain and Ireland*, 1905), is developed from one—the dentary—centre in membrane. Meckel's cartilage does not form bone, except that it becomes ossified and incorporated with the mandible just below the lingual side of the sites of the sockets of the first and second incisors.

Distribution.—Both forms of bone, known as compact (smooth, dense, and ivory-like) and cancellated or spongy

(rough, open, and soft) are met with in the jaws. The former is found covering each surface both of maxillæ and mandible, the latter constituting the intervening tissue, which in the case of the lower jaw is similar to the diploë of the cranial bones. The compact forms a somewhat thicker shell or crust on the external and internal surfaces of the mandible than on any portion of the maxillæ. Compared with the bone of the sockets of the teeth of the mammalia generally—particularly those of the hyena—that of man is a degenerate structure, on account of the fact that its blood supply is feeble and inadequate, it serves for the attachment of no muscles except a few fibres of the buccinator, and it is therefore almost functionless, and rapidly undergoes at its gingival margins physiological absorption or atrophy. (See Appendix.)

HISTOLOGY

Before considering the special histology of the bones of the jaws, a brief description of the structure of osseous tissue generally must be given.

Bone of the jaw, as bone elsewhere, consists of a calcified fibrous ground-substance or matrix arranged as lamellæ around spaces of varying shape, size, and contents which everywhere penetrate it in all directions. Of these the following are to be noted: (*a*) Haversian systems, (*b*) lamellæ, (*c*) periosteum, and (*b*) Sharpey's fibres.

(*a*) An Haversian system consists of an Haversian canal, several lamellæ, with numerous lacunæ and canaliculi.

Interpenetrating everywhere are short longitudinal passages or tubes which in cross-section appear as rounded or oval apertures, and, longitudinally cut, like short, straight, or slightly curved spaces of fairly regular diameter throughout. These are the Haversian canals. The largest may measure 100μ in width, the smallest 20μ , the average size being about 50μ .

They are surrounded by lamellæ,—thin bands of bony material arranged concentrically round each canal. Dark and light alternate, the difference in the refraction being due to the fact that the opaque lines are occasioned by the calcified

fibrils running longitudinally, and the clear zones by their running transversely. In consequence, the ends only of the fibrils are cut across (see Fig. 176).

Situated between these lamellæ are bone-lacunæ with their canaliculi. The first are flattened branched spaces, which may measure 14μ in their greatest diameter. In dried specimens they look like myriads of tiny, dark, fusiform specks arranged with fairly uniform regularity between the lamellæ, and fully connected with each other and with the Haversian canals by means of many long, narrow tubes or canaliculi which cross the lamellæ. Each cavity is filled with or contains a bone-cell with a large oval nucleus, as first described by Virchow. These are homologous with those of ordinary connective tissue. The wall of each lacuna is formed of some substance which resists the action of decalcifying reagents in a similar manner to the sheaths of Neumann in dentine.

The contents of an Haversian canal, in the recent state, comprise several capillaries, small arteries and veins, a bundle of nerve-fibrils, and a few lymphatic vessels, all imbedded in fine connective tissue, which is surrounded externally by a tough lining membrane possessing properties identical with that which obtains also in the membranous lining of the walls of the lacunæ.

(b) In addition to the concentric lamellæ, others arranged parallel to the surface of the bone, are called "circumferential" or "peripheric;" while a third set, when found between the Haversian systems, are commonly spoken of as "interstitial." Their structures differ in no particular from the concentric lamellæ.

(c) The periosteum can be well studied microscopically in sections where the hard and soft parts have been retained *in situ*. Bony periosteum consists of two layers, an outer, made up chiefly of white fibrous tissue, and an inner, of the same with few yellow elastic tissue fibres and capillaries in addition. In developing bone, osteoblasts—small, cubical, nucleated cells—are also present in this inner osteogenetic layer.

(d) Sharpey's perforating fibres are noticed in thin strips of decalcified bone near the surface. They thus run in from

the deep surface of the periosteum and pierce the peripheric lamellæ in a perpendicular or oblique direction. The fibrous bundles are of varying lengths, and taper gradually to their free extremities. They are fasciculi of fibrils, probably of white fibrous tissue; though it has recently been shown that many are perhaps elastic fibrils. When they do not become calcified they shrink and leave tubes in the channels in the dry bone. Sharpey also first demonstrated the presence of decussating transparent fibrils which constitute the main part of the lamellæ (see Fig. 176). In this way, in bone, Sharpey's discoveries include both perforating and decussating fibres, the former being bundles of fibrils, the latter an exceedingly delicate network of fibres. In dental histology Sharpey's fibres are the fibres which run from the periodontal membrane into the cementum; while his homologous fibres in dentine matrix were originally seen and described by von Ebner¹ and later by J. Howard Mummery.²

Turning now to the minute structure of several typical portions of the bones of the jaws, it will suffice to point out their distinguishing features.

(i) *Bone of Canine Fossa*

In vertical lateral sections of the bone of a young subject (age ten and a half years), it is found that the greater part of the tissue is composed of a dense osseous substance, but very scantily supplied with Haversian systems. Large areas of bone are quite devoid of either lamellæ, lacunæ, or canaliculi (Fig. 168). The matrix is distinctly coarsely granular (see Fig. 169), and has in it an indefinite number of short canals, the majority of which do not always communicate with lacunæ. These tiny tubular spaces, probably in the recent state, contain connective tissue fibrils, as they are too minute for the conveyance of blood-cells or even lymph. They are most marked and most numerous in the neighbourhood of the lacunæ, the canaliculi of which they somewhat resemble. Varying in

¹ "Handbuch der Zahnheilkunde," Vienna, 1890-91.

² *Philos. Trans. Royal Society of London*, 1891.

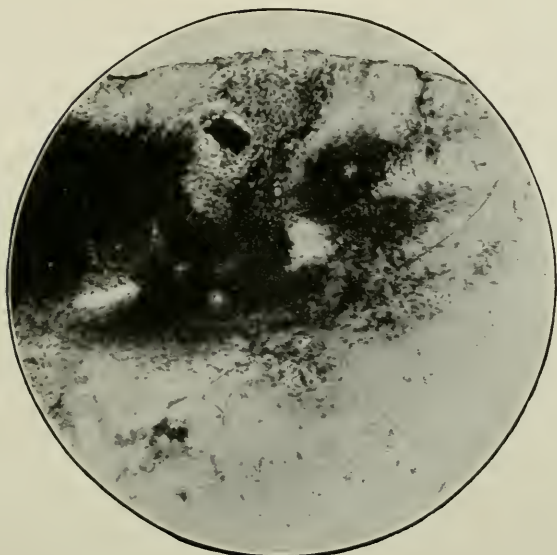


FIG. 168.—Vertical section of the bone of the canine fossa; from a dried specimen. Magnified 45 times. Unstained. Shows its general histological features. The dark masses are crowds of lacunæ, the lighter portions the ground substance.

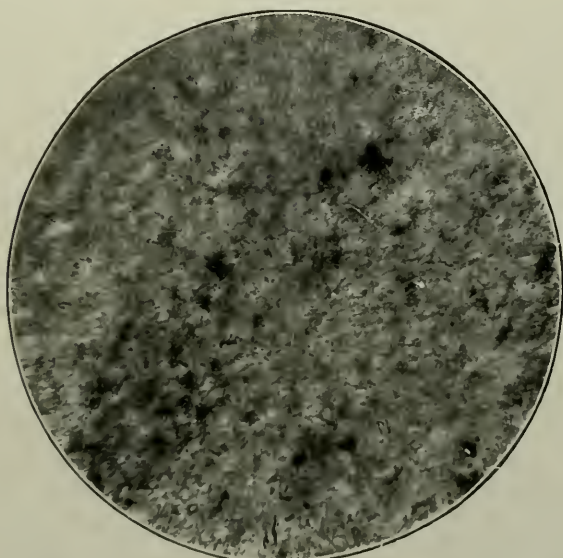


FIG. 169.—Granularity of the osseous matrix of the floor of the canine fossa. Magnified 750 times. Unstained.

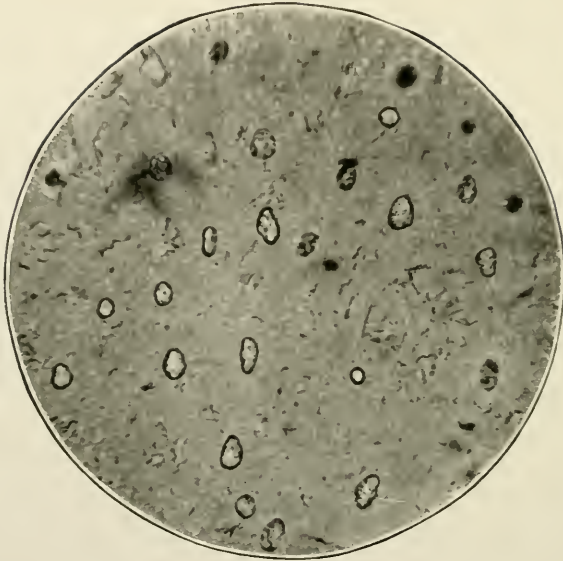


FIG. 170.—Abrachiate lacunæ from a dried specimen of the floor of the canine fossa. Magnified 750 times. Unstained. In the matrix a few short canals can be seen.

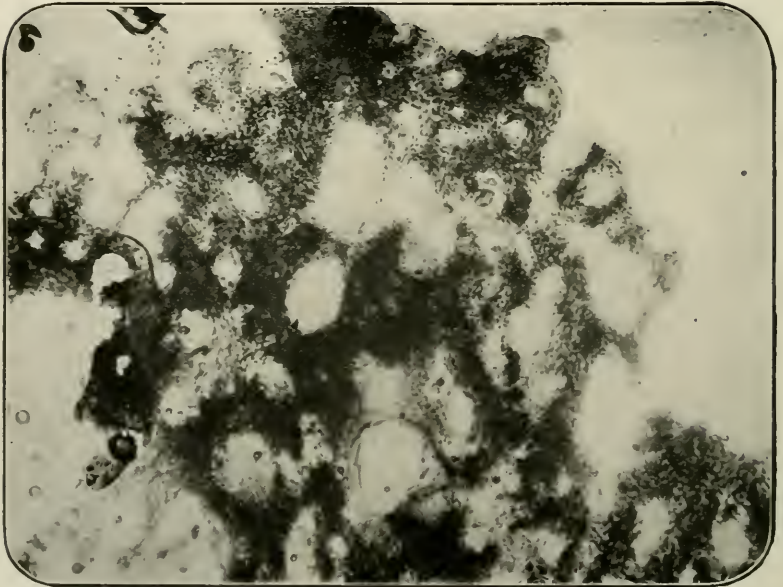


FIG. 171.—Vertical section of the bony septum between two maxillary premolars. Magnified 40 times. Unstained.

length, their diameter measures about 1μ . Several are shown in the photomicrograph Fig. 169.

The Haversian lamellæ, when they do occur, are but feebly marked. They do not present the usual microscopical characteristics of other bones, being very irregularly disposed in position and in shape, size, and constituents.

The lacunæ are massed together without order or regularity. Many are spherical in shape and absolutely unlike

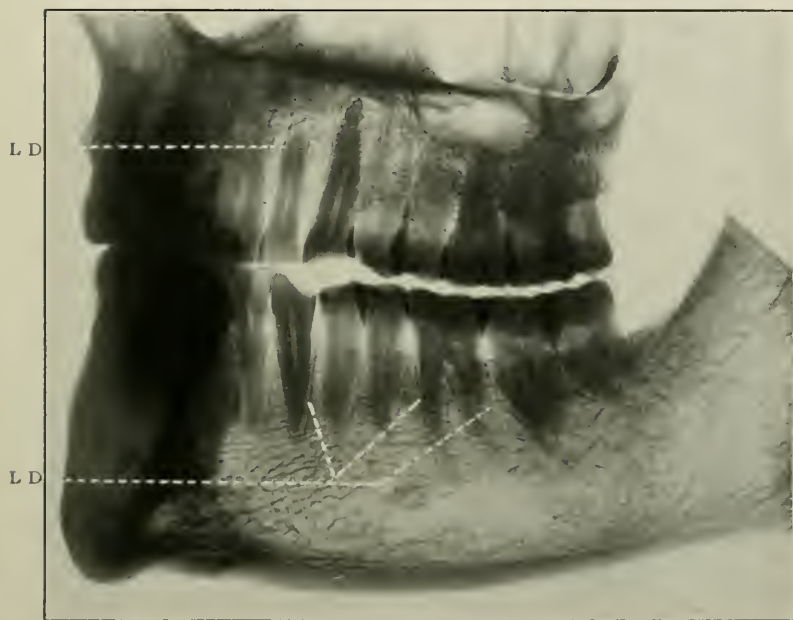


FIG. 172.—Radiograph of left side of normal jaws of man aged forty-five years, showing at L.D. the *lamina dura*. A certain amount of absorption of the terminal margins of the alveolar processes has, here and there, occurred.

those of well-constructed compact bone, the majority being provided with short coarse offshoots, though great numbers are quite abrachiate. This last fact is of great interest, and probably has also some pathological significance. These lacunæ, as is well shown in Fig. 171, do not possess, and they probably never did possess, canaliculi; their outlines are sharply defined rounded or oval contours, and under low magnifications rather simulate dentinal tubes cut transversely.

In addition to the granular matrix, the substance of the bone, thin though it is, contains numbers of broad channels of great length, which may perhaps, during life, act as venous carriers of the blood or give passage to lymphatic vessels. Possessing no histological or physiological interest, they occur sufficiently commonly in this situation to warrant merely a passing reference.

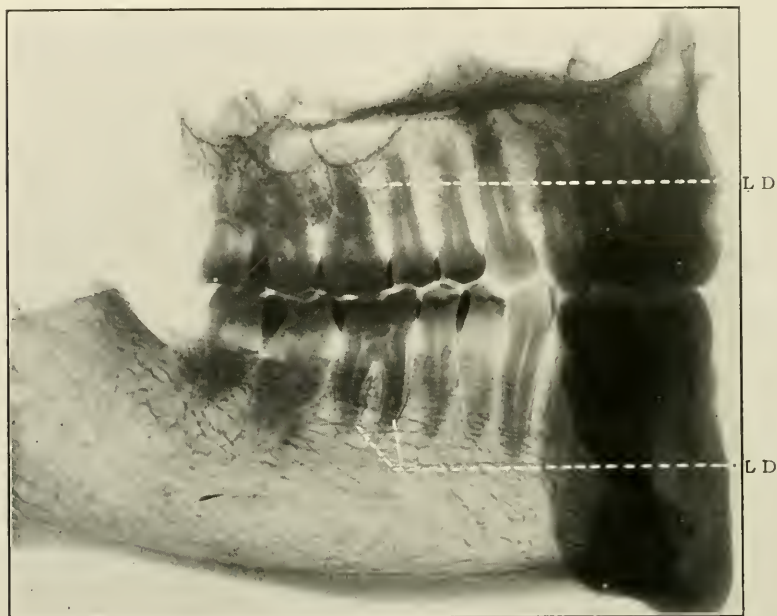


FIG. 173.—Radiograph of right side of jaws of man aged forty-five years, showing at L.D. the *lamina dura*.

(ii) *The Interdental Septa*

These are composed of cancellated bone the lattice-like character of which differs in no material degree from spongy bone elsewhere. The lamellæ are arranged, as a rule, in lines parallel to the edges of the large openings in the bone. The lacunæ are very numerous; a few are abrachiate, but by far the greater number possess canaliculi (Fig. 171).

Thin sheets of compact bone exist normally immediately outside the periodontal membranes of the teeth. These are

called *Lamina dura*. Good radiographs show them in a marked degree, see Figs. 172 and 173.

In the recent state, the large open spaces in the bone are filled with quantities of red medullary tissue, viz.—delicate branching, retiform tissue supporting the marrow cells of Kölliker, and small coloured nucleated cells many of which undergo sub-division by mitosis.

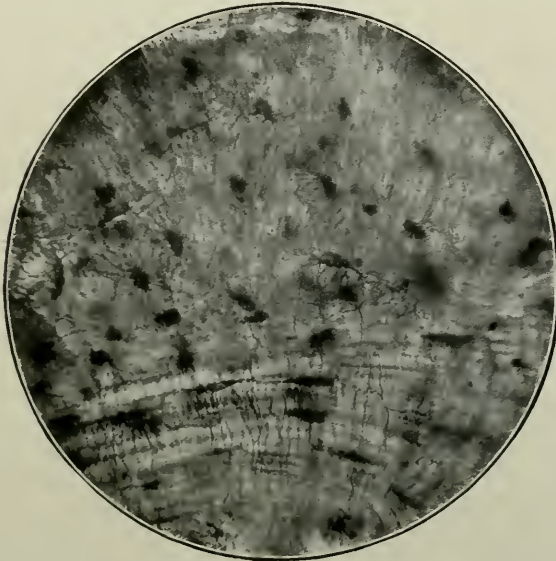


FIG. 174.—Sagittal section of the substance of the hard palate. Magnified 250 times. Unstained. The photograph exhibits the fusiform shape of the lacunæ in the lamellæ, and the rounder spaces elsewhere; also the connective tissue stroma of the matrix.

(iii) *Hard Palate*

Vertical antero-posterior sections of the roof of the mouth at the articulation of the palatal process of the maxillary with the horizontal plate of the palate bones, near the sutural line, all reveal the characteristics of dense osseous tissue thickly crowded with lacunæ and canaliculi (Fig. 174), and also several longitudinal spaces of large dimensions filled with marrow. The long axes of the lacunæ are more or less parallel to the long axes of the cancelli.

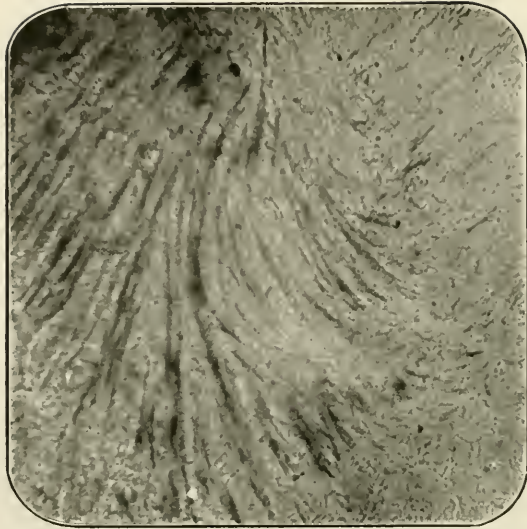


FIG. 175.—Radiating connective tissue fibres in the matrix of the bone of the wall of the maxillary sinus. Magnified 250 times. Unstained.




FIG. 176.—Perforating fibres running lengthwise through the matrix of the bony wall of the maxillary sinus. Magnified 800 times. Unstained. The cut extremities of descussating fibres appear as white, round dots.

(iv) *Nasal Wall of Antrum of Highmore*

Here, as in the bone which constitutes the floor of the canine fossa, the matrix is very coarsely granular, and contains in places long markings, which are evidently the remains of the connective tissue stroma (Figs. 175 and 176). The lacunæ, which are exceedingly scanty, do not present the usual characteristics, being spherical or oval when viewed from above (Fig. 177). Some are concavo-convex as seen in side section. Again, the canaliculi are but very indifferently formed.

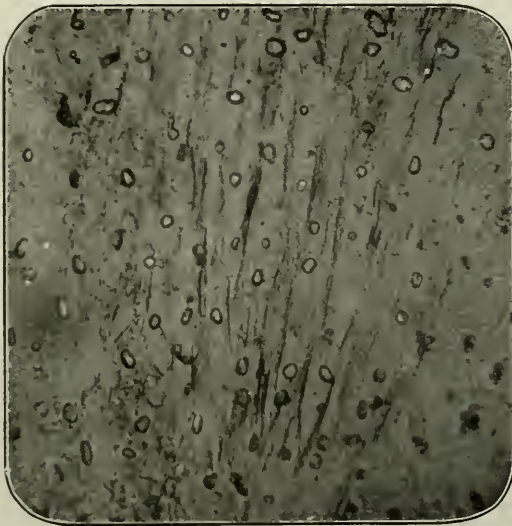


FIG. 177.—Abrachiate lacunæ amongst perforating fibres. Bone of antral wall. Magnified 250 times. Unstained.

(v) *Angle of Mandible*

Examination of the structure of vertical transverse sections exhibits, best of all, the pervious parts of the bones,—the regular disposition of the Haversian systems, and the peripheric and interstitial lamellæ. The first are not very numerous, and are seen mainly in cross section. The peripheric lamellæ are comparatively long, and the line of demarcation between the individual lamellæ very marked (Fig. 178). Strong lines of calcified connective tissue fibres can be observed, here and there, closely welding together the interstitial lamellæ




FIG. 178.—Vertical section of the angle of the mandible; from a dried specimen. Magnified 50 times. Unstained. The section shows the general structure. At the upper part of the figure the long peripheric lamellæ are seen at the free edge of the bone, with interstitial lamellæ between the Haversian systems. At the lower part of the figure the commencement of the cancellous diploë-like portion is separated from the external surface by the dense layer of dark compact bone.

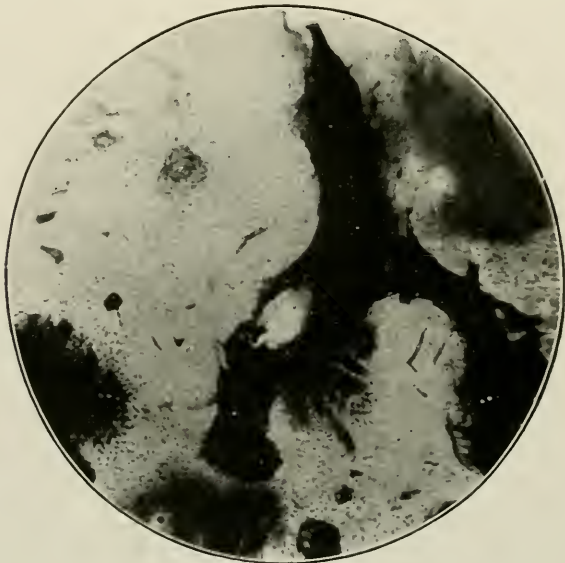


FIG. 179.—General structure of the bone of the alveolus; from a recent specimen. The cancellous spaces and contents are too darkly stained to show any structure. Magnified 40 times. Stained with fuchsin.

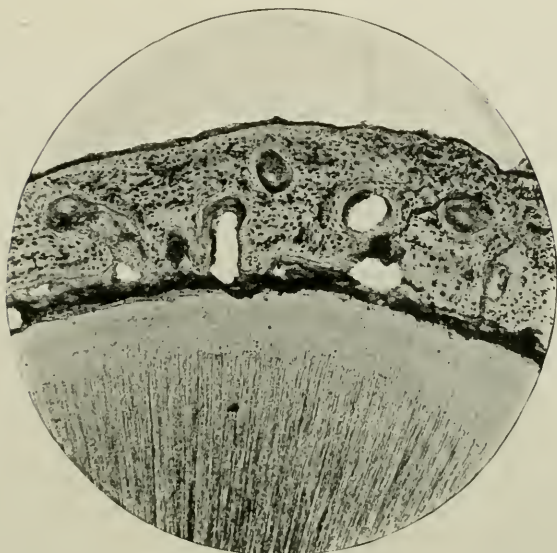


FIG. 180.—Transverse section of the alveolus *in situ*; from a dried specimen. Magnified 40 times. Stained with borax-carmin. In the upper part of the photograph is the free edge; below, the dentine and cementum, with the periodontal membrane intervening.

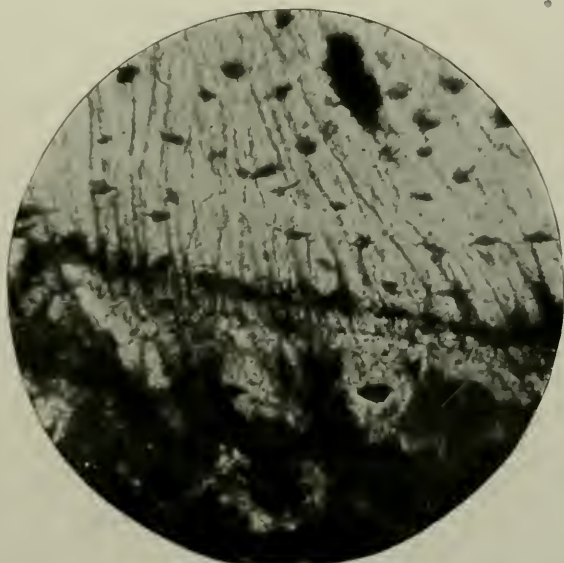


FIG. 181.—Perforating fibres of the alveolus, passing into the periodontal membrane. Magnified 800 times. Unstained.

even in bones of adult life (age thirty-five years). Internal to the free surface of the jaw, the cancellated tissue follows very much the lines already laid down.

Vertical lateral preparations of the same, show absence of Haversian systems, but multitudes of lacunæ and canaliculi, and many radiating bands of calcified fibres.

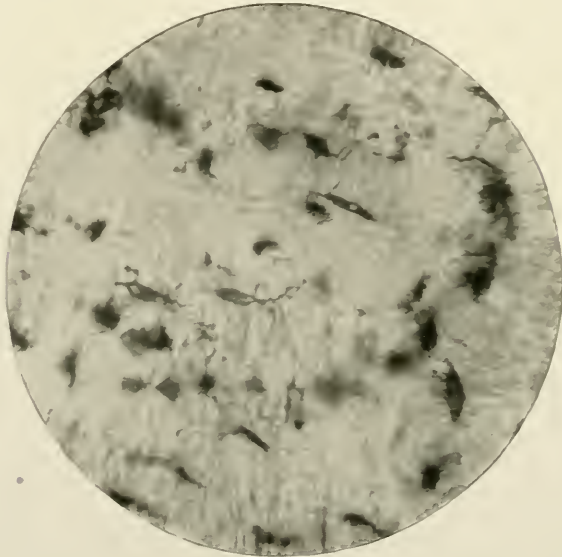


FIG. 182.—Lacunæ and canaliculi in the bone of the alveolar process. Magnified 250 times. Unstained.

(vi) *Alveolar Process*

Here are found all the appearances of soft cancellous bone, with Haversian systems and lacunæ well marked (Figs. 179 and 182). The cancelli run longitudinally in the same direction as the long axes of the teeth. Osseous tissue is dense externally (see Fig. 180); and the perforating fibres are very strong and of great length (Fig. 181).

The foregoing remarks refer to the greater portion of the bony structures. At the free gingival terminations, however, the alveolar process is so narrow, that there is no room to accommodate medullary spaces and Haversian systems. These are, therefore, usually non-existent. The external alveolar plate is considerably thinner than the internal alveolar plate: in neither, does the bone exhibit a typical appearance.

CHAPTER XI

A GROUP OF MINOR STRUCTURES. THE ABSORBENT ORGAN—THE DENTAL CAPSULE—THE GUM—THE LINING MEMBRANE OF THE ANTRUM OF HIGHMORE

THE ABSORBENT ORGAN

MICROSCOPICAL ELEMENTS:—(i) Connective tissue stroma; (ii) Osteoblasts; (iii) Foveolæ of Howship.

GENERAL CHARACTERISTICS

Definition.—A delicate vascular structure spread over portions of the roots of the deciduous teeth of man, during the periods when they are about to be shed.

Origin.—From the outer layer of the dental capsule of the permanent teeth.

Macroscopical Appearances.—A thin, white, insensitive organ covering the excavated parts of the roots of deciduous teeth loosened by the impending eruption of their permanent successors. It can be easily removed from the dentine, but is best observed and studied when retained *in situ*. It may also be seen as a soft reddish papilla over the crowns of the erupting permanent teeth.

HISTOLOGY

Vertical sections exhibit a tissue composed of cells and blood-vessels imbedded in a dense connective tissue stroma.

The cells are usually small and round, with round or oval prominent nuclei. On the surface, and filling the foveolæ of Howship—large bay-like crescentic excavations in the dentine

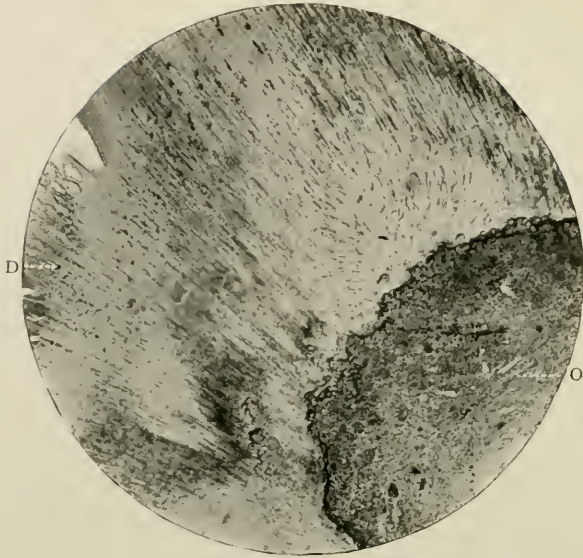

FIG. 183.—The absorbent organ. Prepared by the Author's process. Stained with Ehrlich's acid hæmatoxylene. Magnified 40 times. O. Absorbent organ; D. Dentine of the deciduous tooth.

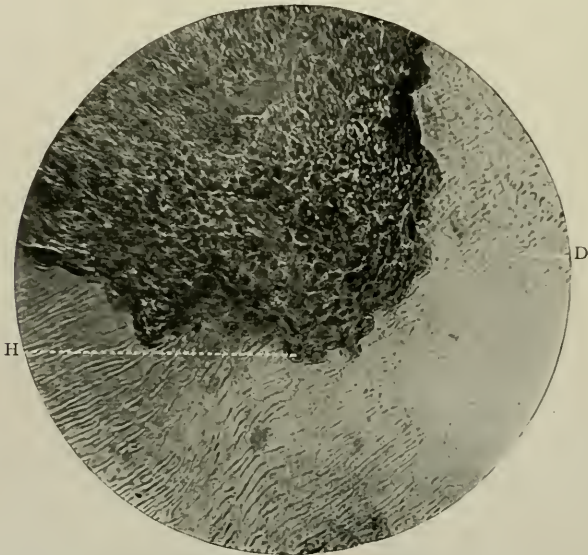


FIG. 184.—Same as the preceding. Magnified 250 times. H. A Howship's foveola with its giant-celled occupant; D. Dentine of the deciduous molar.

—are found large multi-nucleated giant cells which correspond in many particulars with osteoclasts. In fact, they may be considered to be nothing more nor less than these specially organised cells. The cells which make up the main mass of the organ are of the ordinary variety. They are not osteoblasts, in the general acceptance of the term, but may take on a lime-depositing function, as sometimes there are evidences in physiologically absorbed roots of new depositions of dentinal matrix.

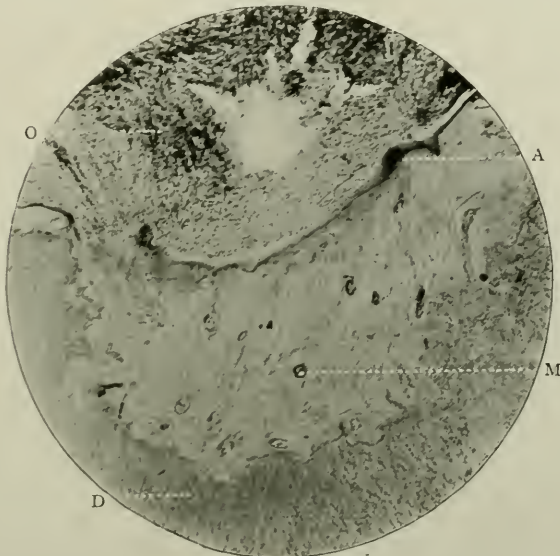


FIG. 185.—The absorbent organ *in situ*. Prepared and stained as in Fig. 153. Shows a deposition of dentine matrix (with a few scattered cells embedded in it) in the excavated portions of the dentine. Magnified 50 times. O. Absorbent organ; D. Dentine of deciduous tooth; M. Dentine matrix containing nucleated cells; A. Albumenoid material undergoing calcification.

In the two accompanying photomicrographs, Figs. 186 and 187, it will be seen that a kind of hyaline matrix has been laid down, in the excavated portions of the roots of the deciduous teeth. This nearly homogeneous material may at times present nothing more than a coarse granularity, or, at times, show a finely fibrillated reticulum with large round nucleated connective tissue cells imbedded in its midst. Both forms closely recall those two kinds of adventitious dentine found in the pulp known as hyaline, and cellular (*q.v.*). Here, again,

is another remarkable instance of dentinal matrix being produced without the aid of the so-called odontoblasts.

The vessels are very numerous, but comparatively large nerves other than vaso-motor branches are probably absent.

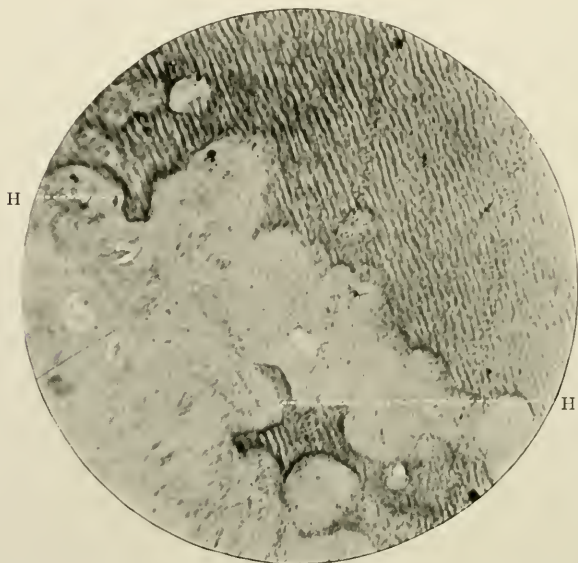


FIG. 186.—A similar section to the preceding. Prepared and stained as in Fig 184. Magnified 250 times. H. The foveolæ of Howship filled with calcified dentinal matrix.

THE DENTAL CAPSULE

MICROSCOPICAL ELEMENTS:— (i) Outer and Inner Portions; (ii) Fibres; (iii) Glands.

GENERAL CHARACTERISTICS

Definition.—A sac-like investment of fibrous tissue of the non-erupted teeth of man, and many animals, which disappears after histogenetic periods have passed.

Origin.—From the mesodermic cells of the outer portion of the dentinal papilla.

Macroscopical Appearances.—A rather tough, pale membrane easily stripped off the surface of teeth which have not yet arrived at the proper time for eruption. The author has been

unable to find another organ in the body which is its counterpart. It exists for a few years only, and when its work—that of protecting the crown of the erupting tooth, after being instrumental in generating the cementum and periodontal membrane—is accomplished, it disappears entirely, completely differing from such organs as the uterine adnexa, which persist after the cessation of their functions, and even the thymus gland, which, as a rule, leaves traces behind. It can be fairly claimed for the




FIG. 187.—Degeneration and vacuolation of the dental capsule prior to its disappearance.

dental capsule that in this respect it is unique. Regarded from an embryological aspect, the dental capsule, *e.g.*, of the first premolar, may be observed in certain portions of the oral submucous and alveolar tissues about the ninetieth day of intra-uterine life in man, and can be well demonstrated in sagittal sections of the jaws of kittens three weeks old. The cells are very elongated and thin, with small lenticular nuclei, chiefly arranged in longitudinal bundles corresponding to the long axis of the tooth germ. Later on they become developed into the

extended fusiform cells of fibrous connective tissue. Eventually the capsule undergoes atrophy and degeneration by the loss of the nuclei of its cells and vacuolation of its substance, in this specific instance, about the seventh to the ninth year in man. This vacuolation, it is important to notice, occurs as a normal

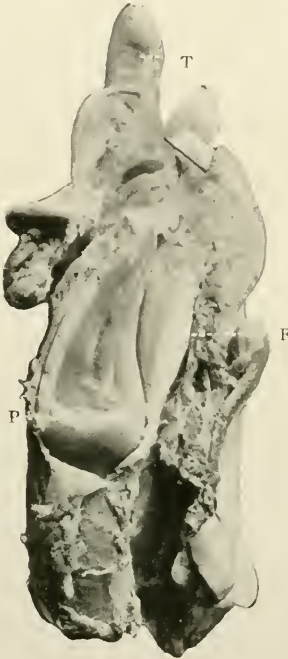

FIG. 188.—Sagittal section in the incisor and canine regions of mandible of a young heifer. Prepared by cutting through the jaw with a saw while in the recent state. Actual size. Shows (P) the permanent tooth in its (F) capsule; T. Functional deciduous incisor.

change in the capsules of teeth about to erupt, of course just prior to their disappearance; but when a tooth is retained *in situ* in the bone, it does not follow that it undergoes this vacuolation.

HISTOLOGY

It is composed of bundles of white connective tissue fibres, running in a complex and varied fashion and interlacing in all directions. The cellular elements, as well as the vascular

supply, are scanty. The outer portion is less dense than the inner, but it cannot be removed as a separate layer from the latter, as neither is divided by a pronounced line of demarcation. The inner is dense, and is covered on its free surface, *i.e.*, the part directed towards the enamel and cementum with a flat layer of epithelial cells, which are manifestly part of the layer of polygonal cells of Nasmyth's membrane.

Running inwards towards this cellular layer groups of tube-like epithelial bodies wind between the fibres. They are

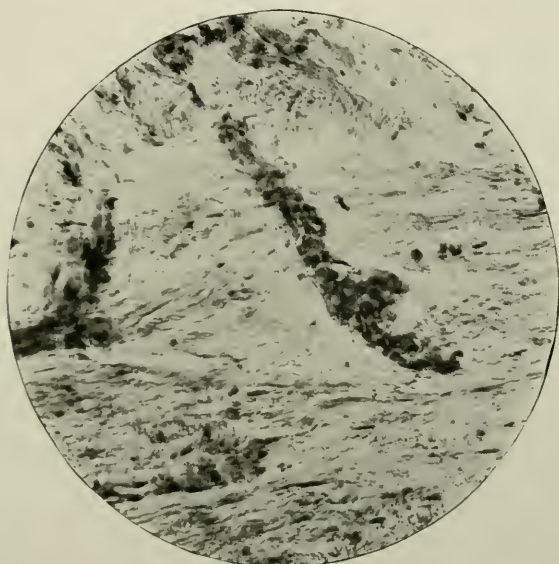


FIG. 189.—A tubular gland-like structure from the dental capsule of man. Prepared by "fixing," hardening, and cutting on an ether-freezing microtome. Stained with Ehrlich's acid hæmatoxylene. Magnified 250 times.

simple in construction, though sometimes they may branch. They have no definite lumina; but the epithelial cells which line the basement membrane are cubical in shape and have large prominent nuclei. They end in *culs-de-sac*. Their function is unknown, and their origin doubtful, although it is quite possible that they may be derived originally from "rests" or vestigial remnants of the unatrophied epithelium of the tooth-band.

THE GUM

MICROSCOPICAL ELEMENTS:—(i) Epithelium of the mucous membrane; (ii) Simple and compound papillæ; (iii) Mucous glands; (iv) Fat lobules; (v) Blood-vessels; (vi) "Glands" of Serres.

GENERAL CHARACTERISTICS

Definition.—The soft dense tissue which clothes the alveolar processes of the jaws, being intimately connected with their periosteum, and surrounding the necks of the teeth.

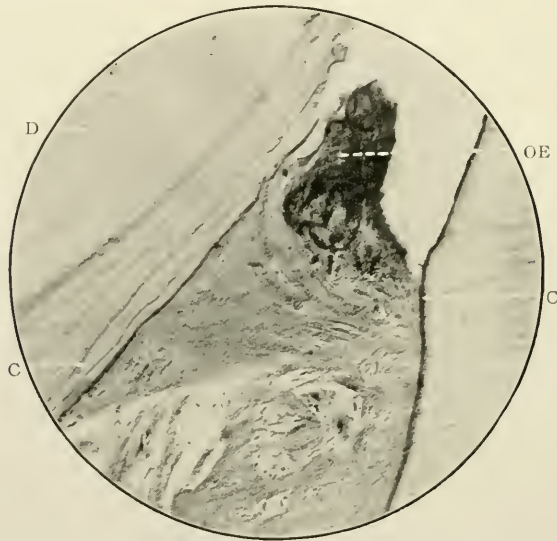


FIG. 190.—The margins of the gingival tissue in an interdental space. Magnified 200 times. Stained with hæmatoxyline. o.e. Oral epithelium of the gingival tissue; d. and c. Dentine and cementum of two contiguous teeth, that on the left being hyperplastic.

Origin.—The superficial epithelial portion is derived from the stomodæal ectoderm, the submucous tissue from the stomodæal mesoderm, both due to the backward involution of these parts of the blastoderm between the maxillary and mandibular processes of the head.

This involution deepens and extends further backwards, till a thin partition only intervenes between it and the cæcal extremity of the fore-gut. On the absorption of this, connection with the pharyngeal cavity is permanently established.

Macroscopical Appearances.—The gum is a smooth, firm, pale pink tissue round the necks of the teeth, continuous externally with the sulci between the lips and cheeks, and internally with the hard and soft palates, floor of mouth and root and sides of tongue. The gum envelops the arches of the osseous septa between the teeth in much the same way, but not to so great an extent as over the external and alveolar plates (see Figs. 191 to 194). In normal conditions there are no interdental papillæ.

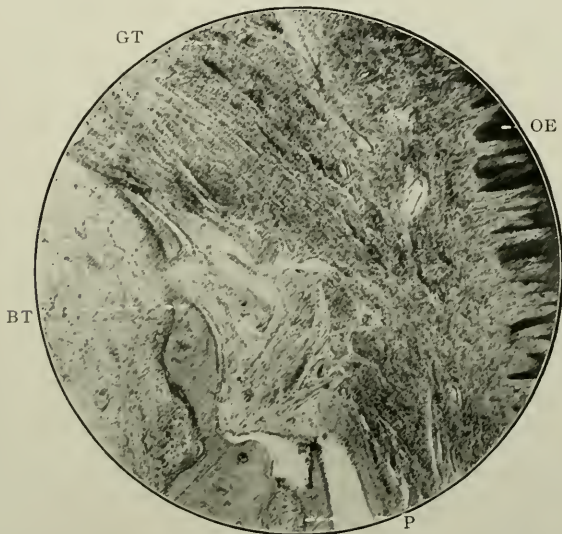


FIG. 191.—Gingival tissue covering an interdental septum of bone, showing oral epithelium, and character of sub-epithelial parts. Magnified 200 times. Stained with hæmatoxyline. O.E. Oral epithelium; G.T. Gingival tissue; B.T. Free termination of alveolar bone; P. Periosteum.

HISTOLOGY

The minute anatomy of the gum may be conveniently considered under the following heads: (A) The mucous membrane; (B) The submucous tissue.

A

The mucous membrane, about 0.3 mm. thick, is essentially of a stratified epithelial character, consisting as it does of

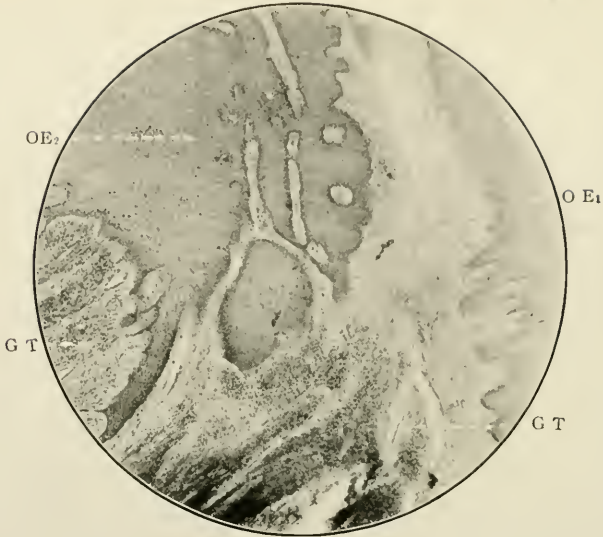


FIG. 192.—Another portion of the gingival tissues covering an interdental septum of bone. Magnified 200 times. Stained with hæmatoxylene. o.E₁. Normal oral epithelium; o.E₂. Deeper and more abundant oral epithelium; g.t. Normal gingival tissue.

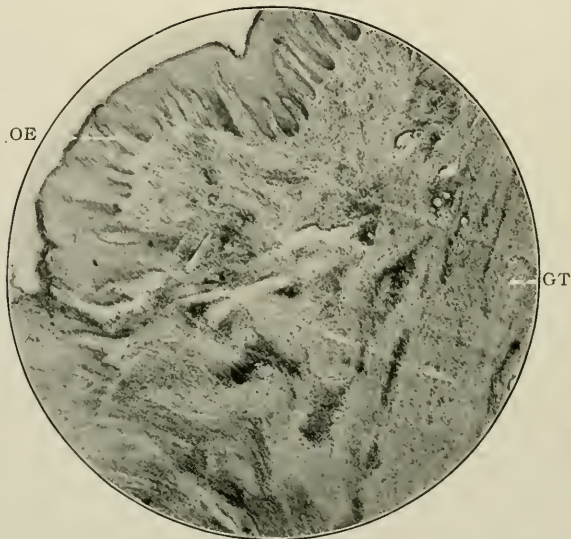

FIG. 193.—Gingival tissues covering another interdental septum of bone. Magnified 200 times. Stained with hæmatoxylene. o.E. Thin layer of stratified squamous epithelium; g.t. Normal gingival tissue.

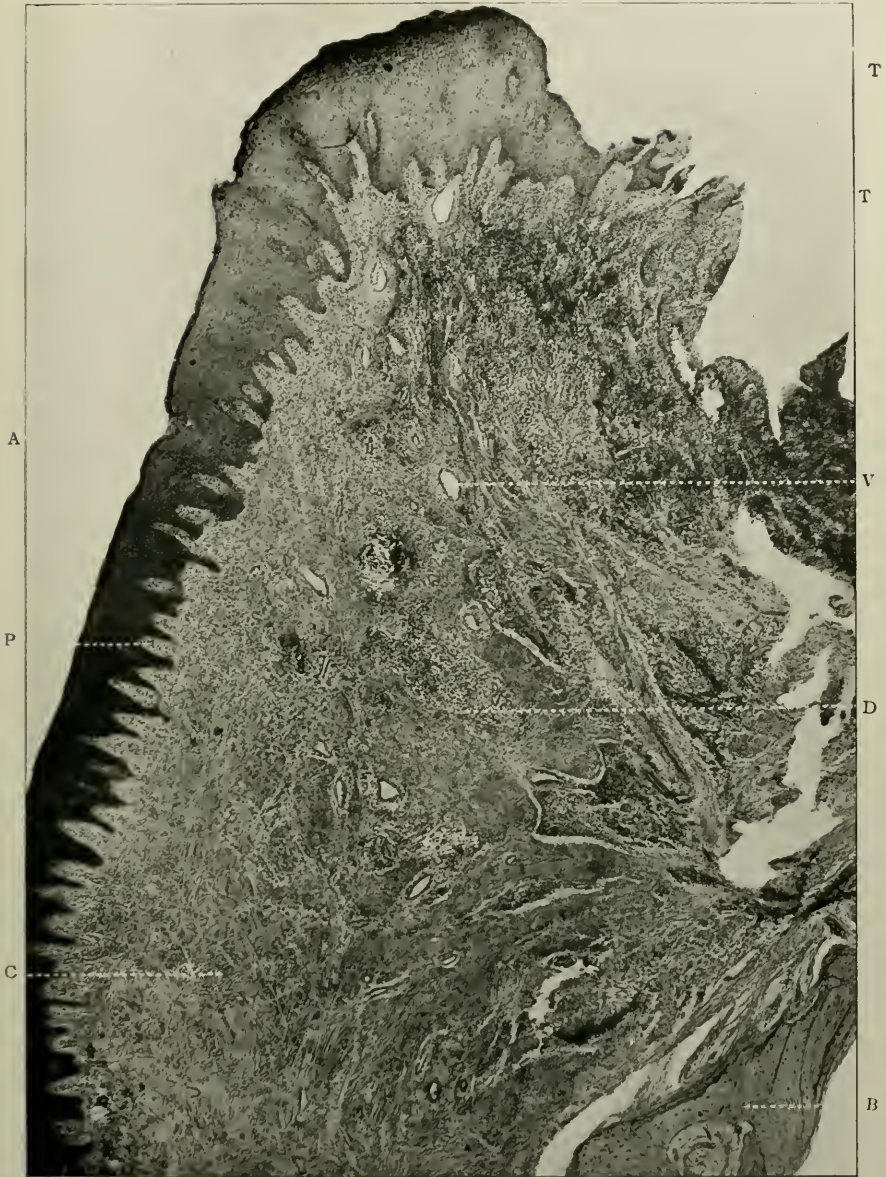


FIG. 194.—Vertical section of the gum. Prepared similarly to Fig. 193. Stained with Ehrlich's acid haematoxyline. Magnified 50 times. A. Oral epithelium; P. Papilla of the submucous tissue; C. Connective tissue fibres interlacing in all directions; D. Scanty cellular elements; V. Blood-vessel; T. T. Parts of the section bordering the gingival trough, torn in cutting; B. Alveolar bone.

several layers. On the surface are large, stratified, squamous epithelial cells which overlap each other to some extent. Deeper, they become more cubical in shape, but the deepest of all are columnar in outline, and form the *rete Malpighii*, resting on an exceedingly thin basement membrane. In the lower layers the shape of the cells is modified by their mutual apposition. They fit each other very closely. The epithelium of the gum can be divided into the layers known as the *stratum corneum*,

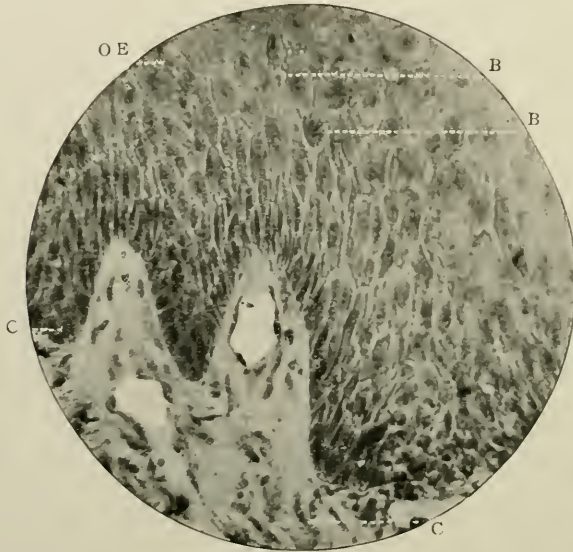


FIG. 195.—Vertical section of the oral epithelium. Stained with Ehrlich's acid hæmatoxylene. Magnified 250 times. O.E. Epithelium of gum (oldest cells); B.B. Intercellular bridges of the "spiny" cells; R. Rete Malpighii; C. Corium.

stratum lucidum, and *stratum granulosum*, as in the epidermis, and possibly there is eleiden or granular material deposited in the older, more superficial cells.

The deeper cells are more protoplasmic than the others, undergo repeated karyokinesis, and gradually push outwards the latter, which ultimately become lost by abrasion.

Many "spiny cells," separated by systems of wide intercellular channels, are often noticed in the layers nearest to the *rete mucosum* or *Malpighii*.

This last named consists of a very folded line of columnar cells, placed vertically on the surface of the papillæ, which are formed by the submucous tissue.

The epithelial mucous membrane is perforated here and there to allow the passage of the ducts of many mucous glands, which are present in the sub-lying region.

The gingival trough extends to a depth of 2.5 to 4 mm. in different situations, and always contains, even in the healthiest of mouths, microorganisms of the *Micrococcus Catarrhalis*, and *Streptococcus pyogenes* groups. It is bounded internally by the enamel, externally by the stratified squamous epithelium of the gingival tissues.

B

The sub-mucous tissue consists of dense bundles of connective tissue arranged throughout its substance. These are closely associated with the fibres of the alveolar periosteum, and at the necks of the teeth, with the "principal" fibres of the alveolo-dental periosteum. They pass outwards in fan-shaped fasciculi to the surface of the numerous papillæ.

The latter are large elevations of the sub-mucous fibrous tissue. They form the base on which the cells of the *rete mucosum* rest, and between them are depressions which vary indefinitely in size and shape. A simple papilla consists of one large mound or elevation of vascular fibrous tissue, the term "compound" being applied to those larger ridges, which are further sub-divided by smaller ones passing in from without. The papillæ are visible to the naked eye, if, after removal of the epithelium by means of some dissociating fluid, the free surface of the gum be examined.

Among the connective tissue fibres plasma cells are frequently seen. These are large cells with round, eccentrically placed nuclei whose chromatin stains intensely. Their cytoplasm is dense and stains deeply. Occasionally they contain vacuoles, which when filled with semi-fluid substances are recognised as Russell's fuchsine bodies. Mast cells and leucocytes are often, also, found.

Other constituents of the sub-epithelial tissue are:—

(i) Small lobules of fat cells—tiny oval vesicles (each cell being about 70μ in diameter)—of adipose material gathered together into clusters, and imbedded in a fine reticulum of areolar connective tissue; (ii) Mucous glands, similar to those described on page 189; (iii) Blood-vessels, which are abundantly distributed; (iv) Scanty nerve fasciculi; and (v) the so-called “glands” of Serres.

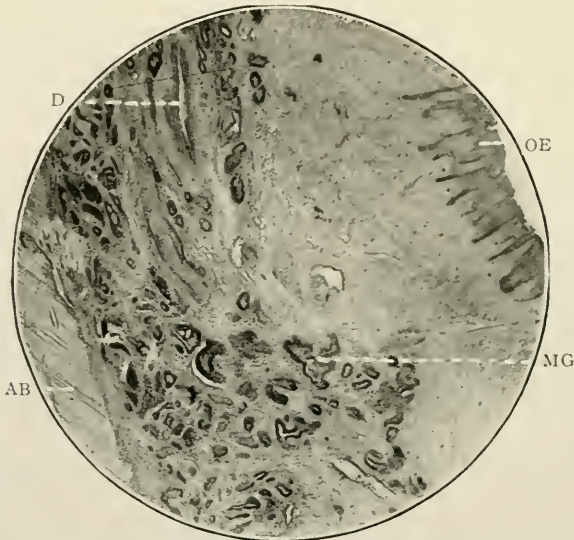


FIG. 196.—Gingival tissue covering the internal alveolar plate of the incisor region of a woman of 25 years. Normal. Magnified 200 times. Stained with hæmatoxyline and eosine. O.E. Stratified squamous epithelium; A.B. Bone of the internal alveolar plate; M.G. Mucous gland; D. Duct of mucous gland.

There are large mucous glands in the gum at the cervical margins of the teeth on the *lingual* or *palatal* side, none in that on the *labio-buccal* aspect of the alveolar process. The author experimentally proved this by excising a portion of normal gum immediately in contact with the teeth, on the outer side of the alveolar process of the mandible of a man, aged about forty-four, and chose a spot between the two right premolars. It measured 6.5 mm. in length. There was no mucous gland to be seen. Similarly none was present in the gum on the *labial* aspect of the bone over the root of the second left maxillary

incisor of a woman aged twenty-five. Again, in a piece of the tissue, over the septum which intervenes between two mandibular molars, no mucous gland was found. The reason is obvious. Mucous glands are not wanted in the former situation, because of the existence of countless numbers which open on the free surfaces of the lips and cheeks and in the latter situation because of lack of room.

The "glands" of Serres (see Figs. 251 and 253), according to Tomes (*op. cit.* p. 126), are "small round aggregations of pavement epithelium, met with at a little depth, or even imbedded in the surface." These have no known function, but are remnants of the dental lamina or tooth-band. Bland-Sutton and R. R. Andrews¹ consider them to be histologically comparable to young enamel organs; but Sayre Marshall² erroneously describes them as lobulated glandular structures.

THE MUCOSA OF THE ANTRUM OF HIGHMORE

MICROSCOPICAL ELEMENTS:—(i) Epithelium; (ii) Submucous Tissue; (iii) Glands.

GENERAL CHARACTERISTICS

The histology of this tissue seems to have escaped the notice of workers, who, generally speaking, have contented themselves by saying that it is continuous with, and similar to the Schneiderian mucous membrane of the nose.

A knowledge of its minute structure is important because of its intimacy with the roots of the first and second maxillary molars, or premolars, and the fact that treatment of its diseased conditions not infrequently comes into the province of the work of the dental surgeon.

Regarding its anatomy, Sappey³ describes it as being supplied

¹ "American Text-Book of Operative Dentistry," p. 90, 1901.

² "Principles and Practices of Operative Dentistry," p. 58, 1901.

³ "Quant au sinus maxillaire, elles (the glands) répandent sur tous les points de ses parois avec une telle profusion, qu'il serait fort difficile d'en faire le dénombrement. . . . Ces glandes affectent, du reste, toutes les dimensions et toutes les formes possibles: il y en a de très considérables et de très compliqués, de moyennes, et plus simples, de petites, de très minimes, et enfin d'uni-utricular. Les unes revêtent la forme arrondie, d'autres la forme rameuse, d'autres les formes intermédiaires. Elles sont surtout remarquables par la dilatation extrêmement fréquente de leur conduit, en sorte que sur un grand nombre, d'entre elles il existe un kyste, naissant, ou ayant déjà acquis une certaine développement ou complètement développé."—"Traité d'Anatomie," Vol. III., Paris, p. 660, 1871.

with glands, which, in appearance, are much like the Meibomian glands of the eyelids. They are irregularly distributed, and much scantier than those of other mucous membranes.

Definition.—The lining membrane of the maxillary sinus, otherwise called the antrum of Highmore.

Origin.—It is an outward involution of the ectoderm of the olfactory fossæ, which themselves originate at a point below and in front of the ocular vesicle. It is said that it begins to develop about the fourth month of intra-uterine life.

Macroscopical Appearances.—A thin whitish tough membrane, very readily removed from the bone, and in places thrown into slight rugæ. In old subjects (*æt.* 64) patches of pinkish material (inspissated mucus) may be seen. The thinness is not uniform, in health, large territories may be found somewhat thicker than the rest. It is also slightly thicker over the situations of the glands.

It measures 0.7 mm. to 0.9 mm. in thickness. The whiteness is due to lack of blood supply, which is particularly scanty. The vessels come from the anterior and posterior ethmoidal branches of the orbital group of the ophthalmic artery. Bödecker, in this connection, says (*op. cit.*) “The blood-vessels are principally derived from the mucous membrane of the nasal cavity, although some of the smaller branches arise from the posterior dental arteries through the alveoli.”

Its toughness depends upon the large amount of white connective tissue fibres which go to make up the greater proportion of its bulk. Sections curl up very readily, and large pieces can be torn off the thin bony walls to which it is but loosely attached by fibrous tissue.

HISTOLOGY

The lining membrane presents for microscopical examination—(i) An epithelial surface, (ii) sub-epithelial tissue, (iii) certain glandular structures, and (iv) its periosteal attachment.

(i) *The Surface Epithelium*

In common with the mucous membrane of the respiratory passages (except that of the olfactory region of the nose), the

upper surface of the soft palate, the nasal region of the pharynx, and several other organs of the body, the epithelium of the antral mucosa consists of a transitional layer of ciliated columnar epithelial cells, situated side by side, and on and between several layers of variously shaped cells, the lowest stratum of which is placed on a delicate basement membrane. This covers the whole of the mucous membrane.

The layer of epithelium measures about 0.02 mm. in depth in young subjects (*æt.* 25).

Each superficial cell is granular, narrow, more or less columnar in shape, and bears, at its free end, a number of long cilia, which are securely fixed to the surface of a clear disc. The attached basal extremity of the cell is generally pointed or dichotomous.

The intervening and deep-lying cells are pyriform or polyhedral, thus called, by some authors, "battledore cells," whilst the deepest cells are spherical. All have very pronounced oval nuclei, which in the case of the first-named is situated near the refractile disc.

Some authors consider that the younger spherical cells finally replace those possessing cilia; but probably this is not true, as they appear to contain mucigen, and to become ultimately distended into the shape of goblet-cells.

At intervals numerous goblet or chalice cells may be observed between their ciliated neighbours.

These are large poculiform bodies, with wide open mouths, which are directed inwards towards the centre of the antrum. Each contains mucigen and an indistinct small nucleus placed at its distal end. The mucus may entirely or only partially fill it; but sometimes it can be observed in sections, becoming extruded from the mouth of the cell.

(ii) *The Sub-Epithelial Tissue*

is very loose, and sparsely supplied with cells and blood-vessels, though glands are fairly abundant. It is made up of bundles of white connective tissues fibres, which, while in no sense compactly arranged, are still very tough. The author has

never noticed the presence of any elastic tissue fibres in this membrane.

(iii) *The Glands*

are of great interest. They are visible macroscopically in suitably stained specimens, as pin-point spots more deeply coloured than the rest of the tissue. Seen in sections cut in a

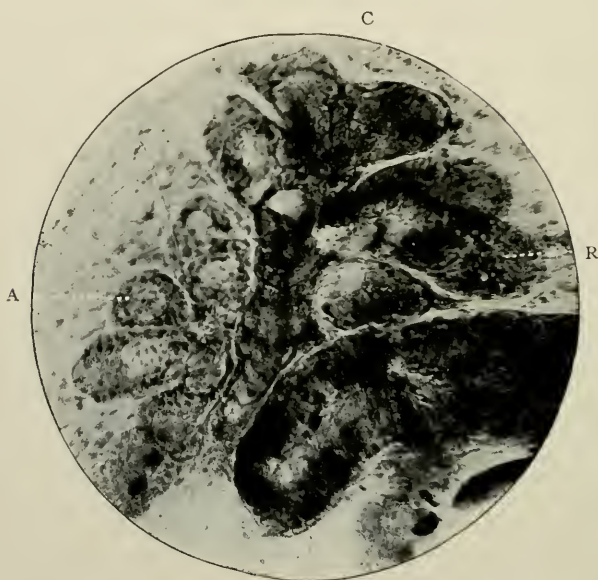


FIG. 197.—A mucous gland of the lining membrane of the antrum of Highmore. Stained with Ehrlich's acid hæmatoxyline, counter-stained with eosine. Magnified 250 times. A. Mucous secreting cells in activity; R. The same after the period of activity is passed; C. Crescent of Gianuzzi.

plane perpendicular to the surface of the bone of the antrum, they present the appearance of tubular glands; and this, no doubt, led Sappey to assert that they resemble the Meibomian glands in the eyelids. Such, however, is not the case, for if sections be made in an oblique direction, or in a plane parallel with the surface of the antral bone, below the level of the epithelial layers, they are at once recognised as compound racemose bodies, consisting of well-defined lobules, and having single ducts, which open on to the free surface of the mucous membrane.

The largest glands measure in length 0.8 mm. to 1.3 mm., and 0.2 mm. to 0.6 mm. in depth. The lobules assume varying shapes (see Fig. 197), and are held together by delicate strands of connective tissue. Each lobule possesses a small duct, which communicates with a larger excretory duct, and its constituent parts are composed of a number of alveoli or acini. Glands during rest, and after a period of activity, are clearly observed.

These latter consist of a basement membrane, on which rest, by means of their broad bases, five or six, or more, large polygonal secretory cells. Others often fill the acini, leaving but little room for lumina. Their translucent interiors are traversed by an exceedingly minute reticulum of fibrils,

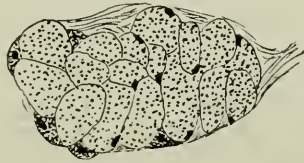


FIG. 198.—Diagram of Fig. 197 shows the secreting mucous cells about to begin their functions. Several crescents of Gianuzzi can be seen.

which includes in its meshes mucigen, small indifferent flattened nuclei being placed at the periphery of each cell. The crescents or lunulae of Gianuzzi—groups of small crescentic granular nucleated bodies—may be found occasionally in places between the bases of the cells, more darkly stained than the other parts of the acini.

The ducts are short, straight tubes, of about 0.02 mm. in length. In width at their orifices they may measure as much as 1 mm. At their junctions with the gland substance proper their diameters are less, as they are somewhat truncated. They are lined with a simple layer of small cubical epithelial cells.

(iv) *The Periosteal Attachment*

is due to the presence of strong bands of connective tissue which pass into the peripheric laminae of the bone.

PART III

THE HISTOGENESIS OF THE TEETH OF
MAMMALS, FISHES AND REPTILES

CHAPTER XII

THE DEVELOPMENT OF THE TEETH IN MAMMALIA

MICROSCOPICAL ELEMENTS IN:—(i) The Enamel Organ; (ii) Dentine Germ; (iii) Dental Capsule. (iv) During later periods of the formation and growth of the enamel, dentine, and cementum; and (v) Appearances in human embryos at half term.

For purposes of description it will be convenient to divide the series of phenomena which take place during the histogenesis of the deciduous and permanent teeth and surrounding structures, into:

- (A) The changes occurring in the jaws before and up to the period of formation of the dentine germ,
- (B) The metamorphoses occurring in and around the tooth germ at the period of formation of the dentine germ,
- (C) Subsequent stages of development.

A

Earliest Phases of Evolution

At a very early period of intra-uterine life in man, viz., about the 40th to 45th day, the embryo measuring about 12 cm. in length, the first signs of change are noticeable. The date synchronises with the commencement of ossification of the clavicle, the first of all bones to ossify.

(i) *Changes in the Ectoderm*

Coronal sections through the anterior part of the embryonic head before this age show that there is a slight appreciable thickening of the stomodæal ectoderm over the regions of the

embryonic alveolar processes, that is, the promontories of tissue known as the maxillary processes of the embryonic face, which, having met the lateral plates of the fronto-nasal process, have continued their growth downwards and inwards, and joined the mid-frontal process to complete the alveolar arch and maxillary bone. In the mandibular arch the changes begin above the cartilage of Meckel, and at places a little external to the primitive elevation of the tongue.

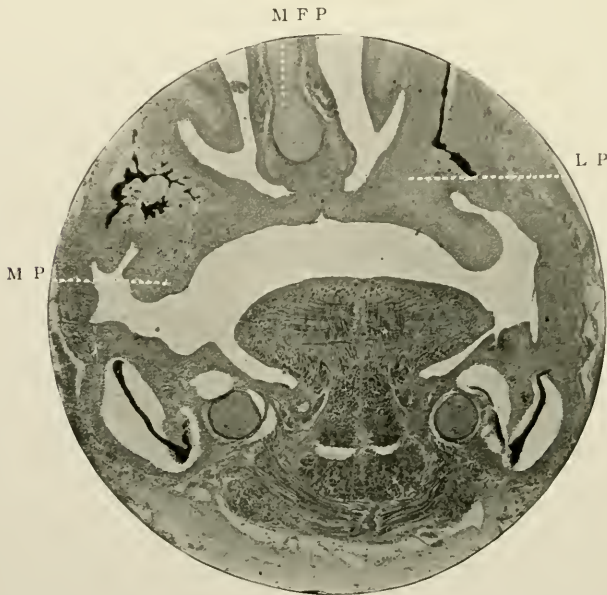


FIG. 199.—Coronal section through head of a human embryo, exact age unknown. Prepared as other soft tissues. Stained *en masse* with borax-carmin, and cut in paraffin wax. Magnified 20 times. To show the development of the maxillæ. M.P. Maxillary process; M.F.P. Mid-frontal process; L.P. Lateral plates of fronto-nasal process.

The contour of the *rete Malpighii* is undisturbed in its clear outline and flattened appearance.

The epithelial surface of the mouth is extremely thin and undeveloped, consisting of a few flat cells, while the *rete Malpighii* is almost indistinguishable from the rest of the ectoderm. A great depth in the mucosa is noticed, and the bones which will ultimately form the crypts of the teeth are beginning to appear and stain deeply.

In the kitten, the start in the development of the bony alveoli is delayed at this time, and even later; but in man, the osseous framework begins to assume a somewhat different shape, and is a prominent feature in specimens of an earlier date than the 40th day.

At this age, however, a marked metamorphosis in the ectoderm can be observed.

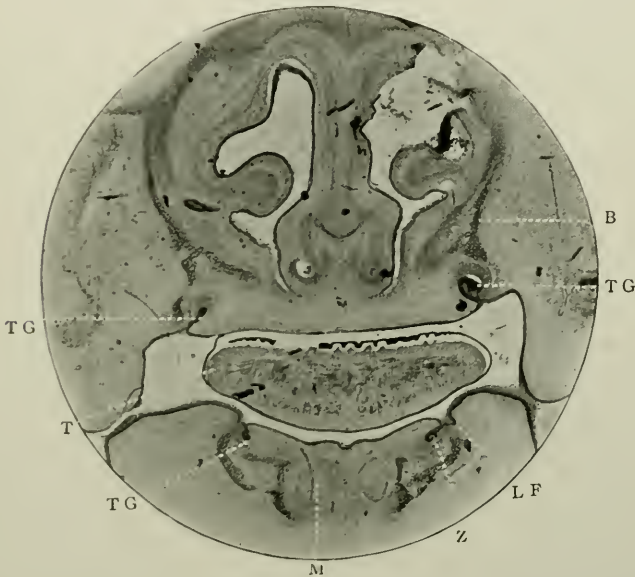

FIG. 200.—Coronal section through head of embryo of cat. Prepared and stained as last figure. Magnified 20 times. Represents the stage of development in man at about the 50th day of intra-uterine life. T.G. Tooth germ; z. Tooth band; L.F. Lip-furrow; T. Tongue; M. Meckel's cartilage; B. Commencement of formation of bone of alveolus.

(ii) *Formation of the Dental Furrow*

Its free surface appears to be slightly indented (*"The primitive dental furrow"*), in most cases, and follows fairly closely the lines of contour of the *rete Malpighii*. Over the palate in places, it is one cell thick, but over the floor of the buccal cavity, as well as its sides, and the sides of the roof, four, five, eight, or even nine rows of cubical or polygonal cells can be counted. The large size of their oval nuclei arrests attention. The cubical cells are set on what looks like a

delicate line or basement membrane. A few small flat squamous cells are often found here and there, coherent to the surface epithelium.

As the epithelium approaches the place where the *primary inflection* is about to occur, it becomes thickened.¹ The nuclei become considerably elongated, and almost fill the cells which themselves have undergone some amount of lengthening.

The epithelial surface is clearly distinguishable from the underlying tissues, for two reasons:—It takes the stain more intensely, and its cellular constituents are crowded together. In other words, its appearance is identical with that which is about to form the Schneiderian membrane of the nose, the surface epithelium of the skin of the face, and the under surface of the tongue.

The ectoderm would appear to be formed some considerable time after the mesoderm, that is, it is an involution of the superficial layer of the blastoderm reflected backwards into the mesoderm. Its genesis is probably synchronous with that of the nasal fossæ, external skin, and mucous membrane of the cheeks.

(iii) *The Primary Epithelial Inflection*

In coronal sections of the maxillæ the *first epithelial involution* into the subjacent mesoderm begins at a spot a little external to the lateral margins of the tongue, in the mandible some distance internal to those margins. The invagination extends right round the jaws, and thus forms a continuous semi-circular band of cells enclosed by mesodermic tissue. In vertical sections it looks like a narrow finger-like penetration of cells into the mesoderm: in side section it is seen to be a continuous flat band extending from the surface into the jaw.

(i) *Origin of the Lip-furrow and Tooth Band*

At the 40-45th day a splitting of this primary inflection occurs, not across, but in a longitudinal direction with it; thus

¹ This epithelial thickening is greatest along the line of the future jaw on the surface of which it extends longitudinally, and is produced by sub-division and repeated multiplication of the deepest cells.

it becomes divided into two parts, an outer and an inner. The former is towards what will be the labial side, the latter towards the tongue. The former, known as the *labio-dental strand*, or *lip-furrow*, passes in a perpendicular direction, and ultimately produces the groove which is afterwards the furrow between the lips and the alveolar processes of the jaws: while the latter, known as the *common dental germ*, or *tooth band*, is penetrating the mesoderm in a horizontal direction, and becomes the layer of cells, in connection with which both the deciduous and permanent teeth are developed.

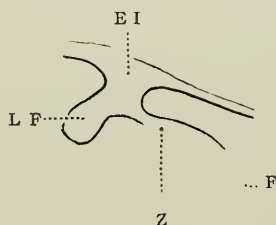


FIG. 201.—Diagram to show method of cleavage of the primary epithelial inflection. E.L. Ingrowth of epithelium; L.F. Lip-furrow on outer or buccal side; z. Tooth band on lingual side; F. Free growing end whence the permanent tooth germs will arise.

The opposing theories regarding the relations to each other of lip furrow and tooth band may be, here, briefly noted. Thus:

- (i) Röse¹ affirms that both have a common origin, as just described.
- (ii) Baume² believes that the tooth band arises from the side of, or is merely a process of the lip furrow, an opinion shared also by
- (iii) Xavier Sudduth,³ who says:—"The lamina is only an offshoot from the side of the band, which becomes somewhat shallower, and in some instances disappears."
- (iv) Leche⁴ holds that both are developed separately, but simultaneously.

¹ "Archiv. f. mikros. Anatomie." Bd xxxviii, 1891, and "Anat. Anzeig," 1896.

² "Versuch einer Entwicklungsgeschichte des gebisses," in *Odontologische Forschungen*, 1882.

³ "American System of Dentistry," p. 620, 1887.

⁴ "Morph. Jahrbuch," 1892, and "Bibliotheca Zoologica," 1895.

At this time the tooth band possesses an attached edge or border, which is continuous with the surface epithelial cells, and a free edge or border, which penetrates more deeply inwards. It is from this free edge that the ten deciduous tooth germs in each jaw will be developed.

Still examining the coronal sections through the embryonic head, it is seen that each tooth germ is accurately directed

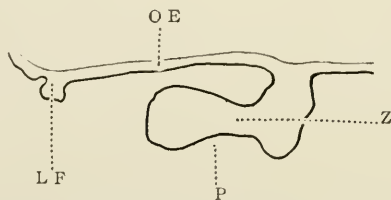


FIG. 202.—Diagram of a sagittal section through the germ of the first mandibular milk molar of a human embryo 30 mm. long. O.E. Oral epithelium; L.F. Lip-furrow; Z. Tooth band; P. Site of future dentine germ. (After *Röse*.)

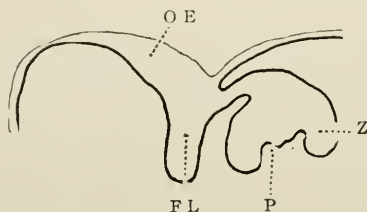


FIG. 203.—Diagram of a similar section to the preceding figure, but through the germ of the canine tooth of an embryo 40 mm. long. The lettering as in Fig. 202. (After *Röse*.)

towards the central portions of the developing alveolar bone: thus the direction of growth in the maxilla is upwards and slightly inwards, that in the mandible is downwards and slightly inwards. (See Figs. 200 and 204.)

The cells lining the tooth band possess the same histological characteristics as those at its immediate junction with the free stomodæal epithelium; viz., long, cylindrical cells with large oval granular nuclei situated rather more towards the distal than the basal end.

They are placed side by side in a single layer, the substance of the tooth band being composed of round or polygonal less distinct cells having circular, less granular nuclei.

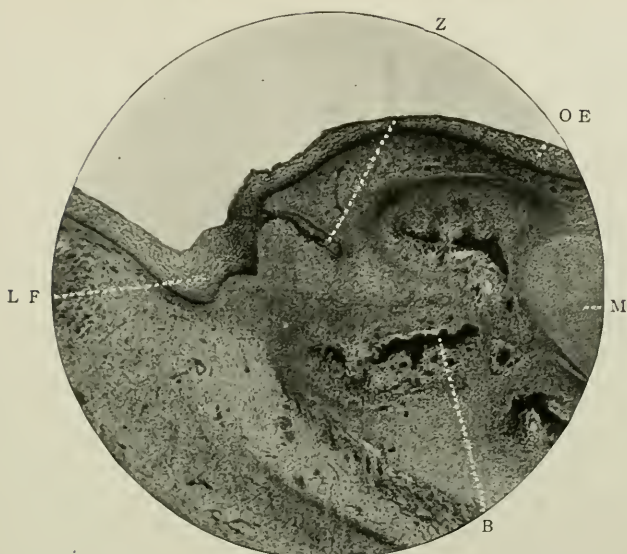


FIG. 204.—Coronal section of the mandible of an embryonic pig. Stained with hæmatoxylene. Magnified 45 times. Represents the stage of development in man at about the 50th day. z. Tooth band; L.F. Lip-furrow; o.e. Epithelium of mouth; M. Meckel's cartilage; B. Bone of alveolus.

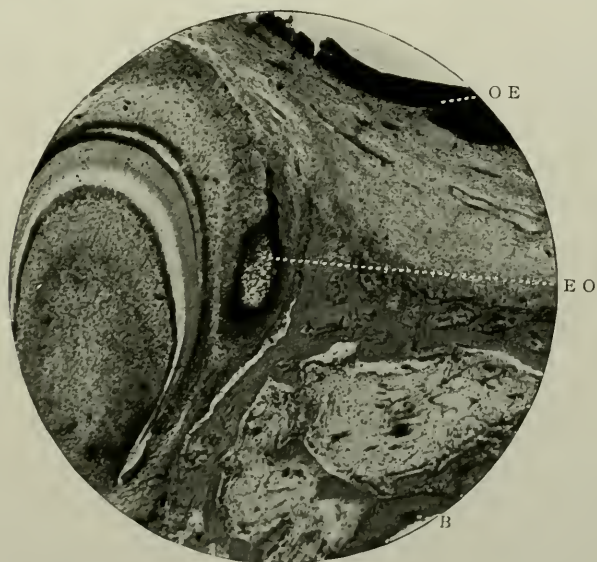


FIG. 205.—Further stage of growth. Magnified 45 times. The tooth germ in the centre of the field represents the stage of development in man at about the 60th day. E.O. First evolution of enamel "bud." Lettering as in preceding photomicrograph.

(v) *Changes in the Mesoderm*

Coincidentally with these alterations of the epithelial surface, many, *not all*, of the cells of the mesoderm (hitherto discrete) in the immediate proximity of the growing extremity of each germ undergo three distinct and remarkable changes. First they lose their identity as spherical mesodermic cells with rounded nuclei; they undergo a fresh arrangement of position; they become multiplied in numbers. No longer do all the mesodermic cells share like features regarding shape, the new change being that many become elongated, and therefore spindle-shaped and have fusiform nuclei. Those nearest the *rete Malpighii* of the tooth germ retain for some time longer their rounded outlines. Their new position is one in which their long axes take up the same direction as that of the up-growing tooth germ. Their numbers are trebled or quadrupled. It must not be forgotten, however, that these phenomena are only to be observed at the developing end of the epithelial germs.

(vi) *Evolution of the Enamel Organ*

The next step in development is concerned with the deepening of the tooth band and its lateral expansion *near*, but not *at*, its free end, into a bell-like structure. This takes place at its deepest portion, and on its labial side. At the superficial part a slight constriction begins to take place; and at about the 60th or 70th day in man, the first rudiments of the *enamel organs* of the deciduous teeth in the incisor region can be clearly discerned. They are called "enamel buds."

At certain spots, ten in number in either jaw, and separated at equal intervals along the continuous tooth-band these campanular bodies are found. The intervening portion of the tooth band in its anterior part presently atrophies and finally disappears after the lamina has become cribriform,¹ while it

¹Unatrophied portions of the tooth band frequently persist. According to their growth they may develop into elongated epithelial masses in the dental capsule, "glands" of Serres, supernumerary teeth, enamel nodules, accessory cusps, true geminated teeth, or epithelial odontomes.

still remains continuous in the posterior or molar region. The primitive enamel organs become now specially organised and constituted.

Thus originate the earliest aspects of the enamel organ. In shape such an organ is primarily like a Florence flask or laboratory beaker, having a broad flattened concave base, and long narrow neck opening on to the free surface of the epithelium

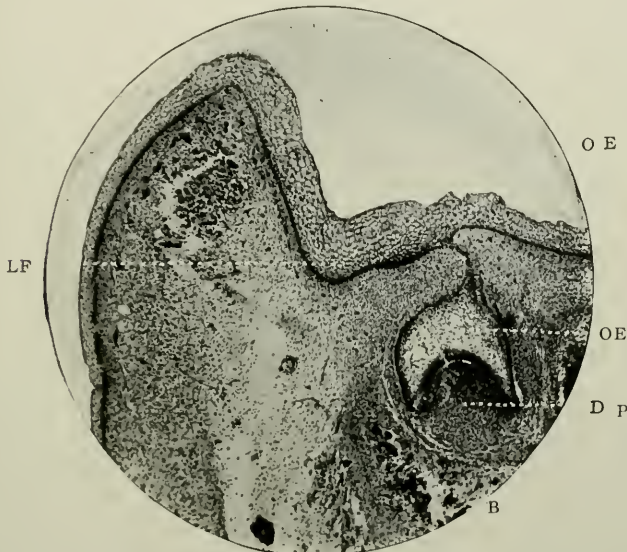


FIG. 206.—Further stage of development. Magnified 45 times. Represents the stage of development in man at about the 70th day. D.P. Rudiments of dentine papilla. Lettering as before.

of the mouth. At first the outline of the enamel organ is smooth, but later on, the external part will become rather sinuous, due to several "tufts" or "papillary projections" from the subjacent tissue indenting the external epithelial layer of cells. Sometimes the tooth bands and the necks of the enamel organs also exhibit these as collections of polyhedral cells similar to those just mentioned (see Fig. 232). Capillaries from the dental capsule are freely distributed to these "tufts."

In structure, the external cells still assume a cylindrical character; the deepest are more pronounced than those else-

where, and they are still continuous with the oral *rete Malpighii*. The interior is filled with round cells, which however speedily develop long branched extremities, and exhibit, in a rudimentary fashion, the cells of the *stellate reticulum*. It is not yet determined how these internal cells become branched, or exactly in what way the *stellate reticulum* is formed. Some observers, including Tomes, have thought that they represent cells undergoing retrogressive changes—conditions which point

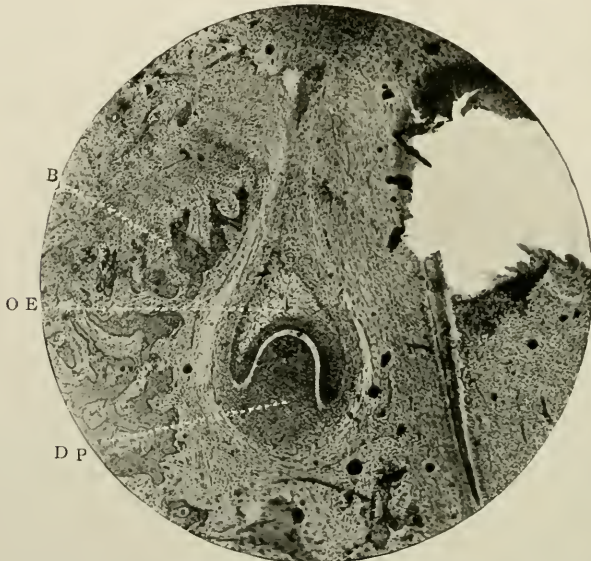


FIG. 207.—Campanular form of tooth germ, from the jaw of an embryonic kitten. Stained with hæmatoxyline. Magnified 45 times. Represents the stage of development in man at 70th day. Lettering as before.

to their ultimate disintegration and atrophy;¹ but Leon Williams holds that they merely represent a sort of intercellular stroma. It is nevertheless certain that lengthy 'marked' branching processes unite them together, their nuclei, in early stages of growth, being in no degree diminished in size, shape, or position.

All the central cells do not become changed into stellate bodies. Certain numbers, close to the deepest layer of the

¹ Cf. The degenerating cells in the cysts of epithelial odontomes, described in Chapter XV, Vol. II.

external epithelium, still retain their rotundity, and are ultimately the cells of the *stratum intermedium* which will presently assume their completed shape, viz., that of small polygonal rather branched cells, having connections externally with the *stellate reticulum*, and internally with the internal epithelium.

Rapid growth now occurs at the margins of each organ, and the whole structure resembles a bell with a handle.

The nearest mesoderm cells, about this time (70th day in man) begin to proliferate and to be more closely approxi-

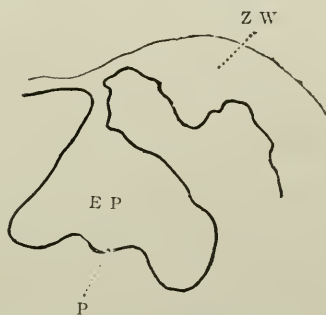

FIG. 208.—Diagram of a section through the germ of the first milk molar of a cow's fetus, 47 mm. long. z.w. Heaped-up epithelium characteristic of ruminants; e.p. Enamel organ; p. Site of future dentine germ. (After Röse.)

mated, and eight primitive dentine germs are noticed in the concavities of the enamel organs.

The alveolar crypts of the anterior parts have become increased in depth and importance, and begin now to assume a definite poculiform shape.

B

The Metamorphoses Occurring in and around the Tooth Germ at the Period of Formation of the Dentine Germ

The elongation of the necks of the enamel organs, the transparency of its central portions, the density of the dentine papilla, and the first attempts in the formation of a capsule or follicle or investing connective tissue sheath, are now observed (about rooth day).

While the neck of the enamel organ extends more deeply than ever into the jaw, it becomes still further constricted,

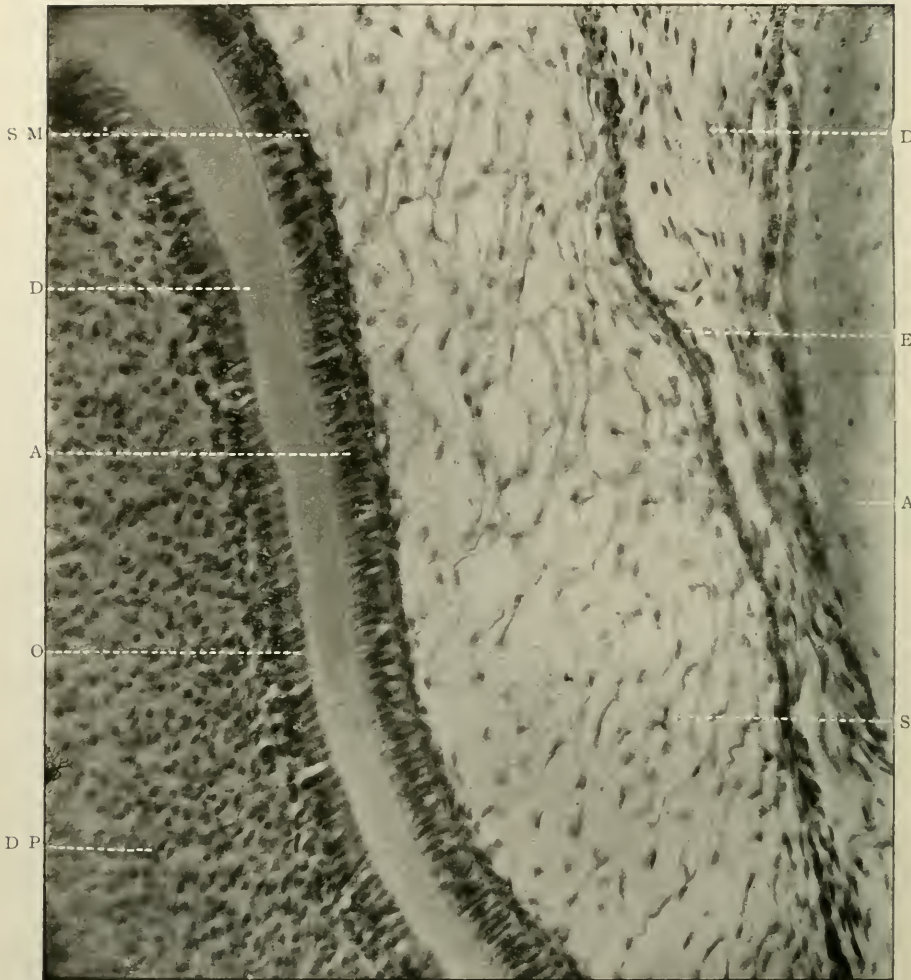


FIG. 209.—Structure of enamel organ. From jaw of a newly born kitten. Stained with borax-carmin. Magnified 300 times. o. Odontoblasts; d. Dentine; a. Ameloblasts; s.m. Stratum intermedium; s.r. Stellate reticulum; e.e. External epithelium; d.p. Dentine papilla; d.c. Rudimentary dental capsule; a.l. Bone of alveolus.

and practically occluded by the apposition of opposite rows of cells.



FIG. 210.—Section of incisor of a rat. Magnified 80 times. A. Capillary loops torn out of the secreting papillæ; B. Secreting papillæ after removal of capillary loops; C. Ameloblasts; E. Enamel; D. Dentine. (*Photomicrograph by Leon Williams.*)

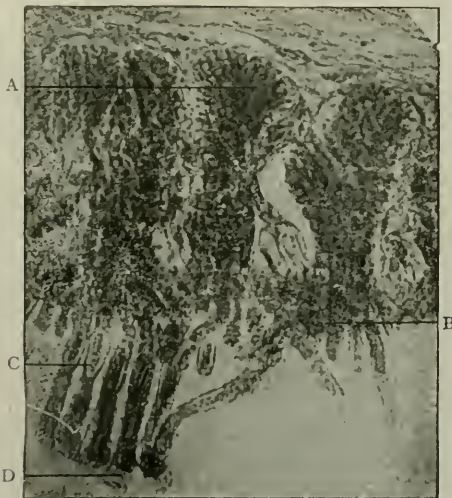

FIG. 211.—Secreting papillæ and ameloblasts from enamel organ of rat. Magnified 600 times. A. Papilla showing secreting cells; B. Showing roots of ameloblasts passing into papilla; C. Ameloblasts containing oval nuclei; D. Plasmic strings and granules emerging from ameloblasts. (*Photomicrograph by Leon Williams.*)

The *stellate reticulum* is now near its fullest height of development.

(vii) *Structure of the Enamel Organ*

The periphery of the enamel organ, starting at the neck (at one side) consists of several rows of cubical or cylindrical epithelial cells, whose oval nuclei almost fill the whole cell. At this spot the most external stellate reticulum cells are flat-

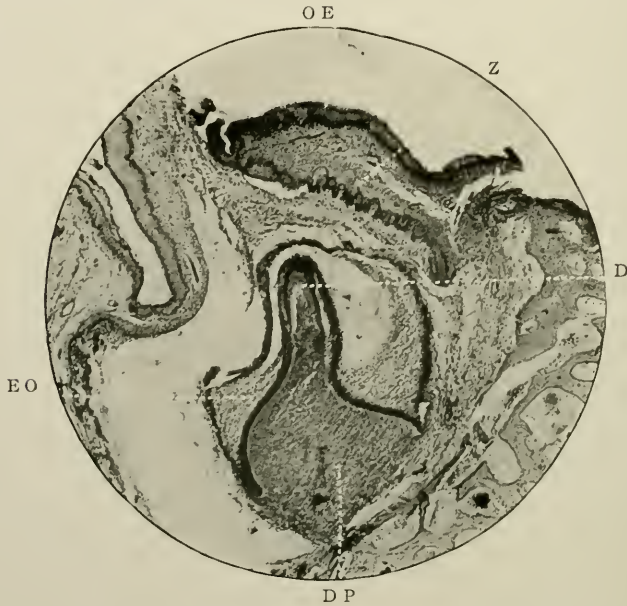


FIG. 212.—Later phase of development. Jaw of kitten. Stained with carmine. Magnified 65 times. Represents the stage of development in man at the 85th day. Z. Tooth band of permanent germ; E.O. Enamel organ; D.P. Dentine papilla of deciduous tooth; D. Earliest trace of formation of dentine; O.E. Oral epithelium.

tened and fusiform, and probably represent immature stellate cells, but their transition to the normal shape is sudden and pronounced.

At the deepest part of the enamel organ many ovally nucleated cylindrical cells are seen, several layers thick. Passing over the convexity of the dentine germ they become aggregated more closely till, as a palisading, they are most elongated directly over the summit of the convexity. Above these cells

of the *internal epithelium* are now six or seven rows of rounded nucleated cells. It is possibly their function to recruit the former.

Thus beginning from without inwards, the enamel organ consists of (i) *external epithelium*; (ii) *stellate reticulum*; (iii) *stratum intermedium*; and (iv) *internal epithelium*. The latter, soon to be called ameloblasts or enamel cells, are placed side by side on what would seem to be a fine basement membrane. There is no commencement of deposition of enamel.

The cells of the *stratum intermedium*, according to Leon Williams, form a layer in which blood-vessels are developed at a very early stage. This is well brought out in the enamel organs of rodents. Here the layer seems to be "a highly differentiated secreting tissue." The ameloblasts are surmounted by epithelial papillæ, around and between which is a free distribution of capillary loops. The enamel-forming cells are seen to have an intimate relationship with the papillæ, each apparently having a root-like process which extends into and is lost within the papilla to which it belongs. "The diameter of each papilla is equal to about that of five or six ameloblasts, and each papilla may therefore be said to supply from twenty to twenty-five ameloblasts" (Fig. 211).

The papillæ are supposed to originate in spindle-shaped cells.

(viii) *Changes in the Dentine Papilla*

Meanwhile the dentine germ is becoming highly specialized. The round nuclei of the cells crowd together, and apparently are imbedded at the enamel surface in a clear indefinable matrix. The cells are protoplasmic, minus branches; but most deeply of all they become fusiform with long branching processes, and are continuous with similar cells situated immediately outside the neck and the rotundity of the enamel organ. Furthest from the centre they are very narrow, and greatly separated from one another.

The alveolar bone is, at this time, extending towards the surface, and is encroaching on the neck of the enamel organ.

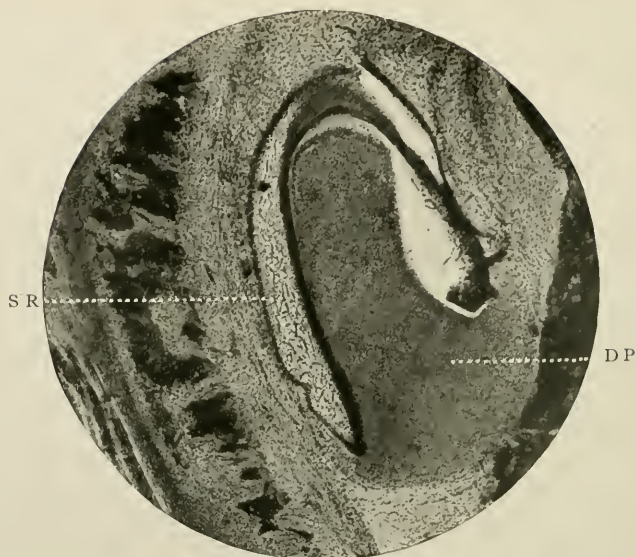


FIG. 213.—Further stage of evolution. Jaw of kitten. Stained with hæmatoxyline. Magnified 60 times. Represents the stage of development in man at about the 90th day. D.P. Dentine papilla; S.R. Stellate reticulum.

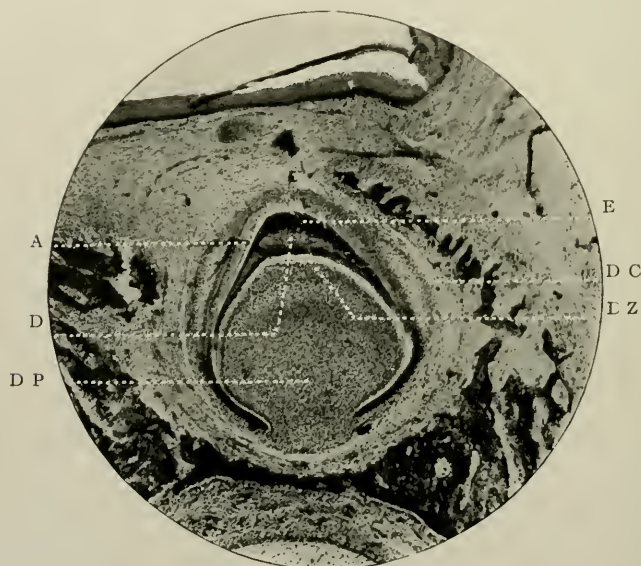


FIG. 214.—Same as preceding, further developed. Same magnification. Represents the stage of development in man at about the 120th day. E. First trace of enamel; D.C. Dental capsule; D.Z. Dentogenetic zone; D.P. Dentine papilla; A. Ameloblasts.

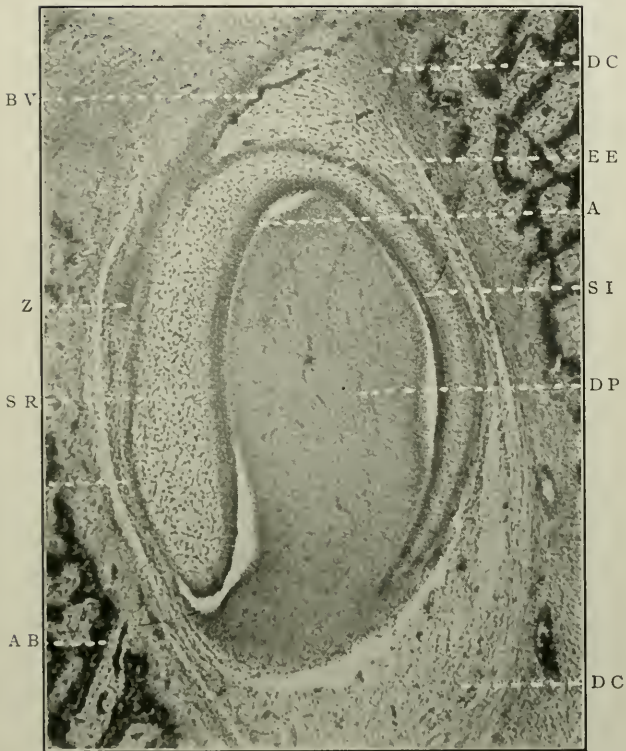


FIG. 215.—Similar to the preceding. Stained with hæmatoxyline. Magnified 80 times. Represents the stage of development in man at about the 100th day. E.E. External epithelium of the enamel organ; S.R. *Stellate reticulum*; S.I. *Stratum intermedium*; A. Ameloblasts; D.P. Dentine papilla; Z. Tooth band of permanent successor; B.V. Blood-vessel; D.C. Dental capsule; A.B. Alveolar bone.

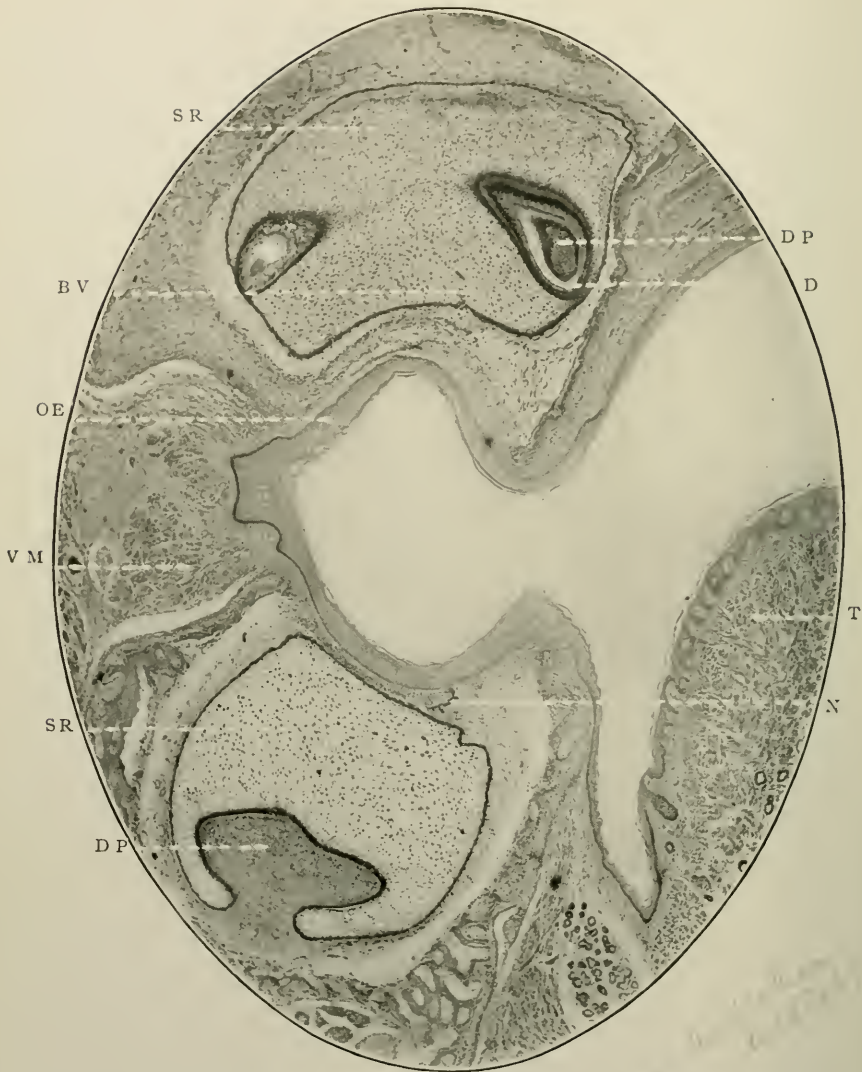

FIG. 216.—Vertical section through head of *Macropus Billiardieri*. Stained with hæmatoxyline and eosine. Magnified 45 times. There is no permanent tooth band, as Marsupials are mon phyodont. D. Dentine; D.P. Dentine papilla; s r. *Stellate reticulum*; N. Neck of enamel organ; B.V. Blood-vessel; v.M. Voluntary muscle of cheek; T. Tongue; o.E. Oral epithelium.

Shortly after these changes have taken place, the neck of the enamel organ is attenuated to the thickness of two layers of cells; and a tremendous increase in the mass of the stellate cells occurs. The internal epithelium assumes the shape of the ameloblasts, and some of the peripheral papilla cells that of the odontoblasts.

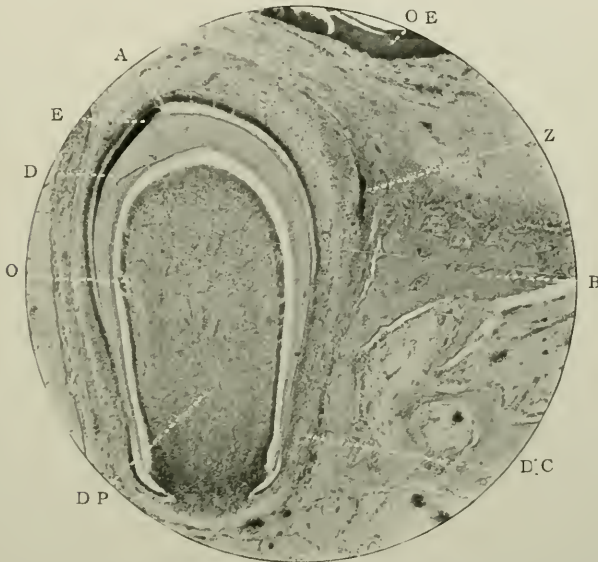


FIG. 217.—Further stage of development. Jaw of kitten. Stained with hæmatoxyline. Magnified 50 times. Represents the stage of development in man at about the 140th day. E. Early formation of enamel; A. Ameloblasts; D. Dentine; O. Odontoblasts; Z. Tooth band of permanent successor; O.E. Oral epithelium; D.P. Dentine papilla; B. Bone of jaw; D.C. Rudimentary dental capsule.

At the same time, about the 140th day in the deciduous incisors, the first deposition of formed dentine is seen, followed almost immediately by the darker line of enamel. The external and internal epithelia are still continuous.

C

Subsequent Embryological Changes

The tooth germ, at a later stage, is lodged in a deep, wide-mouthed gutter of bone. The cap of calcified enamel is sur-

rounded by the layer of *ameloblasts*—long columnar protoplasmic cells having prominent nuclei at their distal growing ends. They measure about 5μ in width, and vary in length from 5μ to 15 or 20μ . At the base of the dentine germ they are cubical in shape, and here attain the former smaller dimensions.

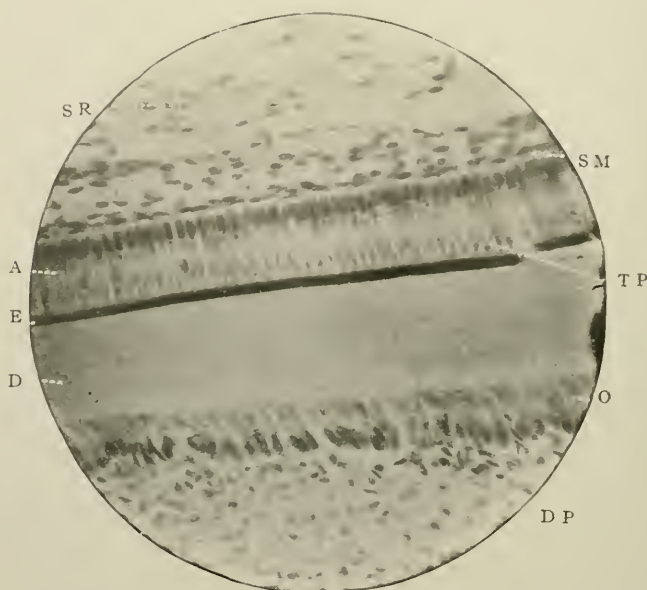


FIG. 218.—To show early stage of formation of enamel and dentine. Prepared by the chromic acid method, stained with carmine, and imbedded in paraffin-wax. Magnified 320 times. D.P. Dentine papilla; O. Odontoblasts; D. Dentine; E. Enamel; A. Ameloblasts; T.P. Tomes' processes of the ameloblasts; S.M. Stratum intermedium; S.R. Nuclei of cells of stellate reticulum. (Photomicrograph by Douglas Gabell.)

In places where they are torn away from the periphery of the enamel they present tapering processes, "Tomes' processes." This end (*viz.*, that directed towards the dentine), according to Tomes (*op. cit.* p. 168), is slightly enlarged, a fact demonstrated after treating an embryonic tooth germ with glycerine or other hygroscopic reagent. The cytoplasm of each ameloblast is granular, and possesses also a delicate spongioplasm (see Fig. 240).

Many instances occur in which the cells appear to be bounded

at either end by lines of basement membrane. To these Leon Williams has given the names the "inner and the outer ameloblastic membranes."

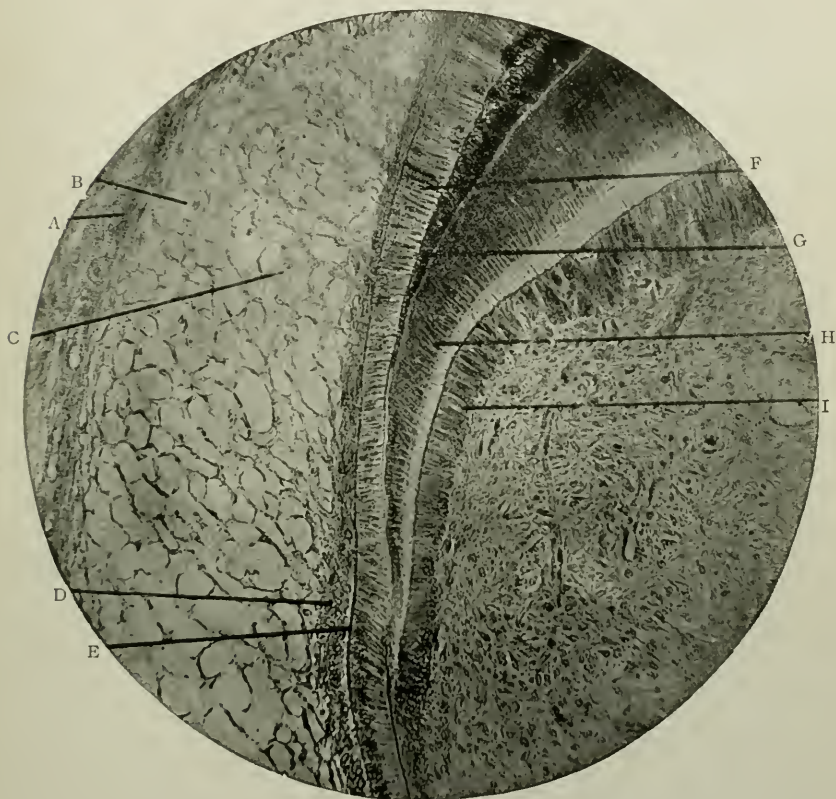


FIG. 219.—Section of developing tooth of human foetus near the seventh month of intra-uterine life. Magnified 175 times. A. Outer epithelial layer of enamel organ in which secreting papillæ are developed; B. and C. Numerous large, round, granular, nucleated cells of reticulum of enamel organ. The stellate appearance in this tissue is largely produced by shrinkage and the washing away of the cell contents; D. Stratum intermedium; E. Outer ameloblastic membrane; F. Ameloblasts; G. Inner ameloblastic membrane; H. Dentine; I. Odontoblasts. (Photomicrograph by Leon Williams.)

The former had been previously described by Huxley, Raschkow and others as the *membrana preformativa*.

Both membranes are structureless basement membranes, and are adherent to both extremities of the ameloblasts.

The outer lies between the ameloblasts and the cells of the *stratum intermedium*; the inner between the ameloblasts and the formed enamel.

Leon Williams describes these membranes very carefully in his contribution to *The Dental Cosmos* for 1896, pp. 110

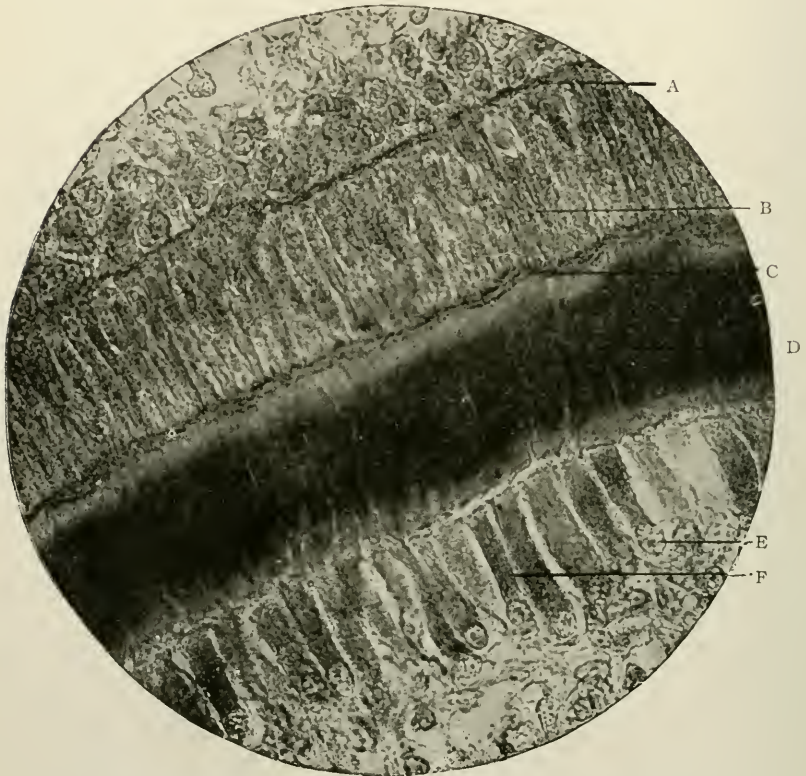

FIG. 220.—Section of developing tooth of embryo calf. Magnified 800 times. A. Outer ameloblastic membrane; B. Ameloblasts showing network pattern of plasmic cell contents; C. Strings of plasmic network passing through inner ameloblastic membrane; D. Dentine; E. Chromatin of nuclei of odontoblasts; F. Spongioplasm of odontoblasts. (Photomicrograph by Leon Williams.)

et seq.: “It is impossible at present (1896) to speak definitely with reference to its (the outer membrane) origin, exact structure, or function. Its appearance at the ends of the cells and not between them would seem to argue against the suggestion that it is due to a condensation of the peripheral zone of the

cells. But this view is supported by the fact that it is not seen during the earlier periods of the tooth germ; but only after the nearly or quite complete specialization of the ameloblasts." Under high powers it is composed of more than a single layer;

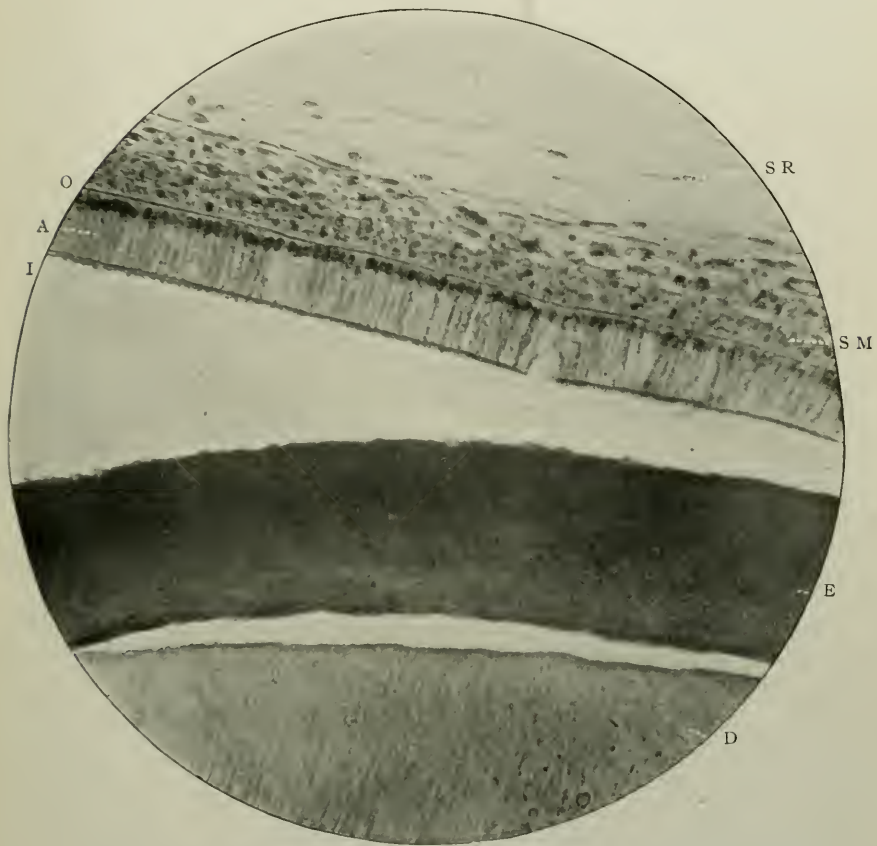


FIG. 221.—To show arrangement of parts in the enamel organ. Stained with hæmatoxyline. Magnified 300 times. D. Dentine; E. Enamel; A. Ameloblasts; I. Inner ameloblastic membrane; O. Outer ameloblastic membrane; S.M. Stratum intermedium; S.R. Stellate reticulum.

and "it is possible that it plays an important part in the elaboration of material for enamel building. It varies considerably in thickness in different specimens, but persists throughout the entire period of enamel formation—a fact which would seem

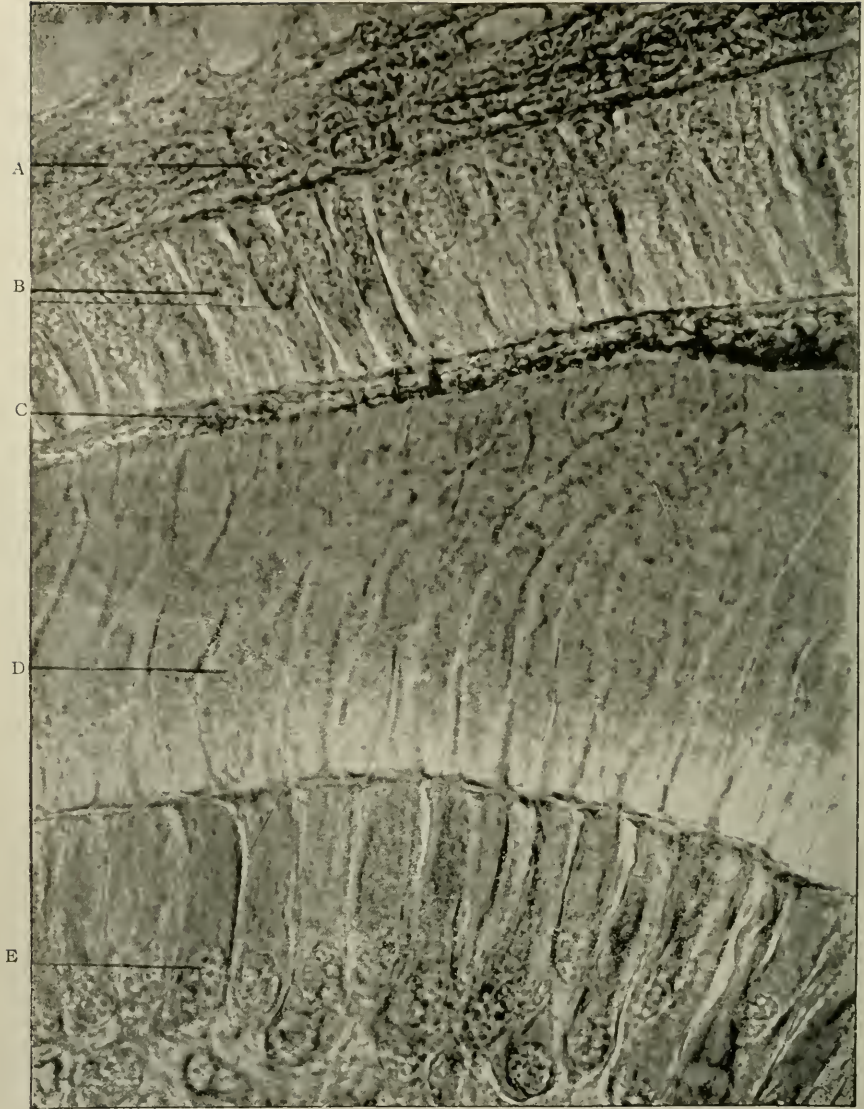


FIG. 222.—Section of developing tooth of human embryo. Magnified 1,000 times. A. Cells of stratum intermedium showing structure of nuclei. B. Ameloblasts; c. Enamel-globules showing radiating processes; d. Dentine; e. Odontoblasts showing chromatin of nuclei. (*Photomicrograph by Leon Williams.*)

to give a decided negative to the theory that the ameloblasts are renewed from the *stratum intermedium*, as many writers on the subject have supposed."

The free surface of enamel has a pitted or honey-combed outline, whence the Tomes' fibres have been withdrawn; the rest is almost homogeneous.

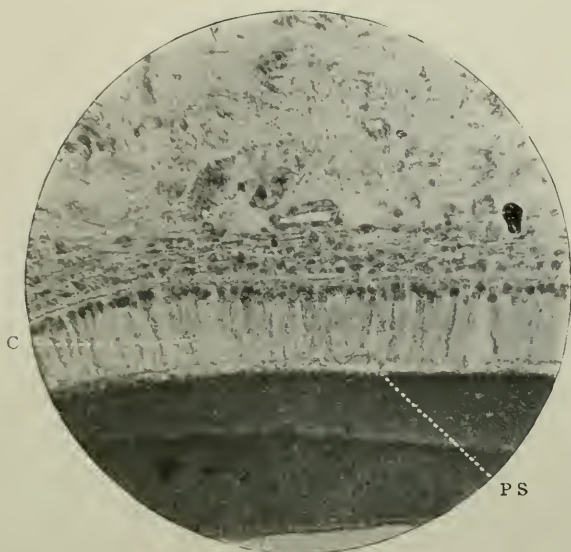


FIG. 223.—Similar to Fig. 221. P.S. Pitted surface of enamel; c. Calcoglobular mass in an ameloblast.

Not so, however, the dentine, for traces of its tubular nature can, even at this early stage of growth, be easily observed in sections stained with Ehrlich's acid hæmatoxyline in its calcified (external), and less clearly in the formed but as yet uncalcified portions.

The superficial mesodermic cells of the papilla, before the formation of the odontoblasts, are arranged with a certain amount of regularity, with their long axes pointing towards the ameloblasts. These in their growth become elongated, the result being, according to Paul (*op. cit.*), the formation of a definite superficial zone.

Their nuclei are "resting" (see Fig. 101).

Later on the odontoblasts themselves begin to appear among these superficial cells, the nuclei of which, passing from the resting stage, undergo atrophy.

The remainder of the papilla is made up of branched continuous cells.

Shortly after the fusiform connective tissue cells, which go to make up the dental capsule or follicle, have become con-

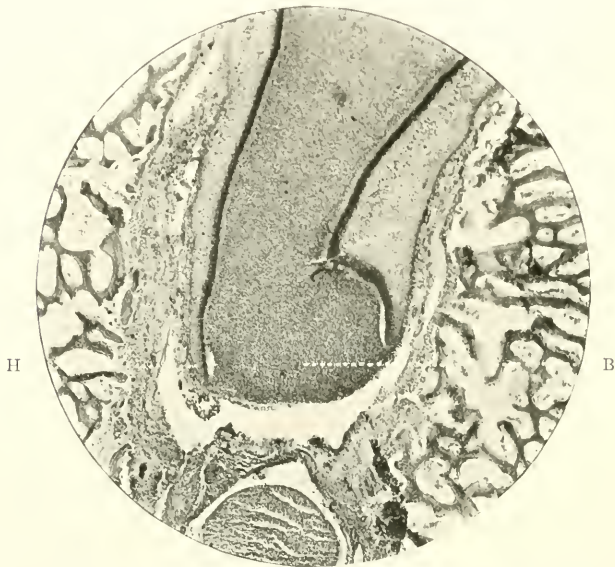


FIG. 224.—Vertical section through mandible of human fœtus at about the 160th day of intra-uterine life. Shows base of deciduous canine tooth. Prepared as usual with soft tissues. Stained *en masse* in borax-carmin. Cut in paraffin-wax. Magnified 50 times. B. Base of dentine papilla; H. Epithelial sheath of Hertwig.

tinuous round the whole tooth germ, the investing *stellate reticulum* begins to disappear. The first stage in its atrophy and absorption is the disappearance of the nuclei of these cells.¹ The external epithelial cells become somewhat separated, but connected still with the branches of the *stellate reticulum*

¹ The stellate reticulum persists longest in the intervals between the cusps of the molar teeth.

on the one hand and the elongated cells of the dental capsule on the other. The ameloblasts reach their highest degree of development over the cusps of the dentine germ, and the enamel is being rapidly manufactured. The dentinal wall of the

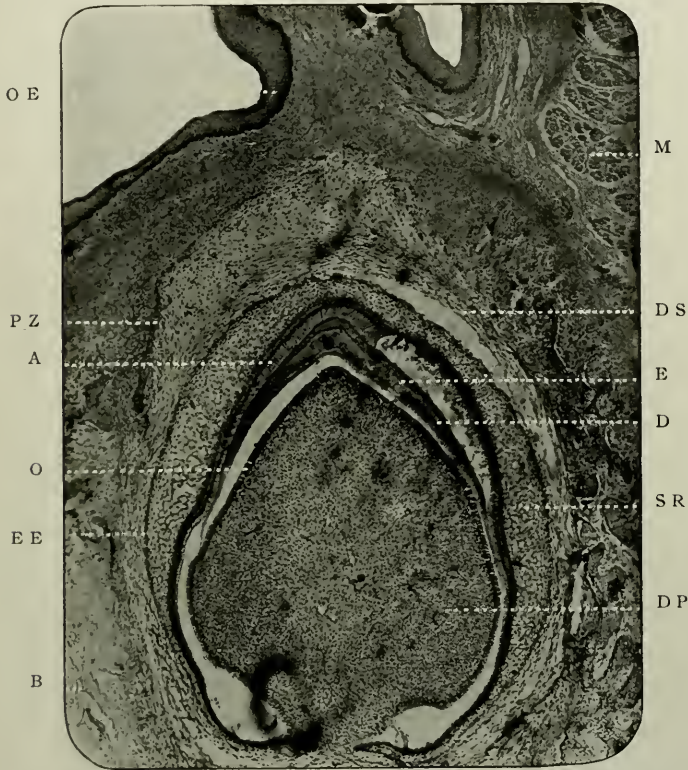

FIG. 225.—Vertical section through jaw of pulp at birth. Prepared in the usual way. Stained with Ehrlich's acid hæmatoxyline. Magnified 45 times. Represents the stage of development in man at about the 140th day. o.e. Oral epithelium; A. Ameloblasts; E. Enamel; D. Dentine; O. Odontoblasts; D.P. Dentine papilla; S.R. Stellate reticulum; E.E. External epithelium; D.S. Dental capsule; B. Bone of jaw; P.Z. Tooth band of permanent tooth germ; M. Voluntary muscle fibres cut transversely.

tooth germ is lengthening towards the base of the dentine germ, which shows signs of constriction by the approximation of the cells of the internal epithelium.

At the extreme point they suddenly curve upwards and outwards, and thus form the *epithelial sheath of Hertwig*.

The cells of the dentine germ possess the same histological characteristics, except those on the surface of the pulp, which,

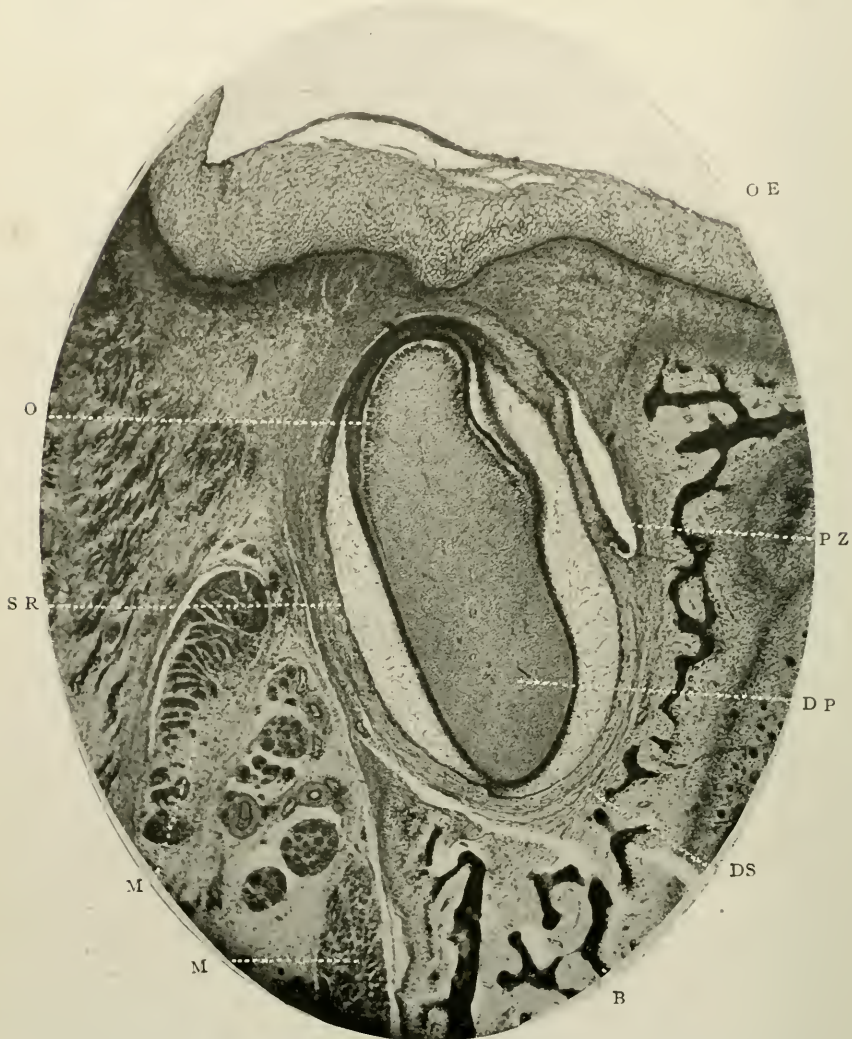


FIG. 226.—Coronal section through the maxilla of a foetal pig. Prepared and stained as in last figure. Magnified the same. Represents the stage of development in man at about the 120th day. Lettering as in Fig. 225.

as the so-called odontoblasts, are clearly differentiated in size, shape, and staining properties from the other connective tissue cells.

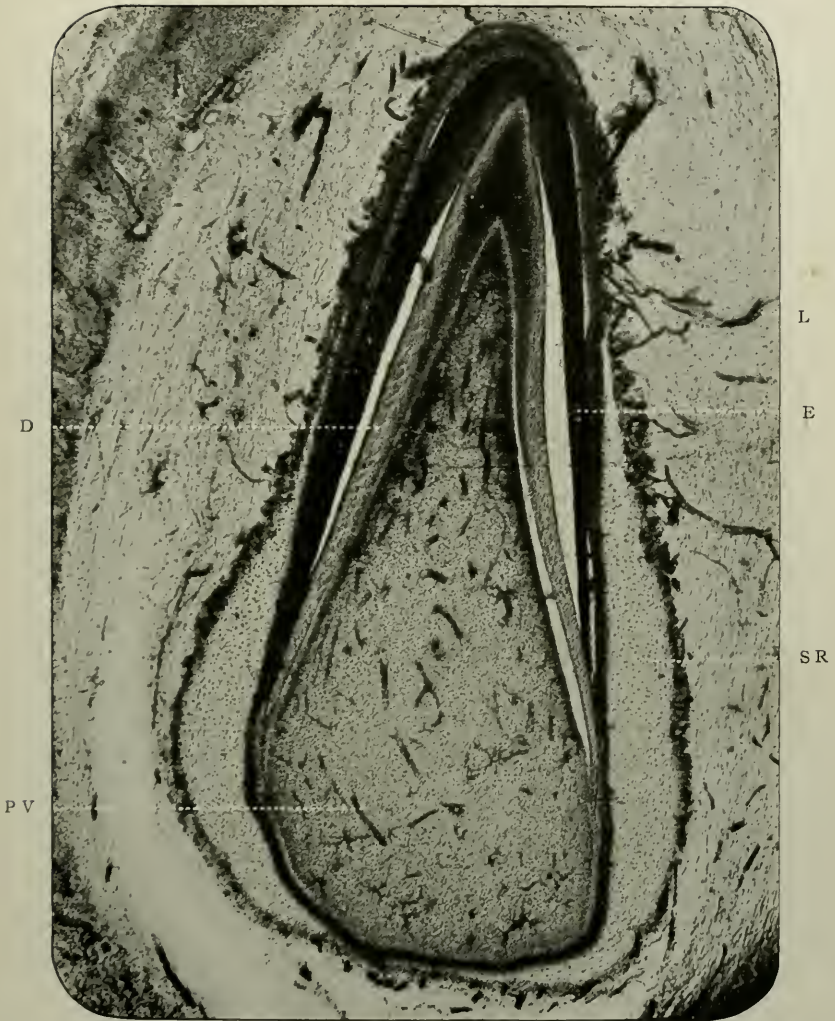


FIG. 227.—Coronal section through the mandible of a kitten. Stained with borax-carminé after hardening in formic aldehyde. The blood-vessels are naturally injected. Represents the stage of development in man at about the 160th day. Magnified 65 times. E. Enamel; D. Dentine; s.r. Stellate reticulum; P.V. Blood-vessels in the pulp; L. Loops of capillaries extending to the external epithelium of the enamel organ.

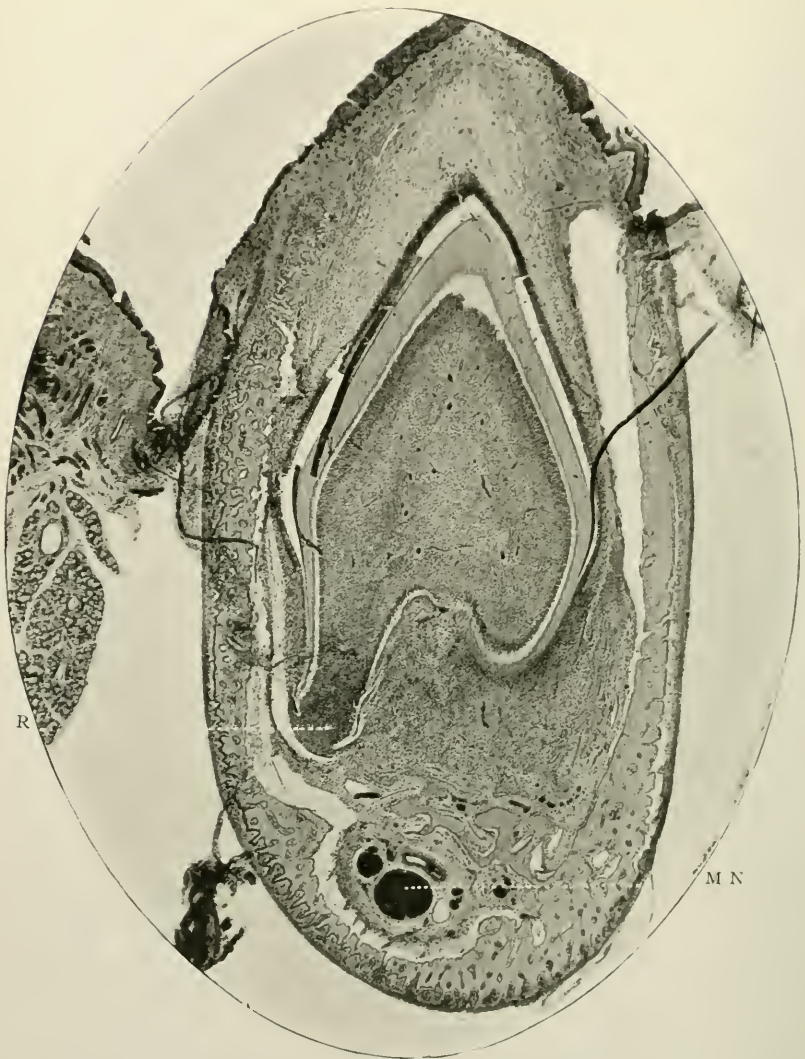

FIG. 228.—Vertical section of mandible of pupa at birth. Stained with hæmatoxyline. Magnified 30 times. About same age as preceding figure. R Early formation of a root; M.N. Mandibular nerve, with accompanying artery and veins.

(ix) *Evolution of the Permanent Tooth Germs*

About this period sections show the epithelial inflection which goes to form the successional tooth, which is but the growing or free end of the tooth band, and not a budding from the neck of the enamel organ of the deciduous tooth germs. Röse has proved this fact beyond doubt. This neck has now completely vanished.

Subsequently the tooth germ assumes the shape of the future tooth. The enamel organ has gone; the calcified dentine and dentogenetic zone surround the young pulp. The thickness of the enamel cap has increased; the regularly arranged ameloblasts and *stratum intermedium* cells are very pronounced, and nothing intervenes between the oral epithelium and the *stratum intermedium* but a large amount of submucous tissue, composed of long branching fusiform connective tissue cells imbedded in a thin stroma, which also contains blood-vessels, and at times, tiny masses of epithelium ("Glands of Serres"). The latter are derived from the remnants of the fenestrations of the tooth band. The former seem to run right down to the condensed papillary tissue on the surface of the *stellate reticulum*, as if they were carrying special nutritive material to this region.

In the young pulp, the walls of the blood-vessels and rudimentary myelinic nerve fibres make their appearance, the first by the approximation and joining up of the branching process of the longer cells, running singly in a line, the second by the development of the cells in longitudinal bundles.

The vascularity or otherwise of the enamel organ is not yet determined, many competent authorities holding opposite opinions on this subject. Thus Lionel Beale, Leon Williams, Howes, and Paulton assert that a vascular network is to be found in the *stratum intermedium*, while Tomes, Paul, Andrews, Wedl, Sudduth, and Magitot affirm its non-vascularity.

The author in a joint paper with H. W. Marett Tims has recently described the presence of blood-vessels, containing erythrocytes in the enamel organ of the Australian wallaby.

(“Tooth Germs in the Wallaby, *Macropus billiardieri*.” *Proc. Zoolog. Soc.*, London, 1911.)

(x) *The Blood Supply of the Developing Dental Tissues*

In determining the relationship which normally exists between the vascular supply of the dental tissues and the tissues themselves, it is necessary to consider the origin of the blood-vessels, their arrangement and mode of distribution, and the areas supplied by them. Where great development is taking place there is a free blood supply, and the more complex the organisation of a part—whether in anatomical structure or location or in physiological function—the more abundant anastomosis of capillary blood-vessels is found. And this anastomosis is most important in controlling the growth of the tissue, as on it depends the hypertrophy, or atrophy, or normal conditions of the part. For should the blood stream be increased or accelerated, then overgrowth results; while, on the other hand, should it be diminished or occluded, it is followed by shrinkage, atrophy, degeneration, and death.

Hence the blood supply of the hard and soft dental tissues is of vital importance; when normal, the tooth undergoes the changes consequent on evolution, and, finally, is erupted in a perfect condition; when abnormal, hypertrophies and atrophies of the whole or parts of the teeth are produced, and irregularities of external configuration, defects in quality of the organic and inorganic substances and other deviations from typical forms occur.

The most useful subject for the purposes of the examination of the capillary arrangement is an injected section, in which the functional activity of development is most progressive, and most clearly discernible—a section whose genetic cells are most busily engaged in producing the various dental and peri-dental structures—a section, in short, which exhibits the birth of the life-history of a tooth.

Here it is found that the tissues formed from each layer of the primitive blastoderm are supplied by separate sets of vessels. There is (i) an external or superficial, and (ii) an internal or deep network, the former being distributed to the tissues

which are ectodermic in origin, including gum and certain parts of the enamel organ; the latter to those arising from the mesoderm, including dentine papilla, dental capsule and surrounding bone. Thus, the external set of vessels is distinctly separated from, and has no connection with, the internal deeper set, except at one part, viz., the periodontal membrane, where they meet and anastomose freely (see Plate I).

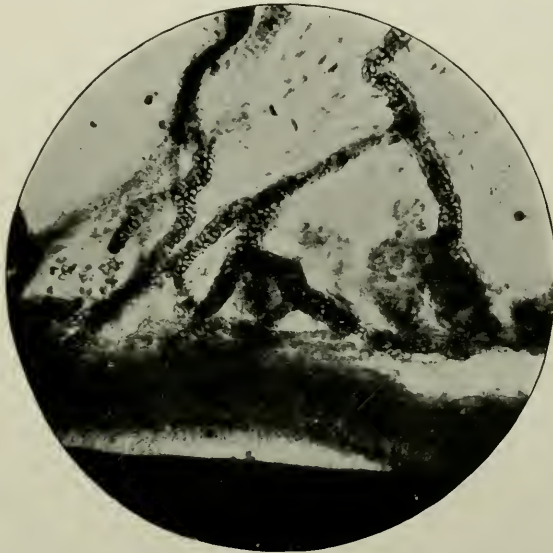


FIG. 229.—A portion of the blood supply of the stratum intermedium of the enamel organ of the section photographed in Fig. 227. Magnified 300 times. The staining was unsuited to reveal the structure of the ameloblasts; but it displays the erythrocytes which have been retained *in situ*.

(i) *The external set* supplies the enamel organ and gum. On examination of the *enamel organ proper*, it is found that its external part is absolutely free from any closely meshed network of capillaries. The layer of cells, forming the external epithelium and the thin branching cells of the *stellate reticulum* have no blood supply. One or two large non-branching vessels traverse the space occupied by the reticulum, from the thick gum and connective tissues lying external to the enamel organ. These, having advanced as far as the *stratum intermedium*, suddenly break up into numbers of small capil-

laries, and form a beautiful plexus which supplies the cells of this intermediate layer and the internal epithelium.

But the capillaries are placed very closely together over the layer of ameloblasts—a fact explained by the activity and importance of these cells in the formation of enamel and their consequent necessity for a large supply of blood.

Little need be said of the vessels of the gum. The *stratum corneum*, *lucidum*, and *granulosum* are non-vascularised: the *rete Malpighii* and fibrous connective tissue of the dermis differing greatly by being abundantly provided with numerous straight, long vessels which ramify in every direction. It is clear, therefore, that the nourishment of enamel organ and fibrous tissue of the gum emanates from the same source, and is quite differentiated from that of the other dental structures.

(ii) *The internal set* supplies the dentine organ, dental capsule, and surrounding bone.

In the dentine organ, the pulp has by far the largest and most important system of blood-vessels. Here, one large vessel enters at the apical foramen of the tooth, and occupying its longitudinal axis, passes sinuously outwards, to end near the newly formed dentine. As it proceeds, its calibre becomes somewhat diminished in size, and in a thick plexus of vessels its branches terminate beneath the odontoblasts, some running, in adult pulps, into the basal layer of Weil. There appears to be no definite regularity in the arrangement of the primary branches: they leave the large arterial trunk at a considerable angle—in some sections this approaches to, even if it does not exceed, a right angle. The secondary and other branches have a similar arrangement. The greater number of the minor distal branches run parallel to the dentogenetic zone under cover of the odontoblasts, between and around which their ultimate ramifications are distributed. These cells and the small round pulp cells which lie closely to them, have, therefore, an abundant supply of blood, brought about in a similar manner to that which obtains in the cells of the *stratum intermedium*, and internal epithelium.

The comparative size of these pulp vessels is much greater than that of the fine closely set capillaries of voluntary muscle

fibres; they bear a slight analogy to them, but none of the vari-
cosities or spherical dilatations found on the walls of the latter
are to be observed in the former.

The advantages of this peculiar method of arrangement—
the sinuous primary arterial trunk, the branches coming off
at right angles, the minute anastomosis beneath the dentine—
are manifest at once. It is evident that they are thus distrib-
uted, first, to give as large an area of blood supply to the pulp
tissues in as small a space as possible; and, second, to prevent
shock or any other extraneous influence from acting injuriously
on its delicate elements. In this manner, a flow of blood to the
part is maintained—constant and uniform, two necessary
factors in the production of perfect development, growth, and
nourishment.

There is no collateral circulation in the dental pulp.

Included in the term “dental capsule” at this period of the
genesis of the tooth, are its products, the cementum and perio-
dental membrane.

It is difficult to determine absolutely whence and how the
cementum is nourished. It would seem to come chiefly from
the periosteal vessels. That trophic influences are exercised
upon it to a certain but limited extent, is an undoubted fact, and
it is equally certain that the dentine is not the medium by
which they come. Hence it is fair to presume that the same
vessels which supply the alveolo-dental membrane, vitalize
the tissue by means of an exudation of lymph through their
walls, which passes into it *viâ* the channels which contain
Sharpey’s perforating fibres. It may be assumed, however,
that cementum is practically devoid of nutrition.

Wedl¹ was the first to demonstrate that the dental perios-
teum has three sources for its blood supply, viz.: (*a*) from the
gum, (*b*) from the pulp, and (*c*) from the adjacent bone of the
alveolar process.

In regard to the first, it has already been shown that the
external and internal sets unite in this situation, the vessels
of the gum running downwards to anastomose with the

¹ “Pathologie der Zähne,” 1870.

internal set which supplies the dental capsule. But also loops of capillaries from the main arterial trunk of the pulp, before it enters that organ, can be seen spreading outwards and joining the before-mentioned vessels (see *F*, in Plate I). And in addition, numerous offshoots from the capillaries of the alveolar bone run towards the cementum, and form thick plexuses with the other two. The periosteum is, therefore, most richly vascularised, and forms by its method of attachment the vascular bridge, so to speak, between the living tissues of the jaw and the tissues of the tooth.

The vascularisation of the bone of the alveolus calls for no further comment here, being identical with the blood supply of cancellous bone elsewhere.

Briefly, to summarise, it can be said with tolerable certainty that of the soft tissues, the pulp as being the most important nutritive agent, has the greatest, and the gum the smallest system of capillaries; while in the enamel organ the reticulate cells, and the external epithelium are destitute of any vessels whatsoever.

An examination of the section from a photomicrograph of which Fig. 227 is reproduced, shows, however, that while blood-vessels do not actually anywhere pierce the *stellate reticulum*, yet long capillaries run freely everywhere immediately outside the external epithelium; and where this is closely applied to the *stratum intermedium* (the intervening stellate tissue being atrophied), the numbers and size of the capillaries are greatly increased. This must not be interpreted, however, as signifying complete, but only as a modified form of vascularisation of the enamel organ.

The cells of the internal epithelium must obtain a free blood supply from somewhere, for the purpose of manufacturing the calcific basis of enamel, and it is difficult to conceive of this physiological phenomenon occurring as a product of cells which have no contiguity whatever with the vascular system of the body.

An important addition to the literature of the vascular supply of the teeth of man comes from the pen of Dr. W. Lepkowski, of Cracow. Following up original work on in-

jected preparations of the teeth of the lower placental vertebrates, there appeared an interesting article on "The Distribution of the Blood-vessels in the teeth of Man" in the "Anatomische Hefte."¹

"In a fœtus of seven months the alveolar artery provides one branch for each tooth germ which is thus entered at its base. The artery directly before its entrance into the sac is still to be recognised as such, and can be easily distinguished from the veins accompanying it. Further on, the walls of the artery become so thin that even in stained preparations they can no longer be distinguished from the two veins accompanying it. The vessel now rises to the highest part of the pulp and there divides into a number of branches, which spread out in a fan-like fashion from the base to the apex of the tooth germ. These branches are really capillaries. They proceed between the odontoblasts up to the dentine and there form broad loops which unite with each other. As has already been described in animals, there also spreads out in man, on the surface of the pulp between the odontoblasts, a broad net of capillaries, which is distinguished from the remaining wool running through the pulp by its breadth and density. An examination of numerous sections teaches one that the distribution of this capillary net is not, however, the same on the whole surface of the pulp. At the base of the tooth the vascular anastomosis is always denser and more interwoven than towards its apex, where the net becomes comparatively broader and looser. This arrangement of the vessels follows the arrangement of the odontoblasts. With low magnifying power there can be seen, in preparations stained with carmine, a broad band of odontoblasts at the base of the tooth germ just where the vessels also are present in greater numbers; towards the top of the tooth germ the breadth of the odontoblast layer decreases appreciably, and simultaneously the network of the vessels becomes looser. It can scarcely be doubted that both appearances are connected with each other. It is also easily to be explained why at the base of the tooth germ the vessels

¹ "Die Verteilung der Gefässe in den Zähnen des Menschen," Weisbaden, 1901.

and odontoblasts are more closely arranged than elsewhere; for it is on the base of the tooth that new substance is deposited, and the vessels and odontoblasts (*sic*) are chiefly concerned in this process. As this distribution of the vessels and cells can be seen in every preparation, we may consider this kind of arrangement as the rule in the formation of teeth. In reference to the mutual relationship between capillaries and odontoblasts, it may be mentioned that the former, as loops, reach, between the odontoblasts, up to the dentine layer. They take no direct share in the formation of the dentinal tubes. On the other hand, we must assume that they convey the necessary material for the building up of the tooth and induce special activity of the odontoblasts. The dense distribution of the vessels at the surface of the pulp, between the odontoblasts generally, as also specially at the basal parts of the tooth germ, points to this.

“If we compare the vascular systems in the various teeth of the same embryo, we obtain deviations according to the number of the roots and the form of the tooth crown. . . . If we take a section through a single root tooth germ—for example, a canine—we get, in the centre of the pulp, a bundle of vessels, which after their sub-division into finer ramifications provide for the entire pulp, and under the dentine spread out in a characteristic manner. In the germ of a two-cusp tooth there are present two bundles of vessels separated from each other. From this we get the impression that the tooth had been developed from a number of single teeth corresponding to the cusps and roots. A series of sections obtained from the tooth germ of a three-rooted molar favours the proposition still more. We see, therefore, in the first sections two bundles of vessels and two cusps. The vascular bundles enter separately at the base of the tooth germ, and only in their ramifications in the tooth pulp do they become connected with each other.”

As a corollary to this line of argument this author formulates the following highly interesting theory: “I believe that my results on the distribution of the vessels in developing molars speak in favour of the hypothesis advanced by various investigators, among them Dybowski and Röse (*‘Ergebnisse der Anat. und Entwicklungsgeschichte,’* 1899), that the het-

erodont set of teeth of man and mammals has originated from a homodont dental apparatus. The individual cone-shaped teeth such as exist to-day in reptiles, becoming approximated through the shortening of the maxilla, fuse, so to speak, and form compound teeth, which according to their function and the development of the osseous parts surrounding them, in the course of time, receive their present shape. The witness for their descent from simple teeth is to be sought for in the rudiments of several cusps, and their separate vascular supply during their development. Not much reliance must be placed upon the number of roots with which they are provided. As already stated, this is as a rule reduced, perhaps in consequence of mechanical influences. Besides, as is known, there are often found four, five, or even six roots on molars. Their presence proves that corresponding to the number of cusps under favourable conditions they may continue to exist in their original type without reduction, of course, as rudiments, of the former homodont masticating apparatus.

“The vessels which externally surround the enamel organ are connected with the pulp-vessels. The vessels originate in the inter-alveolar arteries which supply the cancellous bone substance of the maxillæ. They spread out in a dense woof at the surface of the enamel organ, but do not, however, penetrate between the ameloblasts of the enamel organ. To judge from microscopical sections they belong to the venous system. They surround the tooth germ from the first rudiments of its development. Notwithstanding that they deviate from the method of arrangement of the pulp-vessels, they agree with the latter in so far, in a physiological sense, that they play an active part in the formation of the enamel, as the others have an active share in the formation of dentine. On thorough examination of the preparations, it is observed that at the apices of the tooth-germs where the enamel is thickest, the vascular net is also denser. The points correspond to the highest parts of the tooth. When the tooth crown is near its completion, the activity of the enamel cells gradually ceases, and the vessels supplying them slowly undergo retrogressive changes. Within the tooth, however, the formative activity

of the odontoblasts and the blood-vessels still continues, until the dentine of the crown and the roots has been built up.

“The disappearance of the vessels of the enamel organ begins at the summit of the tooth, and proceeds in the direction of the root. In the stages of evolution, in which the tooth is erupted, the superficial vessels unite with those of the gum; those lying deeper surround the root and supply its newly formed periodontal membrane. They spread out on the walls of the alveolus, and remain in this position, as long as the tooth exists. . . . Of the pulp-vessels, individual vessels or also bundles of them occasionally separate, perforate in places the dentine-layer and the enamel-layer and obtain connection with vessels surrounding the tooth germ on the outside. Examples of such vascular connections I have observed in tooth preparations of the embryos of the lower animals, as also in those of man.

“On examining such sections one might be tempted to think of an analogy with the Haversian canals in bones. However, the vascular connections of the kind mentioned are too rare to be looked upon as quite normal formations. I believe I can explain in another way this vascular communication which arises but rarely.

“In later stages of development, and in adult man, one finds at the lateral surfaces of the teeth, and more especially on the molars, a funnel-shaped constriction. In sections, made transversely through the tooth at the level of such a depression, one observes the dentine tubes markedly condensed, as it were, as if there were present a scar in the dentinal tissue, which reached up to the pulp cavity.

“In my opinion these cicatricial formations in the developed tooth are related to the vascular communications just described. I myself, during my researches on fully formed teeth have never seen any other formations than this cicatricial contraction, but Thiel mentions a case which tells in favour of my view. Scheff cites the same case in his ‘Handbuch’ when discussing hæmorrhage after extractions. After the extraction of the first upper premolar on the right side, considerable bleeding followed, which, on careful examination,

was traced, from the wall of the alveolus, to a bundle of vessels which entered the tooth at the neck and ran transversely through the dentine up to the pulp. At the outset it is not to be assumed that the vessels in the case mentioned above originally perforated the fully formed tooth, because the tooth substance in advanced life is too hard to allow blood-vessels to penetrate, and, on the other hand, the vascular supply at that period, in comparison with that of a younger age, is too slight."

Lepkowski holds that: "If we compare the vascular distribution in the teeth of man with that of mammals, such as the pig, the horse, and the rabbit, we find, what was to be expected, that there are no appreciable differences. The course of the vessels, their distribution, the density of the vascular net at corresponding places, and its relationship to the tissues in course of formation, are the same here as there. The more pronounced differences are in the number of the vessels in the tooth germ. In embryos of the animal species cited, there exists in the pulp, as also specially in the enamel organ, far richer vascular ramifications than in the corresponding teeth of human embryos. The explanation, to my idea, is not far to seek. There exist very considerable differences, first, in the relative size of individual teeth between animals and man (for example, the canine); and secondly, in the thickness of the layers of substance. In the dog the thickness of the enamel layer surpasses by far that of the human teeth. It is, therefore, quite natural that the tooth germs of animals are provided more richly with vessels.

"Otherwise the vascular distribution from embryological periods up to the complete development of the teeth is, in its fundamental characteristics, analogous in man and animals. The observations also which I have made in regard to the relationship of vessels to the cusps and roots in human teeth may be similarly applied to the teeth of animals."

The subject is one of importance, and invites greater attention than has hitherto been accorded to it. It should not, however, be so difficult a matter to determine in these latter days; since the modern introduction into the methods of Dental Microscopy, of solutions of formic aldehyde, as a

fixing and hardening agent, has shown that the natural injection of blood-vessels by blood cells can be maintained almost exactly as during life.

(xi) *Final Stages of Evolution*

Later phases in the evolution of the teeth include the growth of enamel and dentine, the approximation, to the surface of enamel, of the external epithelium as the cellular layer of Nasmyth's membrane, and the complete organization of the dental capsule.

(xii) *Dental Capsule*

As a thick investing fibrous belt this structure envelops the whole of the tooth, except at the apex of its root. Each tooth has its own capsule: and each capsule has a separate entity. At first consisting, as has already been pointed out, of layers of flat fusiform cells, round cells begin to be formed within it. These move in an inward direction, and assume the shape and functions of ordinary osteoblasts. The result of their activity is to deposit cemental matrix, which, about the times of the completion of the crowns of the teeth, becomes intimately and securely applied to the external periphery of the dentine. These cells probably pour it out as a homogeneous ossifying flood.

The remainder of the capsule becomes, almost synchronously, transformed into the periodontal membrane.

It is likely that a special cement organ, which according to Magitot partakes of the nature of fibro-cartilage, exists over the crowns of the developing teeth of the ruminating groups in *Artiodactyla*. A cement organ, as such, has no existence, however, in the teeth of man.

An examination of the tooth band of the permanent tooth, in Figs. 231 and 232, would lead one to suppose that here was a truly remarkable example of four successive tooth germs in man, viz.: pre-milk, deciduous, permanent and post-permanent (V_1 , E , and DP , PZ , and V_2). Some authors, in-

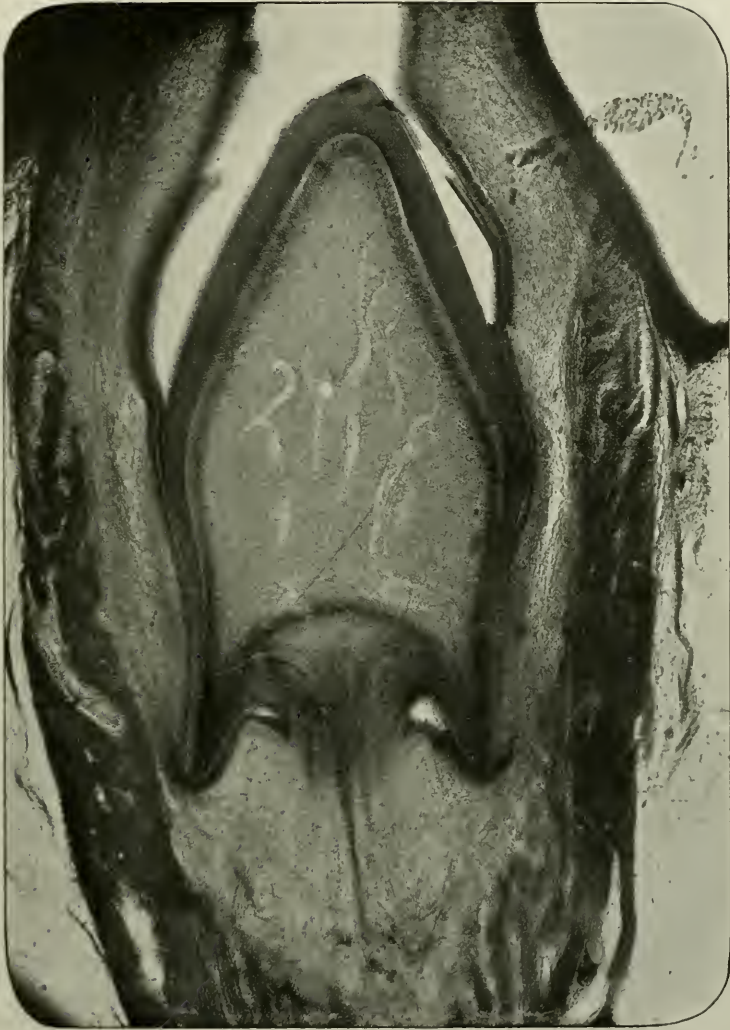


FIG. 230.—To show the vascular supply of the dentine papilla. Magnified 55 times.

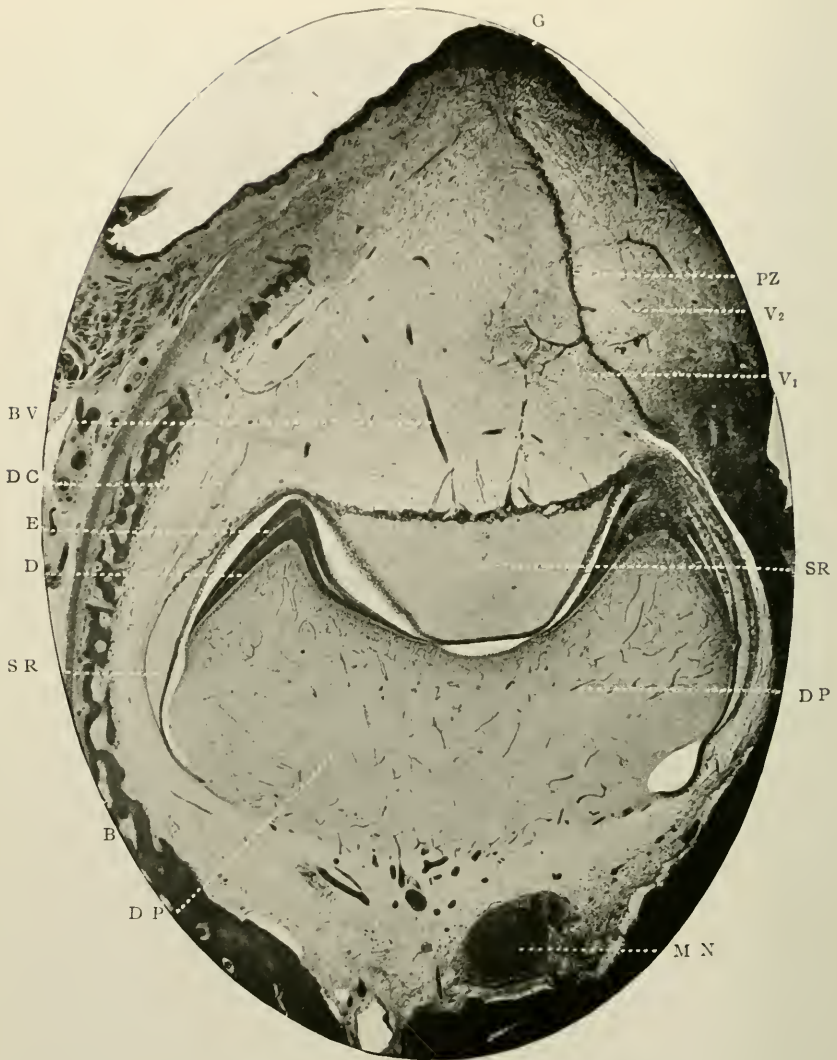


FIG. 231.—Coronal section through the mandible of a human foetus, at about the 170th day of intra-uterine life. Prepared by decalcification, after fixing in formic aldehyde. Stained with hæmatoxyline, and counterstained with eosine. Magnified 15 times. E. Enamel of deciduous tooth; D. Dentine; s.r. Stellate reticulum; d.p. Dentine papilla; d.c. Dental capsule; p.z. Tooth band of permanent molar tooth on lingual side; b.v. Blood-vessels extending to external epithelium; G. Oral epithelium; B. Bone of jaw; m.n. Mandibular nerve; v₁. A supposed vestigial germ (pre-milk); v₂. A supposed vestigial germ (post-permanent).

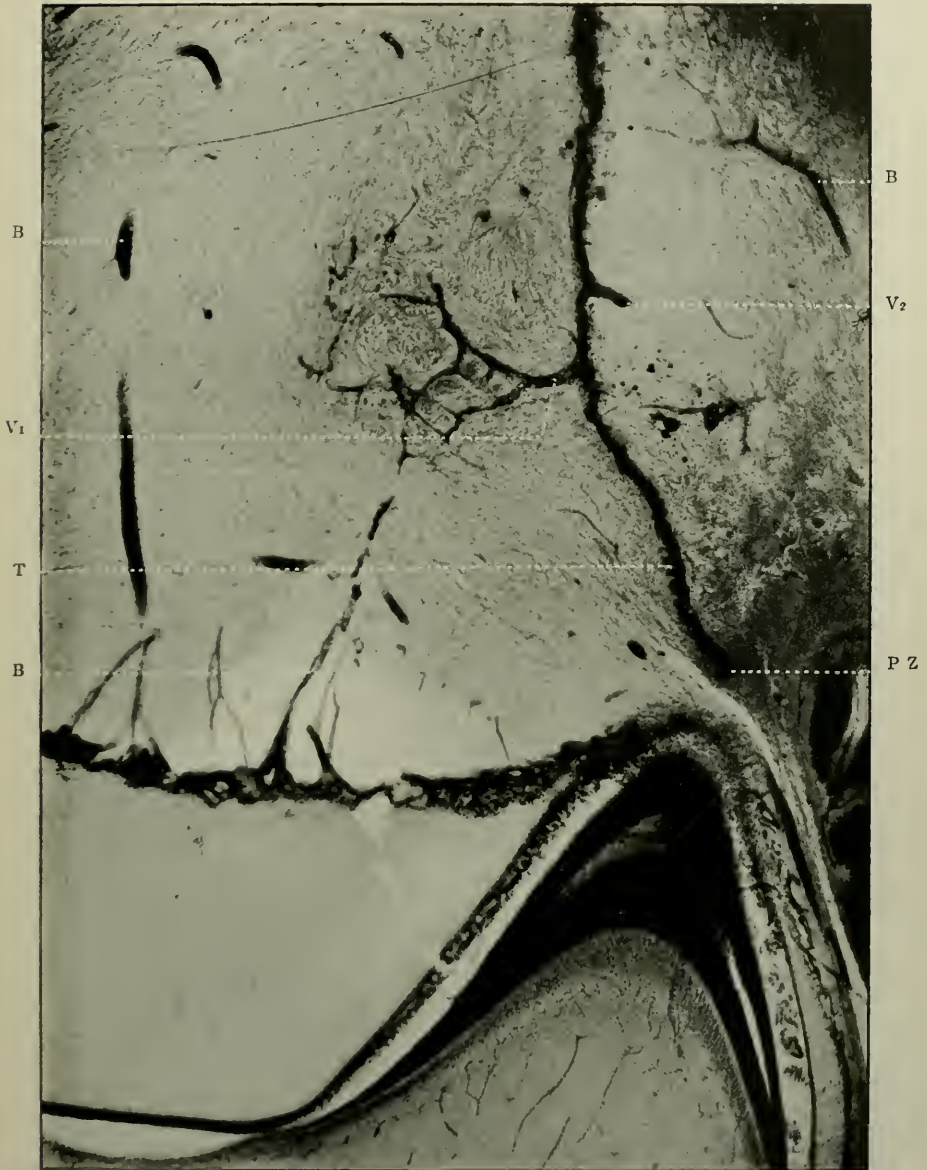

FIG. 232.—The same as the preceding. To show the "tufts" on the tooth band of the permanent germ. Magnified 75 times. p.z. Tooth band of permanent tooth germ; t. "Tufts;" v₁. Part of the tooth band which might be considered by some authorities to represent the tooth band of a vestigial (pre-milk) tooth; v₂. That of post-permanent tooth; b. Blood-vessels.

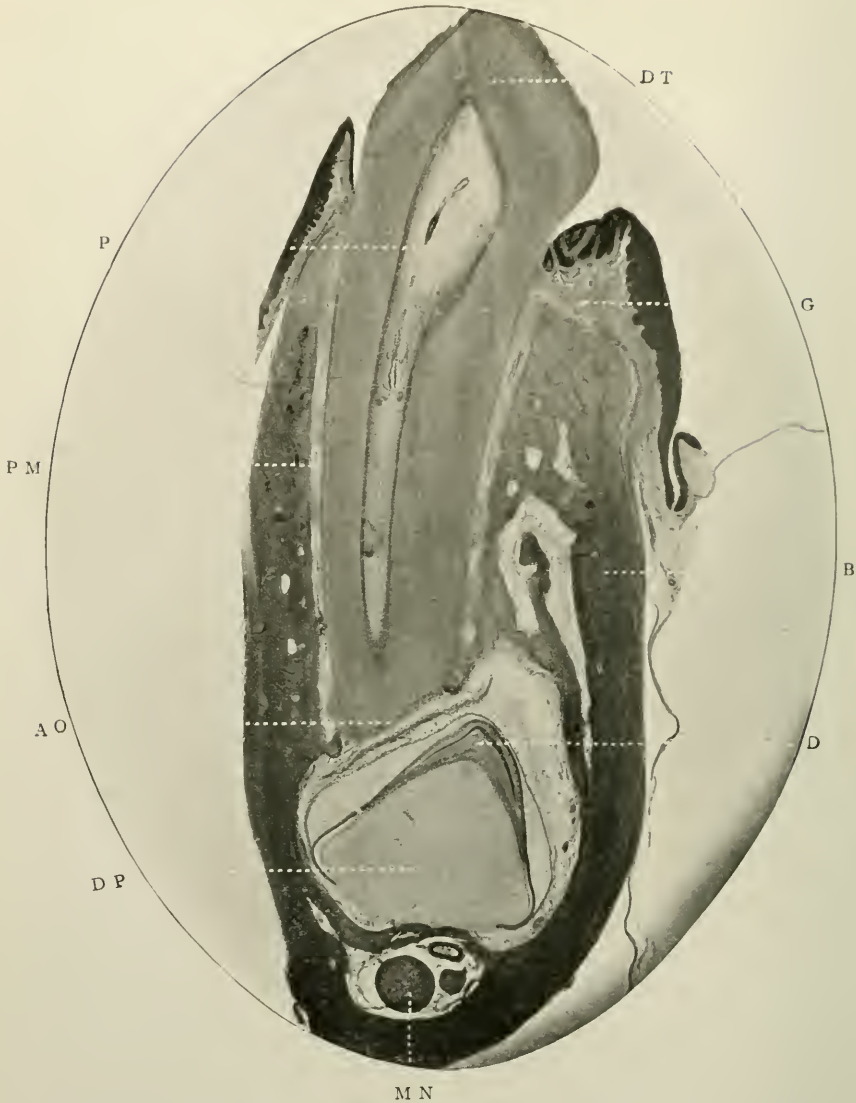


FIG. 233.—Sagittal section of mandible of kitten, with the deciduous and permanent teeth *in situ*. The former is fully erupted. Prepared by decalcification after fixing in formic aldehyde, and hardening in alcohol. Magnified 15 times. Represents the stage of development in man about the 18th month after birth. D.T. Dentine of deciduous tooth; P. Its pulp; P.M. Blood-vessel in its root membrane; A.O. Its absorbent organ; D. Dentine of permanent tooth; D.P. Dentine papilla of same; B. Bone of jaw; G. Gum tissue; M.N. Mandibular nerve.

cluding Röse, Leche, Kukenthal, etc., would accept the offshoots, as these aberrant tooth bands. As Tomes, however,

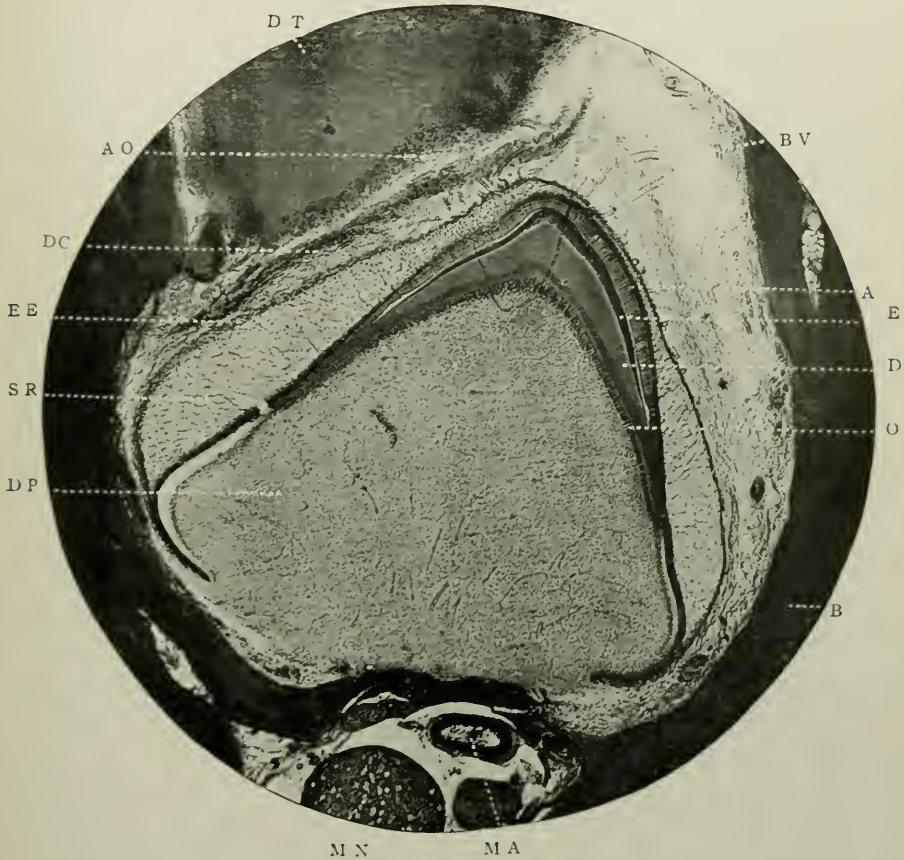


FIG. 234.—The permanent tooth germ of preceding figure. Magnified 65 times. D.P. Dentine papilla; o. Odontoblasts; d. Dentine; e. Enamel; a. Ameloblasts; s.r. Stellate reticulum; e.e. External epithelium; d.c. Dental capsule; b.v. Blood-vessels going down to external epithelium; d.t. Dentine of deciduous tooth; a.o. Absorbent organ of deciduous tooth; b. Bone of the jaw; m.a. Mandibular artery; m.n. Mandibular nerve.

points out (*op. cit.* p. 352), scepticism can only be removed when these structures have become differentiated into external and internal epithelia, and calcification is seen to be commencing.

(xiii) *Recapitulation*

It seems advisable, for the simplification of a somewhat abstruse subject, such as the Development of teeth in *Mammalia*, to here append a brief outline of the histories of the various structures met with during such a study.

1. *Epithelial Inflection*.—Due to individual proliferation of deepest layers of cells of the oral epithelium, and collective penetration into the sub-lying tissues: undergoes cleavage longitudinally; thus forms (i) Labio-dental strand and (ii) tooth band, Fig. 201.

2. *Dental Furrow*.—A slight superficial indentation over the epithelial inflection.

3. *Labio-dental Strand, or Lip Furrow*.—Outer division of primary epithelial inflection after its cleavage: elongates in vertical direction; widens; central cells atrophy; thus producing open sulcus between lips or cheeks and teeth and alveolar processes of jaws. Fig. 203.

4. *Tooth Band, or Common Dental Germ*.—Inner division of primary epithelial inflection, after its cleavage: elongates: has (i) *as one portion*, on *labial* side, depression which goes to form enamel organs of ten deciduous teeth; and *as another portion* (ii) free end or border on *lingual* side, which, continuing to grow, produces enamel organs of ten permanent teeth on lingual side of deciduous germs; and still growing, extends backwards to form enamel organs of first, second and third permanent molars; is continuous around whole length of jaw: degenerates and becomes cribriform; finally disappears, leaving sometimes small epithelial remnants *in situ*, known as "glands" of Serres, also epithelial bodies in dental capsule, supernumerary teeth, true gemination, enamel nodules, etc.

5. *Enamel Organ*.—Formed by expansion of base of tooth band: ectodermic in origin; assumes various shapes; consists of external epithelium, *stellate reticulum*, *stratum intermedium* and internal epithelium; disappears after alveolar crypts are completed.

6. *Neck of Enamel Organ*.—Attenuated form of original tooth band: atrophies.

7. *External Epithelium of Enamel Organ*.—Peripheral layer of round cells continuous with *rete Malpighii* on one hand and internal epithelium on other: undergoes modification and probably forms cellular layer of Nasmyth's membrane.

8. *Stellate Reticulum*.—Ectodermic in origin: derived from central cells of tooth band; acts probably as "packing material" or filter; consists of large stellar cells with prominent nuclei, and long branching processes; nuclei atrophy and network entirely vanishes.

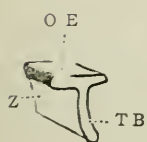


FIG. 235.

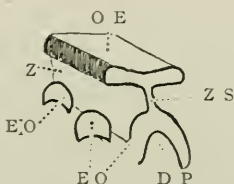


FIG. 236.

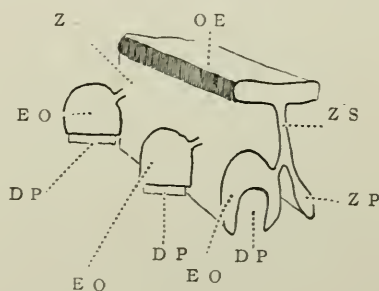


FIG. 237.

FIGS. 235, 236, 237.—Diagrams to show the tooth band, method of evolution of the tooth germs of the deciduous teeth, and continuation of the tooth band to form enamel organs of their permanent successors. O.E. Oral epithelium; T.B. Tooth band in section; Z. Tooth band seen sideways as a continuous sheet; E.O. Enamel organs; D.P. Dentine germs of deciduous teeth; Z.P. Continuation of tooth band going shortly to form enamel organ of permanent tooth germ on lingual side of the others. (After Stöhr.)

9. *Stratum Intermedium*.—Layer of round or polygonal cells intervening between last-named tissue and internal epithelium, from which it is separated, according to Leon Williams, by outer ameloblastic membrane: disappears.

10. *Internal Epithelium*.—Continuous at edges with external epithelium; forms enamel-depositing cells or ameloblasts; thickest over cusps of teeth through individual cells being longest in these situations: as such disappears after enamel calcification is completed, but most probably persists in modified form as translucent pellicle of Nasmyth's membrane.

11. *Epithelial Sheath of Hertwig*.—Continuation downwards to base of dentine germ of layer of internal epithelium: is

believed to determine shapes of future roots; disappears; may leave unatrophied remnants as epithelial "rests" in periodontal membrane.

12. *Dentine Papilla*.—Formed by upgrowth of mesoderm in concavity of enamel organ: mesodermic in origin; assumes form of future tooth, viz., conical, premolariform, molariform, etc.; persists as dental pulp.

13. *Dentogenetic Zone*.—Band of formed but uncalcified dentine, bounded externally by fully completed tissue, internally by layer of odontoblasts: disappears when work of calcification is done.

14. *Membrana Eboris or Odontoblasts*.—Cylindrical bipolar cells situated at periphery of dentine organ and dental pulp; bounded externally by dentine, internally by basal layer of Weil: perpetually persist.

15. *Dental Capsule or Follicle*.—Connective tissue capsule investing each tooth germ: mesodermic in origin, whence are derived periodontal membrane and cementum; persists till near time of eruption, then atrophies.

FORMATION OF THE HARD TISSUES

The study of the phenomena of the calcification of bone and other allied tissues involves the discussion of several subjects, such as chemistry, physics, physiology, as well as histology. It is obvious that the history of the embryology of the teeth would be incomplete if a record as to the modes by which osseous matter is deposited in the soft formative organs were omitted.

The histological aspects of such a study can alone be included in a work of this character: for the principles of calcification generally readers are referred to the well-known writings of Tomes, Sims Woodhead, etc.

DEVELOPMENT OF THE ENAMEL

Sir John Tomes and his son, Andrews, Leon Williams, and others have paid much attention to investigating this difficult

question: and it may be repeated here that the absolute truth of the matter is unknown: but the balance of favour rests with those who hold the secretion theory.

The following are brief outlines of various theories:—

Sir John Tomes considered that the enamel is formed by conversion of the ameloblasts. The pronounced extremities of these cells undergo, first of all, certain chemical changes; later on calcification ensues. The central portions of the cytoplasm of the cells calcify later than the peripheral: contiguous cells become united as calcification proceeds.

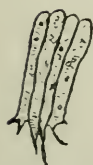

FIG. 238.

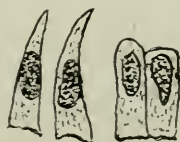

FIG. 239.

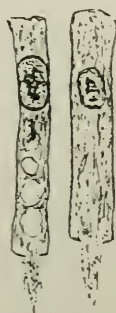


FIG. 240

FIG. 238.—Ameloblasts, with Tomes' processes. (*After John Tomes*)

FIG. 239.—Ameloblasts, two of which have been immersed in glycerine, and present trumpet-shaped ends towards the enamel. (*After Tomes.*)

FIG. 240.—Ameloblasts, showing globular bodies, Tomes' processes, and the spongioplasm of the cells. (*After Tomes.*)

Charles Tomes, in his recent researches on the development of enamel in marsupials, is led to the following conclusions:—

- (i) The ameloblast itself does not become calcified.
- (ii) The chemical and calcareous changes take place in or around a fibrillar process (Tomes' process), which, being continuous with the cytoplasm of the ameloblast, serves for the entire length of an enamel rod, and solidifies equally throughout in the enamel of man and all animals but marsupials and certain others (see p. 96).
- (iii) A tubular condition of the enamel rods is probably merely a stage through which all rods pass during their histogenesis.

Graf Spee¹ was the first to notice and describe globular masses of some kind of calcareous material enclosed in the spongio-plasm of the ameloblasts.

Kölliker (*op. cit.* p. 306) conjectured that enamel rods are produced by a secretion by the cells of the enamel membrane which penetrates the *membrana preformativa* in a fluid condition, but hardens and ossifies beneath it.

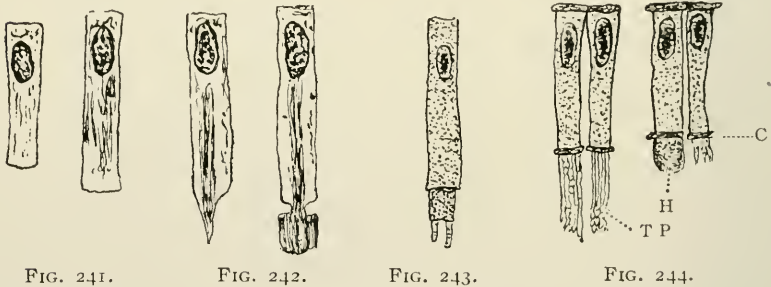


FIG. 241.

FIG. 242.

FIG. 243.

FIG. 244.

FIG. 241.—Ameloblasts prior to the start of formation of the enamel. (After Walkhoff.)

FIG. 242.—The same, with commencement of formation of the enamel. (After Walkhoff.)

FIG. 243.—An ameloblast. (After Waldeyer.)

FIG. 244.—Isolated ameloblasts. H. Homogeneous mass of calcified material, extended from the cell through (C) the enamel membrane by dialysis. T.P. Tomes' processes. (After von Ebner.)

Andrews has shown (*Trans. World's Columbian Dental Congress*, vol. I., 1893) that there is a deposition of droplets or spherules of calcoglobulin formed in the ameloblast, and that these are excreted by these cells at their dentinal ends to build up the enamel rods. The "fibres of Andrews" act as a sort of reticulum or scaffolding to determine the arrangement of the deposition; the existence of these fibres being ultimately blotted out by the dense calcification of the tissue.

G. Arnell in "*Zur Kenntniss der Zahnbildenden Gewebe*" in Retzius' "*Biologische Untersuchungen herausg.*," II., demonstrated, as long ago as 1882, that the inner ends of the

¹"Ueber die ersten Vorgänge der Ablagerung des Zahnschmelzes."—*Anat. Anzeig.*, 1887.

ameloblasts are directly concerned with the formation of the enamel rods, a finely granular deposit occurring round these ends.

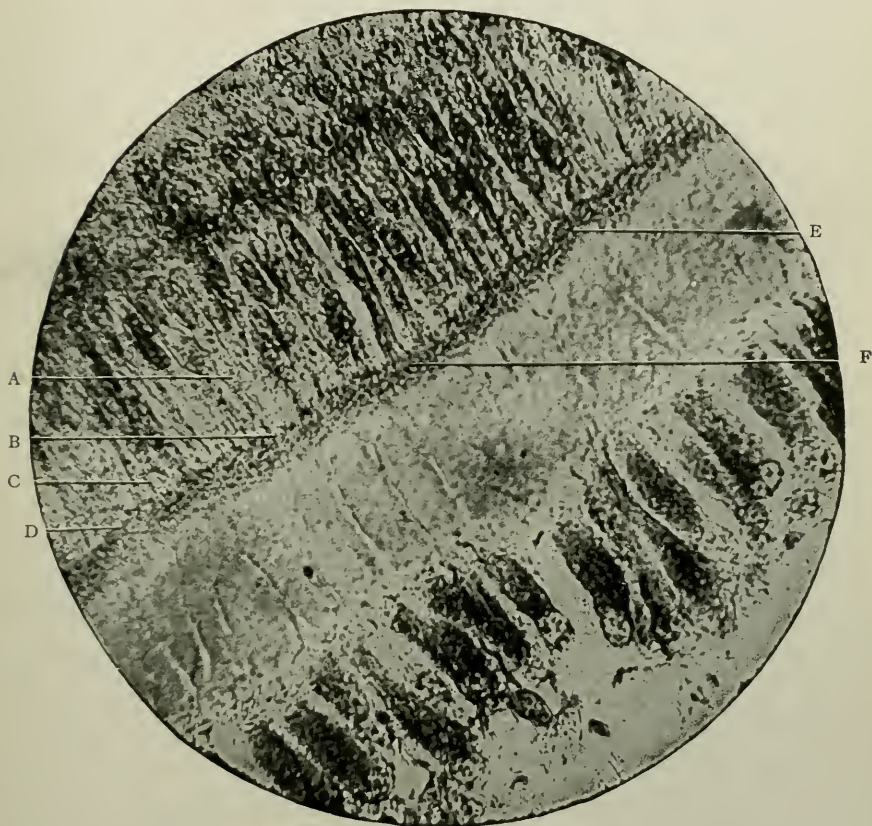


FIG. 245.—Section of developing tooth of a calf, at the commencement of enamel formation. Magnified 1,000 times. It is clearly seen that the organic substructure of enamel and dentine is formed from the cytoplasm of the cells. A. Cytoplasmic network in ameloblast; B. C. D. E. Globular or spherical patterns of cytoplasm. Radiating lines are seen to pass from a central mass to a rim which bounds the circumference, thus resembling nuclear structure. A like appearance is shown in the completely formed enamel rods. F. Shows the cytoplasm of an ameloblast passing without break of continuity into the forming enamel. (Photomicrograph by Leon Williams.)

Heitzmann and Bödecker consider that the ameloblasts “break up” into “embryonal corpuscles,” which afterwards become calcified.

Xavier Sudduth thinks that the ameloblasts excrete the enamel. He is more concerned with the problem whence they get their nutritive supply, and suggests that the calcium salts are stored up in the meshes of the *stellate reticulum* of the enamel organ, which thus furnish material for the first formed layer of enamel.

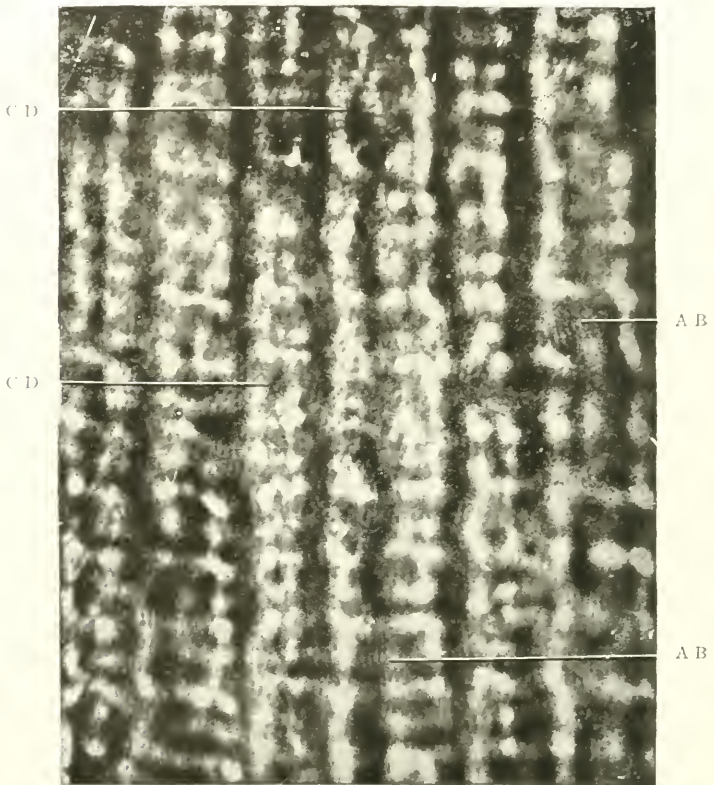


FIG. 246.—Section of mature human enamel of fine quality. Magnified 3,000 times. A.B. Calcified cytoplasmic network composed of very fine granular threads of fibres; C.D. Enamel rods built up of sectional or globular arrangement of calcified cytoplasm. Radiating granular threads pass from a central mass to the border of the sectional part of the rod. (Photomicrograph by Leck Williams.)

After this is laid down, the enamel organ having disappeared from over this calcified layer, a further supply of calcium salts is provided by a rich plexus of capillaries which is found in direct communication with the ameloblasts.

Leon Williams holds views on somewhat similar lines. According to him, the *stratum intermedium* absorbs from the capillaries an albumen-like substance. This is ingested by the ameloblasts, which transform it into enamel globules, and so form the rods. Globules are successively produced within the ameloblasts.




FIG. 247.—Section of mature enamel, showing calcified cytoplasmic network at A, B, and C. Magnified 1,500 times. Compare Fig. 245. (Photomicrograph by Leon Williams.)

“The cytoplasm,” he writes, “of the ameloblasts has a fairly uniform structure, which consists of a number of globular masses of spongioplasm of the same diameter as the cell, and united longitudinally by somewhat coarser plasm-strings—‘the fibres of Andrews.’” “There are many indications that these enamel globules are formed by the nucleus of the amelo-

blast; and they appear to pass down the cell by the natural process of growth, as new ones are formed above, to be finally shed off the inner ends of the cells on to the surface of the forming enamel, where they become completely infiltrated with the albumenoid lime-conveying substance, and calcified. Enamel globules are of uniform size, and quite distinct from the more transparent and irregularly sized masses of calco-globulin." "Enamel rods are manufactured by successive, rhythmical, orderly deposits of these enamel globules, the calcoglobular masses fusing and forming the interprismatic substance."

He finally further adds (*The Dental Cosmos*, p. 477, *June*, 1896):—"There are two distinct products of the enamel-forming organ. One of these products, from which the enamel rods are built up, is formed by the ameloblasts, and is probably a direct nuclear formation. In the enamel cells it takes the shape of globular bodies containing granules, sometimes arranged with more or less order, so as to resemble the nucleus of the cell. In the formed enamel rod these globular bodies are, more or less, compressed into disc-like shapes, and are sometimes nearly, or quite, melted into one another. Simultaneously or alternately with the deposit of the globular bodies, a translucent albumen-like appearing substance is seen passing out of the ameloblasts. This substance is probably taken from the blood by the secreting cells of the *stratum intermedium*, and evidently contains the mineral matter of which the completed enamel consists. As the globular bodies pass from the ameloblasts they are seen to be connected by plasmic strings, which strings can often be plainly seen in the body of the ameloblasts. The globular bodies are often connected laterally by strings or projecting processes. Around the skeleton thus formed, which constitutes the real structure of enamel, the albumen-like substance flows, supplying the cement substance, and probably the mineral matter for the calcification of the whole. All of this structure can be plainly seen in mature enamel; but in normal enamel it is everywhere completely calcified, and contains no trace of organic matter."

To sum up: The theories may be classified under three distinct headings:—

- (1) Enamel rods are produced by conversion or transformation *in situ* of the ameloblasts (John Tomes, Waldeyer, Kölliker, &c.).
- (2) Enamel rods are produced by excretion or secretion, from the ameloblasts (Charles Tomes, Leon Williams, Sudduth, Andrews, Schäfer, &c.).
- (3) Enamel rods are produced by growth of the ameloblasts at the end next to the formed enamel, and the new growth in the younger part is calcified as soon as it is formed (Schwann).

The established facts that require no controversy about this intricate matter are quite clear, and seem to be that the layer of formed but uncalcified developing enamel is outside the main body of the ameloblasts; that it has Tomes' processes penetrating it at regular intervals; that it is produced *pari passu* with the first layer of uncalcified dentine against which it is applied; that it is at first *formed* and afterwards calcified; that it stains deeply with osmic acid; and that it chemically resembles keratin, inasmuch as it offers great resistance to destruction by any of the mineral acids.

DEVELOPMENT OF THE DENTINE

Researches as to the methods of formation, calcification, and the growth of dentine are not so beset with the innumerable difficulties attending like investigations with regard to the enamel. Though the first genesis of this tissue occurs at a period of time slightly antecedent to that of enamel, the fact of its continuance after the disappearance of the enamel organ is completed, and the part it plays in the production of the roots of teeth, with or without persistently growing pulps, as a physiological process, make investigation easier. It must likewise be remembered that certain pathological conditions of the pulp (*q.v.*) in which calcareous (dental) masses are developed—pulp nodules, adventitious dentine, etc.—are of fairly common occurrence. Added to this, also, must be the

fact that opportunities sometimes arise of observing the manner of growth of dentine in odontomes, where the fibrous tissue capsule is still in normal anatomical relationship with the hard parts (see Chapter XV, Vol. II).

Hence it follows that recent discoveries have a tendency to prove the fallaciousness of the tenets maintained by Waldeyer in 1870, and also held by Boll, Beale and others, and that, in a

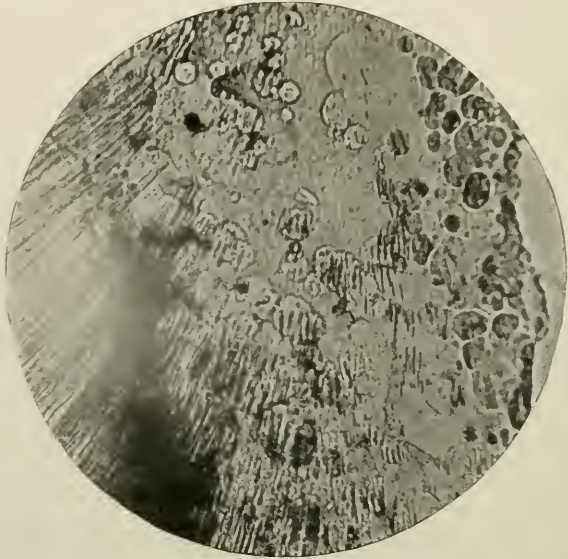


FIG. 248.—To show the process of calcification of human dentine. Regularly arranged tubules traverse the matrix, the sheaths of Neumann being indistinct, till they cross one of the calcospherites in which calcium salts are being deposited. Here they appear as black lines. From a section in the possession of A. W. W. Baker, of a tooth erupted at birth.

word, dentine formation proceeds on somewhat similar lines to those which obtain in intra-membranous ossification of bone. These lines are not quite identical, inasmuch as the so-called odontoblast cells possess persistent processes, and do not become encapsuled as is the fashion with osteoblasts.

Since 1889 the author has never held the view, which had been originally formulated by Waldeyer,¹ that odontoblasts

¹ "Human and Comparative Histology," Stricker's "Handbook;" Sydenham, Soc., Vol. I., p. 463, 1870.

form matrix, sheath of Neumann, and dentinal fibril; and Howard Mummery following up and amplifying the work of von Ebner in tracing throughout the pulp a fine connective tissue stroma which is continuous with that in the dentine matrix, has unconsciously, perhaps, but none the less certainly, corroborated this hypothesis.

Thus there is now established, with a probably great degree of accuracy, the opinion that dentine is a product of certain round cells of the pulp of an osteoblastic nature, whose function it is to abstract lime salts or carbon dioxide, from the vessels of the pulp and lay down matrix as a continuous sheet of formed material on the periphery of that organ. This is found in the teeth of man, as well as fish (vaso-dentines).

Howard Mummery's paper, *Philosop. Trans. Royal Soc. of London*, Vol. 182, pp. 527-545, entitled "Some Points in the Structure and Development of Dentine," should be perused by all interested in the matter. Here it need only be said that his summaries point to the opinions that:—

- (i) The mode of development of hard dentine presents a strong analogy to the development of bone in membrane.
- (ii) In human dentine trabeculæ are seen shooting inwards into the pulp from the surface of the forming dentine; these trabeculæ sometimes exhibiting "an appearance as if stiffened by the deposit of lime salts in advance of the general line of calcification," and being continuous with the connective tissue fibres of the pulp.
- (iii) The fibres and trabeculæ are covered with cells which in many parts thickly clothe them, and have similar functions to osteoblasts. "Smaller cells are intimately associated with the odontoblasts proper, the latter cells being also involved in the connective tissue stroma in continuity with the dentine, and, according to the view which, under the circumstances, seems most reasonable, these cells together secrete a material which calcifies along the lines of the odontogenic fibres" (see Figs. 36, 37, 38, 39, 40 and 41).

Since 1892, when the above was written, Howard Mummery has changed his opinion. In 1913 he contributed to the *Philosoph. Trans. Roy. Soc.* a paper entitled "On the Process of Calcification in Enamel and Dentine," and his new views are based on the assumption of the innervation of the dentine. He does not consider that sensations are transmitted through the dentinal fibrils, and writes as follows:

"The evidences that the odontoblast cells are the principal active agents in calcification of the dentine are, I venture to think, quite as conclusive as the similar evidences of the function of the ameloblasts—a function which has not yet been doubted in their case.

"As nerve-fibres traverse the dentinal canals, the fibril cannot be looked upon as a transmitter of nervous impulses—the cells have granular contents, they lie in a rich plexus of blood-vessels, and we know that active secretion is associated with an increased blood supply; like other secreting cells, they are large and well differentiated from the surrounding tissue elements, and they retain their full size and characteristics during the actual deposition of the dentine in healthy teeth.

"The protoplasmic prolongation of the cell in the form of the dentinal fibril would be considered to share in the functions of the cell of which it forms a part, and there are strong evidences that calcific matter is transmitted by the fibril. The translucent zone in caries, which a great weight of evidence suggests is due to calcification in the tubes, and the peripheral occlusion of the tubes on exposed surfaces, point to this extension of the cell protoplasm being the channel by which lime salts are conveyed to the dentine.

"If I am right in supposing that the sheath of Neumann serves as a dialysing membrane, the comprehension of the process of calcification in the dentine is somewhat simplified. The odontoblast cell, either alone or in common with other cells in the pulp which send processes to the dentine, would deposit the gelatinous basis substance in which calcification takes place—the substance which forms the odontogenetic zone—the lime salts taken up from the circulating blood by the secreting cells would be transmitted by the fibril, and passing by dialysis into

the matrix, lay down the calcifying material in the globular form, slow diffusion of the component salts, such as takes place through dialysing membranes, being an important factor in the production of the calcospherites."

THE GROWTH OF THE DENTINE IN THE RABBIT AND CAT

The following is a *précis* of Aitchison Robertson's experiments and observations on the growth of dentine in the permanently growing incisors and also in the canine teeth of rabbits and cats. They were undertaken to determine whether this tissue increased in size by interstitial growth or not; and the subjoined Tables of measurements and their summaries are exceedingly instructive (see *Trans. Roy. Soc. Edinburgh*, Vol. xxxvi).

METHOD OF INVESTIGATION

"For the purposes of this inquiry the lower incisor teeth of the rabbit were chosen, for these teeth grow from persistent pulps and are therefore never shed. To observe their condition at different stages of growth they were examined in (1) a rabbit newly born; (2) in a rabbit one month old; and (3) in an adult animal. These teeth, while still *in situ* in the lower jaw, were decalcified and sections made in an antero-posterior direction parallel to their long axes. The sections from the very centre of each tooth were alone used for measurement, as they contained the largest pulp cavity and went directly through the centre of the crown. These teeth, as they are worn down in front, are always being added to from behind and thus pushed forwards. The enamel is only found on the anterior and lateral surfaces, and is always thickest in the former position, where also the dentine is harder. Consequently, as the crown of the tooth is worn down, the anterior part, being harder, is not worn so fast, and thus the tooth becomes chisel-shaped.

MEASUREMENTS OF LOWER INCISOR TEETH IN RABBITS

	Newly born	One month old	Adult
Total length of tooth	$\frac{1}{8}$ inch 0.2	$\frac{1}{2}$ inch 0.5	$1\frac{1}{8}$ inch 1.12
Greatest length of pulp cavity.....	$\frac{1}{8}$ inch 0.17	$\frac{5}{120}$ inch 0.43	1 inch 1.0
Greatest breadth of pulp cavity.....	$\frac{1}{50}$ inch 0.033	$\frac{1}{25}$ inch 0.04	$\frac{1}{4}$ inch 0.073
Thickness of dentine at middle of tooth.	$\frac{1}{58}$ inch 0.0063	$\frac{1}{42}$ inch 0.024	$1\frac{1}{250}$ inch 0.044
Greatest thickness of dentine at crown..	$\frac{1}{48}$ inch 0.02	$\frac{1}{12}$ inch 0.08	$\frac{2}{50}$ inch 0.12
Diameter of dentinal tubules at origin...	$\frac{1}{24000}$ inch 0.0000416	$\frac{1}{24000}$ inch 0.0000416	$\frac{1}{24000}$ inch 0.0000416
Width of intertubular dentine.....	$\frac{1}{8000}$ inch 0.000125	$\frac{1}{6000}$ inch 0.000165	$\frac{1}{6000}$ inch 0.000165
Character of dentinal tubules.....	Run obliquely in straight lines; no branches; slightly wider near origin.	Wavy course; not branched.	Wavy course; many branches.

The results of this table may be summarized as follows:—

1. The fact of the great increase in length of the tooth is evident, it being six times longer in the adult than in the newly born rabbit.

2. The pulp cavity increases in length in the same proportion.

3. The width of the pulp cavity increases in a progressive manner.

4. The thickness of dentine at the middle of the tooth and also at the crown increases nearly six times.

5. The diameter of the dentinal tubules at the proximal end remains the same at each stage of growth. They are all slightly larger at their origin and diminish in calibre very gradually as they are traced outwards.

6. The dentinal tubules become gradually more wavy in their course, and their lateral branches become evident in the adult tooth.

“The odontoblasts form a complete lining to the inner surface of the dentine, and thus form, as it were, a bag enclosing the pulp and having its mouth at the inlet of the pulp cavity. Dr. Haycraft suggested that the ring of odontoblasts which forms the mouth of this bag might fitly be called the ‘formative ring,’ because it is apparently here that new dentine is

constantly being formed. The new dentine pushes upwards that previously formed, which carries with it the odontoblasts attached to its inner surface by the dentinal fibrils. The odontoblasts which once composed the 'formative ring' are therefore carried up by the rising dentine, for as soon as each has deposited a little dentine at the extreme base of the tooth, it becomes fixed as a permanent odontoblast and is afterwards lifted up. Fresh cells are continually growing below those engaged in the production of dentine, and thus the existence of the 'formative ring' is continued. From whence do these new cells arise? Are they derived from odontoblasts, or are they derived from the connective tissue cells of the pulp? Dr. Robertson inclines to the belief that they arise from the pulp cells. 'If we trace the layer of odontoblasts, we find that as the dentine becomes thinner so the size of the dentine-forming cells decreases, till at the lower limit of the dentine they are small spindle-shaped cells attached to the dentine by their distal processes. Even below the extreme limit of the dentine we can still follow the line of odontoblasts downwards as a layer of fusiform connective tissue cells, gradually become smaller till they fade imperceptibly into the pulp tissue. There is no line of demarcation between them and the ordinary small round cells of the pulp.'

"The question now is, How are we to explain how the tooth has increased so much in size? There appear to be four processes all at work at the same time in the growing tooth. These processes are:

- (i) Increase in length of the tooth by an addition of new dentine at the lower end of the root. This addition more than compensates for the loss caused by the grinding down of its crown. In adult age, the growth of new dentine and the wearing down balance one another, and the tooth therefore remains of constant length.
- (ii) Increase in width of the tooth by the gradual widening of the "formative ring;"
- (iii) A slight interstitial increase in the dentine, causing

the formation of an increased amount of matrix between the tubules. This interstitial increase appears only to occur in the very young tooth.

- (iv) As the tooth grows, new layers of dentine are deposited on the inner surface of the already existing dentine. This deposit is probably due to the influence of odontoblasts, since they are concerned in the production of dentine from the beginning.

“As the entire tooth is pushed onwards by the growth of new dentine at its lower end, the crown is continually being worn down in grinding. The upper end of the pulp cavity is very narrow and contracted, owing to the large amount of dentine which has accumulated on its surface, for in this situation the dentine is of oldest date and so is thickest. Unless provision were made to prevent it, the pulp cavity would soon become exposed by reason of the grinding down of the crown. It is here, however, at the upper part of the pulp cavity, that the dentine reaches its maximum thickness, and so reduces the diameter of the pulp cavity, that it persists only as a fine channel of considerable length leading from the pulp cavity to the free surface of the tooth. Osseous tissue is developed in this channel, which, together with many small round cells and capillaries, prevents any direct communication between the surface of the tooth and the pulp. No odontoblasts remain in this connecting channel; therefore, since the dentinal fibres in the crown of dentine have lost their connection with nerves the grinding surface of the rabbit's incisor has lost sensitivity. These laminae of bone which help to block up the remains of the pulp-cavity at the apex of the tooth may be part of the layer of cement which, in the persistently growing teeth of many animals, covers over the crown of the tooth, and which may when worn away sink into the almost occluded apex of the pulp-cavity and grow there. It may, however, be developed directly from the tissue of the pulp.

“In the adult rabbit's tooth, then, the growth of dentine at the ‘formative ring,’ the continual deposition of new dentine on the inner surface of the old, and the extent to which the tooth is worn down externally, exactly balance one another,

and thus the tooth remains of the same size throughout life. In the young growing animal, however, the first two of these processes exceeds the third, and so the tooth grows greatly in length, diameter, and thickness of dentine.

“Having seen how a simple conical tooth increases in size, the next question which naturally arose was, How do flask-shaped teeth, such as the canine tooth of a cat, increase in size? To answer that question, the canine tooth of the lower jaw was examined in (i) a newly born kitten; (ii) in a kitten of one month old; and (iii) in the adult cat. These teeth in the cat, as in all *Carnivora*, are shed at an early period of existence. This introduces a slight fallacy, for it compels one to compare deciduous with permanent teeth.

MEASUREMENTS OF LOWER CANINE TEETH IN CATS

	Newly born	One month old	Adult
Total length of tooth..	$\frac{1}{2}$ inch 0.196	$1^8\frac{3}{500}$ inch 0.366	$5^9\frac{1}{100}$ inch 0.59
Greatest length of pulp cavity.....	$\frac{9}{50}$ inch 0.18	$\frac{8}{25}$ inch 0.32	$\frac{1}{2}$ inch 0.5
Greatest breadth of pulp cavity.....	$\frac{3}{125}$ inch 0.056	$3^7\frac{1}{500}$ inch 0.074	$\frac{1}{25}$ inch 0.04
Thickness of dentine at middle of tooth...	$\frac{3}{1200}$ inch 0.006	$\frac{9}{250}$ inch 0.036	$\frac{3}{50}$ inch 0.06
Greatest thickness of dentine at crown....	$\frac{1}{60}$ inch 0.0166	$2^3\frac{3}{500}$ inch 0.046	$\frac{9}{100}$ inch 0.09
Diameter of dental tubules at origin.....	$\frac{1}{17000}$ inch 0.0000589	$\frac{1}{17000}$ inch 0.0000589	at base $\frac{1}{2000}$ inch 0.000833 at crown $\frac{1}{27000}$ inch 0.00037
Width of intertubular dentine.....	$\frac{1}{4250}$ inch 0.000235	$\frac{1}{4250}$ inch 0.000235	at base $\frac{1}{4250}$ inch 0.000235 at crown $\frac{1}{6000}$ inch 0.000166

This table shows that (i) The lower canine tooth of the adult cat is fully three times as long as it is in the newly born kitten.

- (ii) The pulp cavity grows longer in the same proportion.
- (iii) As regards the width of the pulp cavity, it seems first to increase in breadth, but in the adult tooth the breadth is less than in the newly born kitten.

- (iv) At the middle of the tooth the dentine increases to a thickness ten times greater than in the newly born kitten; while at the crown it increases to about six times.
- (v) The diameter of the dentinal tubules was the same in the young kittens. In the adult cat, however, the tubules at the base of the tooth are one-half larger than those of the younger cats; but near the crown their diameter decreases greatly, being a half less than in the younger cats, and even two-and-a-half times smaller than at the base of the same adult tooth.
- (vi) The width of the intertubular substance remains the same in the canines of kittens and also at the base of the adult tooth. At the crown of the adult tooth, however, it is only three-fourths of the breadth of what it is at the root, or in the younger teeth.

“Before describing how this tooth grows, particular attention must first be directed to a fact on which the importance of this inquiry rests, viz., this, that the canine tooth of young kittens is not flask-shaped, but merely conical, resembling the extinguisher of a candle, the sides sloping downwards and outwards from the crown. This originally conical tooth increases in size as follows:

1. By the gradual dilatation of the ‘formative ring’ of cells at the base of the dentine it is increased in diameter.

2. It is increased in length by the addition of new dentine at the base of the tooth and the consequent elevation of the whole tooth. This also is due to the action of the *formative ring*.

“These two processes go on simultaneously, and so the base of the tooth is always growing larger while the tooth is growing in length. This outward extension of the basal *formative ring* of odontoblasts goes on till a maximum is reached. This broadest part of the pulp in the growing tooth of the kitten is at the base, while in the adult cat it remains about the middle of the tooth. Thus in the newly born kitten the broadest diameter of the pulp cavity was at the base of the conical tooth, and measured 0.056 inch. In the kitten one month old, the basal diameter of the pulp was still the greatest, the tooth

still being conical, and measured 0.074 inch. It had not yet become flask-shaped, but about this time the pulp cavity attains its greatest breadth and afterwards diminishes. The elongation of the tooth still continues, but the *formative ring* now gradually contracts, and thus forms an inverted basal cone and so leads to the production of the flask. The narrowing of this basal ring continues until, in the adult, it becomes a small ring surrounding the vessels and nerves going to the pulp. The elongation of the tooth has also caused its broadest part to be situated about midway between crown and base. Thus the tooth is made up of two cones joined at their bases, the 'crown-cone' being formed by a dilatation of the 'formative ring' and the 'root-cone' by the gradual narrowing of the ring.

"3. During the whole time that the tooth is growing in length, a constant deposition of new dentine is taking place on the inner surface of the old. Thus the maximum diameter of the pulp cavity in the young tooth becomes lessened, till, in the adult, the original pulp cavity is much reduced in size compared with its width in the newly born kitten. Having reached this stage the processes of growth cease, and thus a typical flask-shaped tooth is produced. We see now how the apparent anomaly regarding the width of the pulp cavity arises. From the table we find that the width of this cavity is less in the adult tooth than it is in the new-born kitten. This is due to the large deposit of new dentine on the inner surface of the old, causing such a narrowing of the pulp cavity that the above condition is produced.

"4. It is also shown that there has been an interstitial change. The dentinal tubules are smaller and closer together near the crown of the adult tooth than near the base. At the base the amount of intertubular dentine remains the same as it is in the younger cat's tooth, though the tubules themselves are a good deal larger in diameter than in the earlier conditions.

"Regarding root-formation, we have seen how a single rooted tooth, as the canine, is developed by the gradual narrowing of the basal dentine-forming ring. If, however, this *formative ring*, having reached its maximum dilatation, becomes constricted at two opposite points till these meet like a

figure-of-eight, then two smaller *formative rings* are produced. If these both go on forming dentine and diverging from one another, we have two 'root-cones' produced, springing from one body and giving us a double rooted tooth. In a similar manner, if the *formative ring* becomes sub-divided into three or four rings, we have a three or four rooted tooth resulting. The tooth capsules themselves, even of the molar teeth, are quite simple and show no indication of roots. It is only after the body of the tooth has been completed that the roots are produced.

"This inquiry shews that the growth of a tooth is only to a very slight extent interstitial. Interstitial growth is seen in the incisor tooth of the rabbit, where the dentinal tubules become further separated by an increase of dentinal matrix, but this appears to take place only in the young tooth. Probably it causes a slight increase in the size of the rabbit's tooth. In the cat, however, it does not cause any increase in the size of the tooth; the width of the intertubular substance remains the same. It is only in the upper part of the adult tooth that the tubules are smaller and more closely packed. All we can affirm in this case is that the interstitial increase of the matrix simply encroaches on the size of the tubules and so does not cause any increase in the size of the tooth.

EXAMINATION OF THE TEETH OF YOUNG RABBITS FED ON MADDER

While working at this subject Professor Haycraft gave Dr. Robertson the teeth of three young rabbits which had been fed on madder for a fortnight. He carefully examined these, as he thought they might throw some light on the mode of growth in teeth.

I. The first rabbit was killed after being fed on madder for two weeks. All the stained part of the tooth is that produced while the madder was added to the food. In the section, this staining reached the very crown of the tooth, but only at the centre. This clearly demonstrates that there is a constant deposit of new dentine on the inner surface of the old. At the apex of the pulp cavity the colour is deepest, for most of the

new dentine was deposited in that situation. It is also seen that there is a narrow band of stained dentine which immediately surrounds the pulp. These teeth also shew that the incisor teeth increase in length much more rapidly than the others; for, while the incisor is stained in three-fourths of its length, the premolar is stained in only half its length.

II. The second rabbit was fed for two weeks on madder, and then on ordinary food for a similar period. The lower part of the incisor tooth, and also a narrow strip of dentine surrounding the pulp cavity and extending up to the grinding surface, is now unstained. This is all new dentine, formed during the last two weeks of the animal's life. In the premolar the axial staining is hardly yet worn away. The deeper staining of the dentine on the concavity of the incisor may be due to the more rapid growth which there is in this situation, and the greater consequent absorption of the circulating stain.

III. The third rabbit was also fed on madder for two weeks, then on ordinary food for three weeks. The teeth shew merely a further development of what No. II. did. These madder-stained teeth corroborate entirely the explanation of the growth of the dentine which has been already given.

The results of this investigation into the growth of teeth may be thus summarised. There is:

1. Increase in the length of the tooth by addition of new dentine at its base;
2. Increase of diameter by dilatation of the basal *formative ring*. In the case of teeth with roots, these are produced by the gradual contraction of this ring with or without subdivision;
3. Deposit of new dentine on the inner surface of the old;
4. A slight increase in the matrix of the dentine by interstitial growth.

THE GROWTH OF THE INCISOR TEETH OF THE ALBINO RAT

This has been carefully studied by Drs. W. H. F. Addison, and J. L. Appleton, Jr., of the University of Pennsylvania, Philadelphia, who in an elaborate paper, "The Structure and

Growth of the Incisor Teeth of the Albino Rat," *Journal of Morphology*, Vol. 26, 1915, have arrived at the following conclusions:

"The rate of growth of the upper and lower incisor teeth of *Mus norvegicus albinus*, in the mature animal, averages 2.2 and 2.8 mm. per week, or 12.5 cm. and 14.5 cm. per year, respectively.

"Growth is due primarily to the proliferation and growth of cells at the basal end of the enamel-organ, where new enamel-forming cells arise, and at the basal end of the dental papilla where new dentine-forming cells develop.

"The enamel-organ of the adult forms a narrow circular band around the basal end of the tooth, and extends forward from this on the labial side only. It coincides in its lateral boundaries with the enamel, and extends along the entire imbedded portion of the tooth. Anteriorly, it comes in contact with the epithelium of the gingival margin, and is carried out continually as a narrow band of cells lying on the enamel, between the latter and the gingival epithelial tissue.

"The first indication of the tooth band of the incisors appears in 14-day-old fœtuses. In fœtuses 21 days of age (just before birth), enamel and dentine formation is beginning. In animals 1 day old the upper and lower teeth measure 2.3 and 3 mm. At 8 to 10 days the teeth erupt, and at 10 days measure 7 and 11 mm. respectively. This period is therefore characterised by the rapid elongation of the teeth.

"The process of attrition begins within a few days after eruption, so that by 19 or 21 days of age, the typical occlusal surface is formed. Up to the time of eruption the anterior end or apex of the tooth is immediately under the oral epithelium, while the basal or growing end is continually progressing posteriorly. After eruption, the basal end becomes nearly stationary in position, while the whole tooth structure is continually moving forward. The extra-gingival length of the tooth is kept constant, however, by the attrition of the occlusal surface, either through use in gnawing or by the action of the opposing teeth.

"The histogenesis of the enamel-organ is practically completed by the fourth day after birth, although it does not attain

its final relations to the tooth as a whole, until after eruption. In the 18-day foetus the enamel-organ is similar in all parts, and the cells of the inner layer measure the same, both lingually and labially. From this period forwards, however, the labial portion continues to progress towards its fully differentiated functional structure, while the lingual portion retrogresses, until at 4 days after birth the latter is disrupted, by the ingrowth of the surrounding connective tissue. Contrasting the cells of the inner layer—the potential ameloblasts—on the labial and lingual sides, they are practically the same in the 18-day foetus, but at 19 days they are found to measure 24 and 20 μ respectively. In the 21-day foetus, they measure 30 to 34 and 12 μ , and 1 day after birth the true ameloblasts on the labial side have increased to 40 μ , while the non-functional cells of the lingual side are only 10 μ in height. At 4 days, the latter cease to form a continuous layer, by reason of the dispersion of the cells by the surrounding connective tissue, except at the basal formative region.

“Characteristic of the permanently-growing enamel-organ are the epithelial papillæ, formed by the elevations of the outer layer of the enamel-organ, and the cells of the enamel pulp. Between these elevations are numerous capillaries which insure a rich blood supply to the enamel-forming cells.

“There are three layers in the functional enamel-organ—inner, middle and outer. The inner is constituted of the tall ameloblasts, and the middle is made up of two divisions, (a) *stratum intermedium* and (b) enamel pulp. The latter unites with the single layer of cuboidal cells which compose the outer layer, to form the epithelial papillæ.

“The apex of the primitive tooth is formed of a variety of secondary dentine—‘osteo-dentine’ of Tomes—which is softer than true dentine, and differs in its structural arrangement. After eruption, this terminal portion of osteo-dentine is soon worn away by attrition, and the typical occlusal surface is developed, as seen at 19 or 21 days. At 21 and 23 days the first two molars erupt in both upper and lower jaws, and from now on, the animal is able to secure food for itself, and if necessary can maintain an independent existence.

“As the tooth continues to be worn away there is a provision for the continual filling in of the apex of the pulp-chamber by the formation of what may also be called osteo-dentine. This is a form of secondary dentine, containing, when first formed, cells and blood-vessels. This is always at a little distance, about 1 mm., from the occlusal surface, but as any part of the tooth, in its outward progression approaches the occlusal surface, the soft elements disappear within the osteo-dentine, and the latter forms a hard continuous surface with the adjoining true dentine. The position of this osteo-dentine is marked as a line on the occlusal surface of the teeth.

“Prior to eruption there develops around the apex of the tooth, as it lies in contact with the surface epithelium, a thickened ring of stratified epithelium. This ring of tissue is pierced by the apex (*i.e.*, cutting or incisive edge) of the tooth at eruption, and would seem to have the function of serving as a resistant margin for the soft tissues, and of preventing other tissues being carried along with the erupting tooth.

“The length of the teeth varies with the size of the cranium, so that the persistent growth is not only sufficient to offset the continual attrition, but also serves to keep the length of the teeth in a definite relation to the length of the skull, as the latter increases in size.

“The lower tooth is always longer than the upper, and this difference manifests itself even in the tooth-bands of these structures in the 19-day fœtus.

DEVELOPMENT OF THE CEMENTUM

Of this there need be but little said; mere repetition of descriptions of phenomena which are probably now understood with the greatest certainty, is needless. Suffice it to say, that there is every reason to believe that cementum is developed ordinarily after the manner of intramembranous ossification of bone. Where thick layers of the tissue exist over the crowns of teeth, Magitot's opinion that development and ossification in a cement organ of fibro-cartilaginous character is most probably accurate.

THE STAGES OF DEVELOPMENT OF THE JAWS AND TEETH IN A
HUMAN EMBRYO OF HALF-TERM

For the purpose of investigation, and in order to put on record a careful account of the degrees of development arrived at, at a certain period of growth, the right half of the upper jaw of a human foetus of about 20 to 25 weeks was employed.

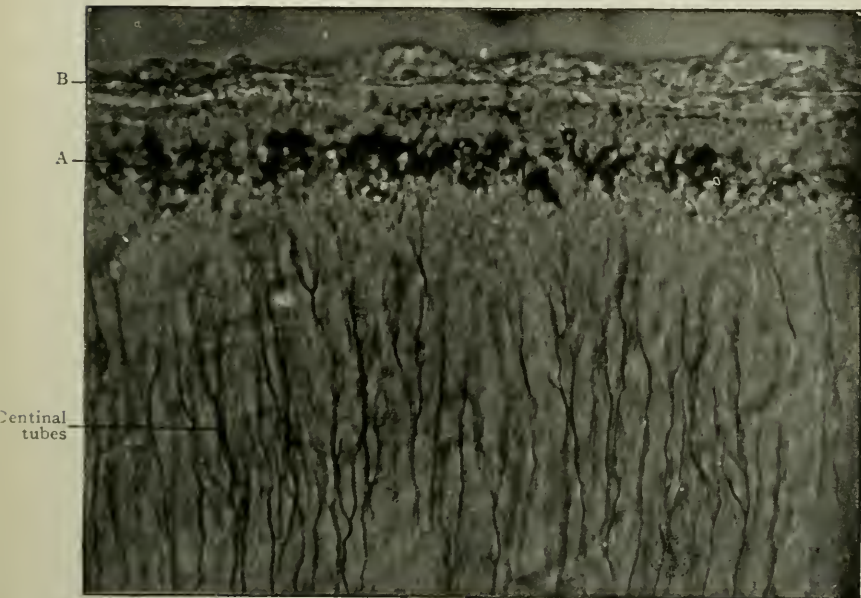


FIG. 249.—To show an early stage in calcification of cementum. Magnified 500 times. A. Granular layer of Tomes partly calcified; B. Young cementum. (Photomicrograph by Norman Broomell.)

This was apparently absolutely normal, and, as far as could be ascertained, believed to be unaffected by rachitis, syphilis, etc.

The jaw was subdivided into seven sections, beginning at the front, in a sagittal, and behind, in a coronal direction, and included the following regions, enclosing deciduous teeth:—1, first incisor; 2, second incisor; 3, canine; 4, anterior molar; 5 and 6, posterior molar, and 7, behind the posterior molar, near the maxillary tuberosity. The latter showed no dental

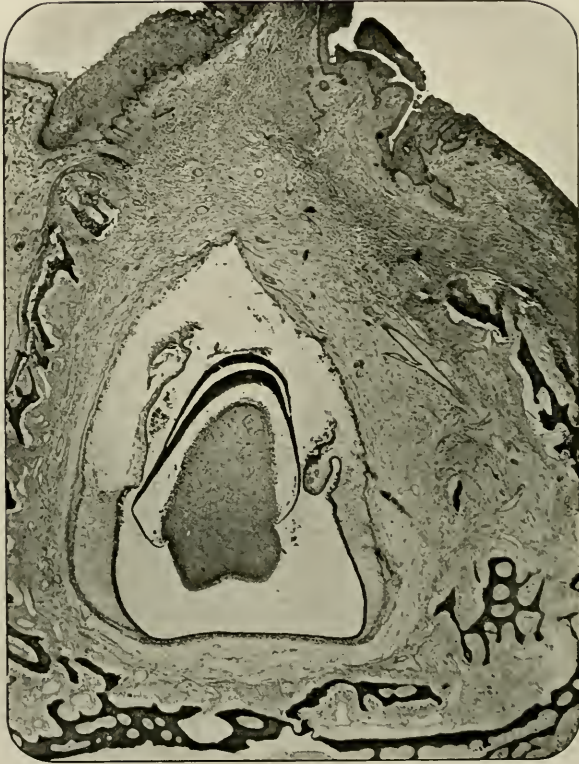


FIG. 250.—From region of first maxillary deciduous incisor. Magnified 30 times. For description of this and following figures, see Tables A. and B. on pp. 306 and 307.

structures whatsoever. The figures at the heads of the following columns indicate these various regions (see pp. 306 and 307).

Carefully decalcified and embedded in paraffin, the tissue was cut serially, and typical mesial vertical sections selected

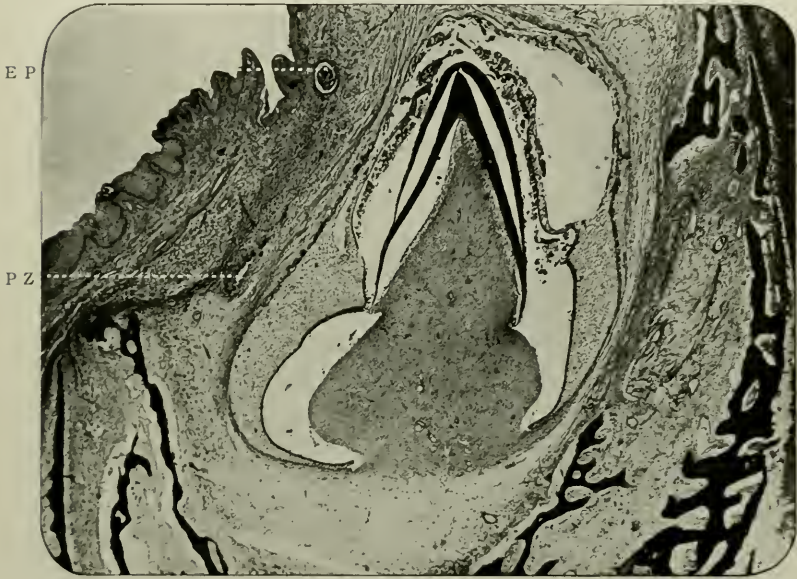


FIG. 251.—From region of second incisor as in preceding figure. Magnified 30 times. P.Z. Permanent tooth germ; E.P. Epithelial "Pearl" or "Gland of Serres."

for pictorially and verbally illustrating the phases of development. It will be observed that in consequence of the action of reagents some shrinkage of the embryonic dentine germ has taken place. To prevent tautology, brief tables only need here be introduced.

THE HISTOGENESIS OF OVARIAN TEETH

Not much is known as to the development of those anomalous misshapen dental structures found in the oöphoronic cysts of the human ovary. Sir John Bland-Sutton has, however, ex-

TABLE A.—GENERAL APPEARANCES

	1	2	3	4	5	6
Enamel.....	Thick cap; extends more than half way down side of dentine.	Thick investment; reaches nearly to base of dentine.	Spear-like point.	} As in 3.	None.	None.
Dentine.....	Thick investment; meets dentine papilla at junction of lower and middle third.	Thick cap over apex.	Slender cap.		First traces.	None.
Enamel organ.....	Continuous around tooth germ.	Narrow; tooth band of permanent tooth germ just discernible.	Broad; discontinuous at base of tooth germ. Tooth band of permanent tooth germ bulbous.	Narrow; tooth band of permanent tooth germ visible.	Wide; broad; trace of tooth band of permanent tooth germ.	Semilunar in shape.
Dentine papilla.....	Conical in shape; very embryonic; capillaries ill defined.	Triangular in shape; vessels assuming usual characteristics.	Triangular with smaller triangle over apex; very embryonic constituents.	Flat, with two triangular eminences; more structurally developed than 3.	As in 4.	Surface raised in several eminences.
Ameloblasts.....	} Pronounced.	} Pronounced.	} Pronounced.	} Pronounced.	Pronounced.	Immature.
Odontoblasts.....					Immature.	None.
Stellate reticulum.....	Continuous with base of papilla.	Discontinuous around tooth germ.	Broad; large amount.	Broad; flat.	Marked.	Well-formed; nuclei of cells plump and oval.
External epithelium.....	Continuous around tooth germ.	Discontinuous.	Cubical cells, continuous with dental capsule at base of tooth germ; small epithelial "tufts" appear.	Wavy in outline; "tufts" appear.	As in 3.	Ill-defined.
Dentogenetic zone.....	Marked.	Broad near base of dentine.	As in 2.	Marked.	None.	None.
Dental capsule.....	Differentiated.	Differentiated.	Differentiated into outer and inner parts.	As in 3.	No differentiation into two parts.	As in 5.
Maxillary bone.....	Well developed; gutter nearly closed.	Thick; several layers; gutter widely open.	Greatly developed away from oral surface; very wide gutter.	Thick.	Thick at base; gutter narrow.	Largely developed.

TABLE B.—DIMENSIONS OF PARTS, IN MILLIMETRES

	1	2	3	4	5	6
Enamel { (a) thickness.....	0.6	0.12	0.05	0.05	None.	None.
(b) extent.....	1.2	1.75	0.5	0.75		
Dentine { (a) thickness.....	0.12	0.35	0.12	0.15	None.	None.
(b) extent.....	1.4	2.0 (slightly less)	0.8	1.2		
Dentine papilla { (a) width.....	1.1	1.5	1.75	3.75	3.0	1.75
(b) length.....	1.3	2.5	2.0	2.5	1.75	0.75
Enamel organ { (a) length.....	2.8	2.8	3.0	1.75	3.0	1.6
(b) breadth.....	1.75	2.25	2.0	5.0	4.25	1.5
Depth of enamel from free oral surface. . .	3.0	2.6	1.8	2.2	Depth of apex of dentine papilla from free oral surface 3.75	Depth of apex of dentine papilla from free oral surface 5.0
Width of orifice of bony crypts, including tissues surrounding the deciduous and permanent tooth germs.....	3.2	4.0	3.5	3.75	3.75	2.5

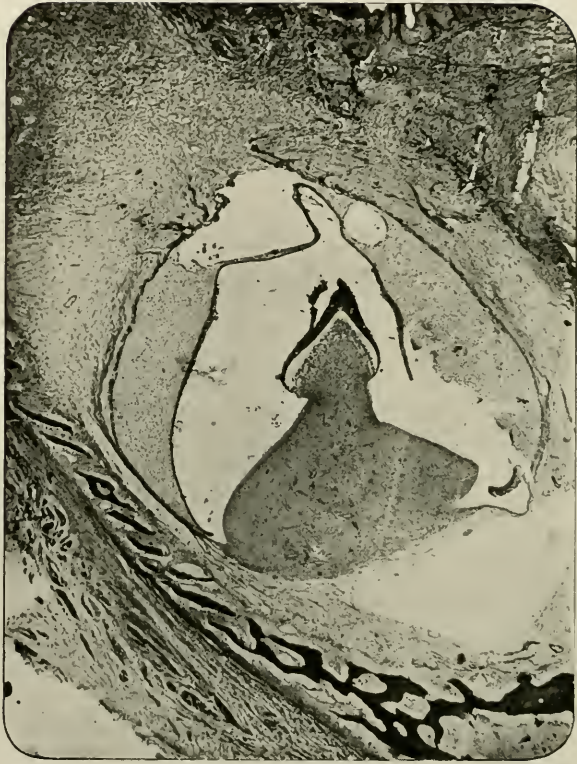

FIG. 252.—From region of canine, as in preceding figure. Magnified 30 times.

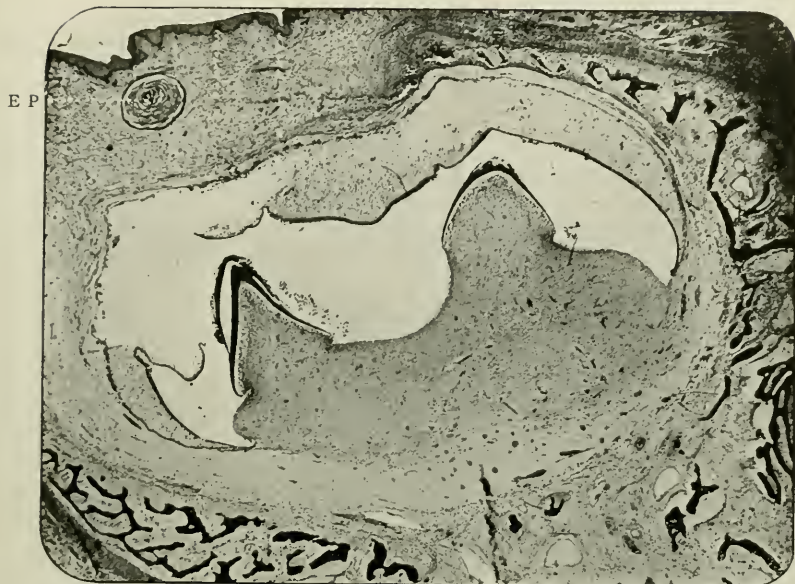

FIG. 253.—From region of deciduous first molar, as in preceding figure. Magnified 15 times. E.P. Epithelial "Pearl" or "Gland of Serres."

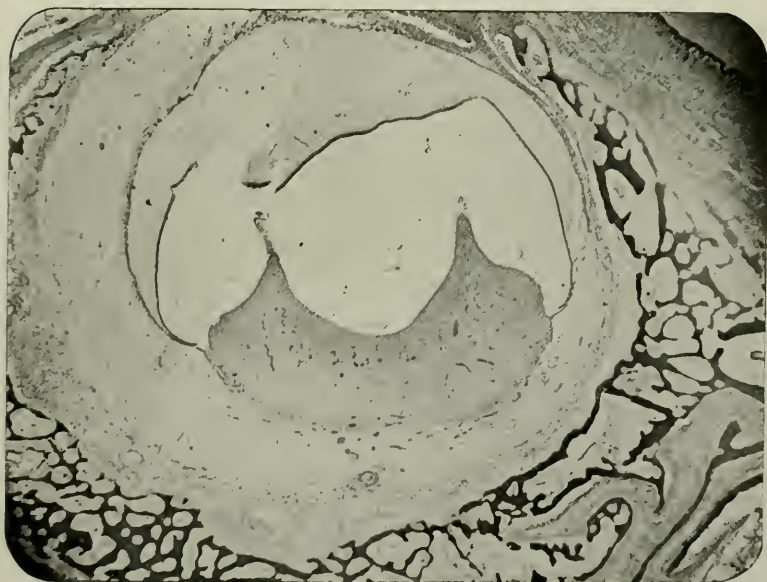


FIG. 254.—From region of deciduous second molar, as in preceding figure. Magnified 15 times.

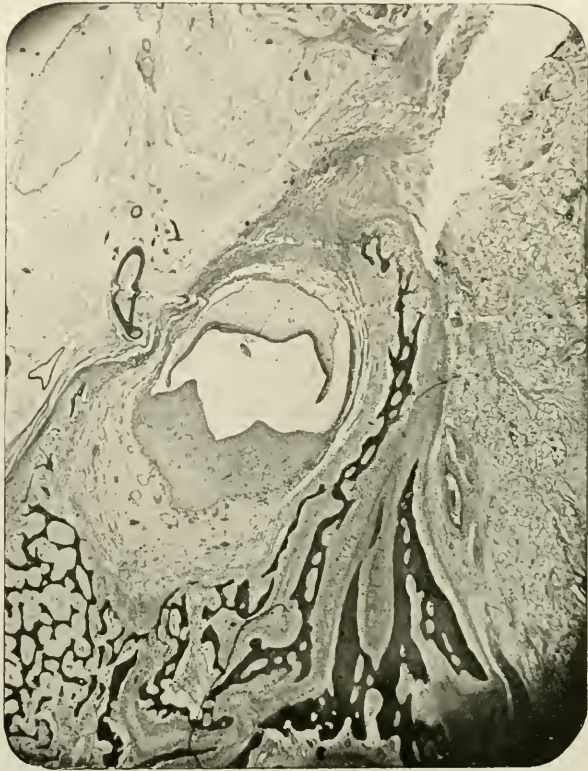


FIG. 255.—From posterior portion of region of deciduous second molar as in preceding figure. Magnified 10 times.

amined many specimens. These are fully described in his "Tumours, Innocent and Malignant," 1906. The accompanying Fig. 256, taken by permission from his work, shows

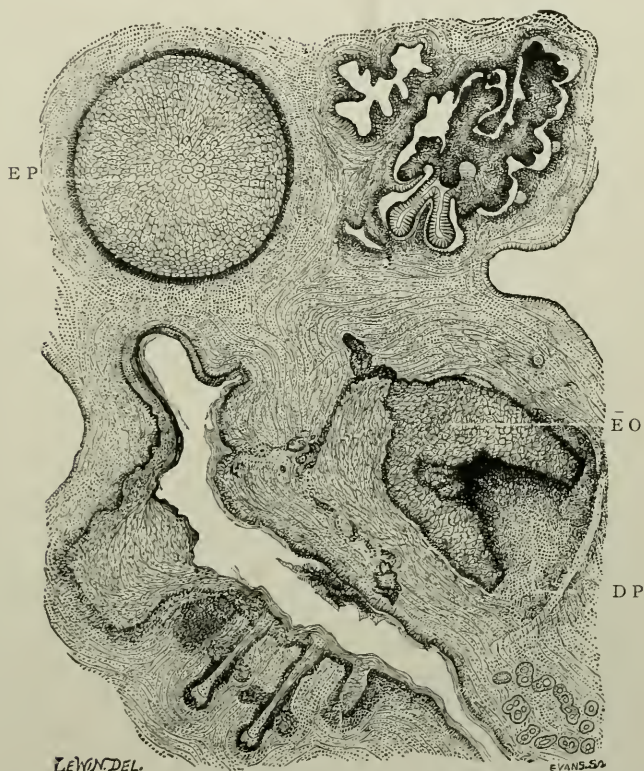


FIG. 256.—Composite drawing of the microscopical appearances in a teratomatous cyst of the ovary. E.O. Enamel organ; D.P. Dentine papilla; E.P. Epithelial pearl.

the component parts in the formation of a tooth. Cf. the "Epithelial Pearl" (E.P.), with the same bodies in Figs. 251 and 253. These are regarded by Bland-Sutton as enamel organs.

CHAPTER XIII

DEVELOPMENT OF THE TEETH IN PISCES, REPTILIA AND BATRACHIA

MICROSCOPICAL ELEMENTS IN: Developing Teeth of (i) Cod; (ii) Dogfish; (iii) Crocodile; (iv) Lizard; (v) Snake; and (vi) Newt.

I

In *Pisces*

Fishes are vertebrate animals which live in water, and breathe the air dissolved in the water by means of gills or branchiæ. The two-chambered heart consists of a ventricle and auricle or atrium. The limbs, excepting in the *Cyclostomata* and *Leptocardii* (which are apodal), are modified into fins, supplemented by unpaired median fins. The skin is either naked, scaly, or covered with osseous plates. Fishes, as a rule, are oviparous.

The class of Fishes is divided into the following:¹—

Sub-class I. Elasmobranchii.

Order 1. Proselachii.

Order 2. Acanthodides.

Order 3. Selachii.

Sub-order 1. Notidani.

Sub-order 2. Squali.

Sub-order 3. Raii.

Order 4. Pleuracanthodes (= Ichthyotomi).

Sub-class II. Holocephali.

Sub-class III. Ostracodermi.

Order 1. Heterostraci.

Order 2. Osteostraci.

Order 3. Pterichthyomorphi (= Antiarcha).

Sub-class IV. Dipnoi.

Order 1. Ctenodipterini.

Order 2. Monopneumones.

Order 3. Dipneumones.

Order 4. Coccosteomorphi (= Arthrodira).

¹ This is the classification adopted (1908) by Sir E. Ray Lankester and Dr. Ridewood of the British Museum (Natural History Department).

Sub-class V. Teleostomi.

Order 1. Stylopterygii* (= Crossopterygii, auct.).

Sub-order 1. Tarrasioides (= Haplistia).

Sub-order 2. Holoptychioides (= Rhipidistia).

Sub-order 3. Cœlacanthoides (= Actinistia).

Sub-order 4. Polypteroides (= Cladistia).

Order 2. Astylopterygii.*

Sub-order 1. Sturioniformes (= Chondrostei).

Sub-order 2. Amiiformes (= Protospondyli).

Sub-order 3. Lepidosteiformes (= Ætheospondyli).

Order 3. Neichthyes (= Teleostei).

Grade A. Physostomi.

Sub-order 1. Salmoni-clupeiformes (= Isospondyli).

Sub-order 2. Cyprini-siluriformes (= Ostariophysi).

Sub-order 3. Symbranchiformes.

Sub-order 4. Anguilliformes (= Apodes).

Sub-order 5. Esociformes (= Haplomi).

Grade B. Physoclisti.

Sub-order 6. Halosauriformes (= Heteromi).

Sub-order 7.—Gastrosteiformes (= Catosteomi).

Division 1. Selenichthyes.

Division 2. Hemibranchii.

Division 3. Lophobranchii.

Division 4. Hypostomides.

Sub-order 8. Mugiliformes (= Percosoces).

Sub-order 9. Gadiformes (= Anacanthini, in part).

Sub-order 10. Acanthopterygii.

Division 1. Perciformes.

Division 2. Scombriformes.

Division 3. Zeorhombiformes.

Division 4. Kurtiformes.

Division 5. Gobiiformes.

Division 6. Echeneiformes (= Discocephali).

Division 7. Triglififormes (= Scleroparei).

Division 8. Blenniiformes (= Jugulares).

Division 9. Trachypteriformes (= Tæniosomi).

Division 10. Mastacembeliformes (= Opisthomi).

Sub-order 11. Lophiiformes (= Pediculati).

Sub-order 12. Balistiformes (= Plectognathi).

It is unnecessary, in a work of this character, to give more than a brief outline of the manner in which the teeth of Fishes are evolved. The simplicity of the process is remarkable

*These are often spoken of as "Ganoid Fishes."

and of interest, especially when the development and succession of teeth in *Mammalia* have been studied.

Two examples need only be here detailed.

One occurs in the *Teleostomi*, the other in the *Elasmobranchii*.

In *Teleostomi*

Example.—Order—*Neichthyes*. Sub-order—*Gadiformes*, in the division *Gadidæ* (Cod-fishes).

The simplest arrangements of parts are well exhibited in the jaws of young Cod-fishes of about 10 cm. body length. *Gadus luscus* may be taken as a type.

Under low powers the oral epithelium is very remarkable for its depth and strength; its thickness may exceed that of the sub-mucous tissue. The free surface is somewhat thrown into wrinkles or folds. The deeper layer of cells is of the usual columnar shape. The submucous tissue extends into the former in the shape of many narrow numerous papillæ.

The tooth germs, originating *de novo*, are developed in the tissue which fills a papilla, which, with the growth of the germ, becomes widened and flattened.

Minute Structure of Tooth Germ.—There is no tooth band and no heaping up of epithelium. An ill-constituted enamel organ exists, the *stellate reticulum* of which is of a rudimentary character, consisting merely of strands of fibres; no cells and no nuclei fill the inter-spaces. The ameloblasts are short cylinders with large oval nuclei separated from a well-defined *stratum intermedium* by a clear narrow zone.

The odontoblasts are prominent. At the base of the dentine germ, the mesodermic cells about to form the pulp are sharply differentiated from the underlying structures, and no dental capsule, as such, occurs. The odontoblasts of mature teeth are rounded or flattened, adhering closely to the dentine, and in a striking way resembling osteoblasts. They are not distinguishable from the pulp cells in any other particular than their position. These same cells in younger teeth shew transitional changes from these round forms to long cylindrical cells, whose nuclei are not particularly marked.

In the *Gadidæ* (e.g., *Gadus Morrhua*) Röse¹ describes the odontoblasts as extraordinarily long and thin cells in the young tooth rudiments. But Fig. 3, which accompanies his paper, shews the cells to be longest and thinnest over the deepest base of the dentine, and gradually diminishing in length and width as they approach the cutting edge.

In every section of *Gadus luscus* prepared by the author this is not the case. The cells half-way down the young tooth

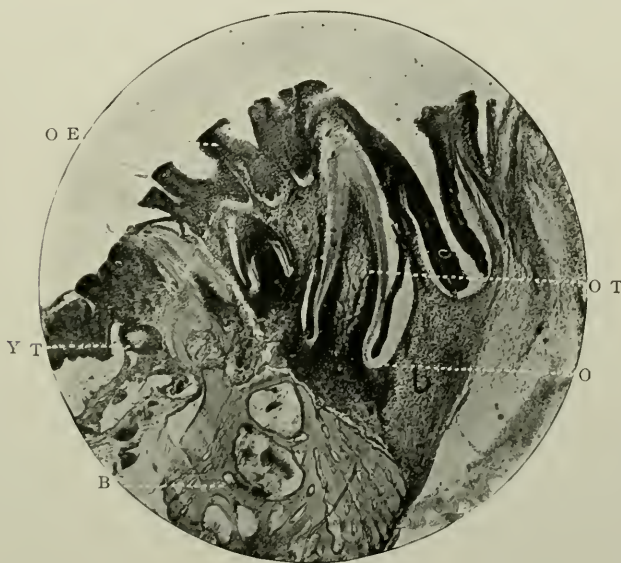


FIG. 257.—Vertical section through jaw of a young cod fish. Prepared by hardening and decalcification. Stained with Ehrlich's acid hæmatoxyline. Magnified 50 times. o.t. Oldest tooth germ; o. Odontoblasts, in several layers, at base of tooth; y.t. Youngest tooth germ; o.e. Oral epithelium; b. Bone of the jaw.

germs are the largest, those at the oral edge and at the base smaller and rounder, till at the extreme limit of the developing pulp, they are flat and scale-like and adherent to the dentine. Inspection of the photomicrograph, however, at first sight would seem to indicate that Röse's description is correct.

¹ "On the Various Alterations of the Hard Tissues in the Lower Vertebrate Animals." Translated from the *Anatomischer Anzeiger*, in the *Journal Brit. Dent. Assoc.*, Jan., 1899.

But the appearances here produced are due to *several layers of small cells*, which become curiously congregated in this way. The chief point is that the *nuclei* are in no sense of the word increased or elongated.

In structure the dentine is *vitro-dentine*, according to Röse. (For the meaning of this term see p. 108). In the cases just noted it (the dentine) possesses no canals, scanty tubes, but faint laminations. The tooth germs move in an outward direction, and when fully completed are found perched on the pedestal of bone known as the "bone of attachment."

In *Elasmobranchii*

Example.—Order—*Selachii*; sub-order—*Squali*; family—*Scylliidæ* (Dogfish).

Specimens of *Scyllium caniculum* afford excellent types of the genesis, evolution and eruption of the teeth.

The epithelium of the mouth is not flat, as in *Mammalia*, but is beset with myriads of elevations of microscopic size.

The outermost layers are not particularly cornified.

At varying distances there occur on the outer surface of the lip, the dermal spines, each of which is imbedded by means of a widened broad base in the submucous tissue. In some places their close association causes these spines to become imbricated.

The accompanying photomicrograph shews the remarkable analogy between the teeth and these placoid scales or dermal denticles. In fact, the latter may all be considered modified teeth, differing chiefly in function and positions (see Fig. 258).

In addition to the variation in their positions, these spines are modified in regard to shape, size, and structure.

In form, the greater number which cover the surface of the skin of the animal are flattened plates, with a slightly convex free margin, and wedge-shaped bases securely dovetailed into the firm dermal connective tissue.

On the edge of the jaw the exposed portion becomes rounded and presents a fungiform outline, while at the place of inflexion over the jaw margin it assumes the appearance of the flattened

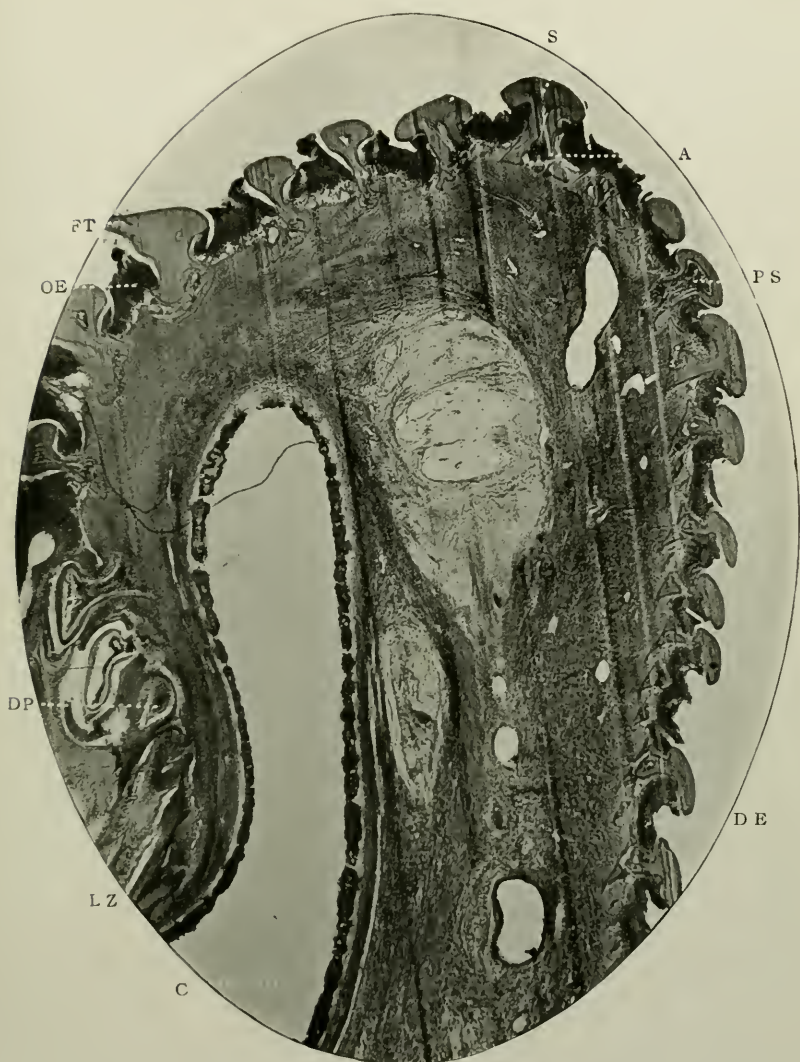


FIG. 258.—Vertical section through the jaw of a young dogfish. Prepared by hardening and decalcification. Stained with borax-carmin and Ehrlich's acid hæmatoxylen. The vertical lines are markings made by a dull razor during cutting on an ether-freezing microtome. Magnified 25 times. c. Cartilage of the jaw, with semi-ossified external crust; d.e. Epithelium of the skin; o.e. Epithelium of the mouth; l.z. Lowest extent of the tooth band; d.p. Dentine papilla of young tooth germ; f.t. Functional tooth; s. Two teeth about to be shed; p.s. Pulp tissue in centre of a dermal denticle. A. Aperture at base of dermal denticle for passage of blood-vessels to the pulp.

head and beak of a bird. In size, the latter are by far the larger.

In structure, each denticle, similarly to each dental organ, possesses a central pulp chamber, filled with abundant round cells and a fairly well organised blood system. The hard parts contain dentinal tubes, which radiate in the usual way.

The epithelium of the mouth is considerably deeper than that of the skin, and extends almost to the base of each tooth; for here, at the oral border, the denticles become teeth in function, being merely transitional in structure. It embraces the teeth very intimately. An aperture at the *side* of the base admits the passage of blood-vessels to the pulp.

The tooth band is continuously growing, and dips down deeply as far as the curved recess of the cartilaginous framework of the jaw. Here, as in the deepest locality, are the youngest teeth germs. This tooth band is of great thickness, and is highly specialised. It extends as a broad column down the side of the jaw cartilage, and in it are the developing teeth.

In the dogfish the deepest layer of the tooth band produces the ameloblasts as in other creatures; and the next deepest layer of cells forms what must be analogous with the *stratum intermedium* of mammalian enamel organs.

Throughout, the deepest layer is composed of long cylindrical cells closely packed together, containing oval or flattened granular nuclei. The external layer is very short and the nuclei are correspondingly abbreviated.

By counter-staining, the young teeth may reveal what is probably a thin superficial band of enamel.

The dentine and the pulps of the teeth are developed from the connective tissue. The cells in the situation of the future dentine papilla become approximated, and in the pulps, while still retaining their rounded forms, can be easily seen to deposit ossific material on the sides of the connective tissue scaffolding of the dentine.

In the interspaces of the developing teeth, the deepest layer is arranged like a loop.

Thus, enamel organs as highly specialised as in *Mammalia*, are non-existent and no dental capsules surround the papillæ.

II

In *Reptilia*

The class of Reptiles is divided into the following orders:—i., *Crocodylia*; ii., *Rhynchocephalia*; iii., *Lacertilia*; iv., *Ophidia*; and v., *Chelonia*. In i. (Crocodile, Garial, Alligator) the teeth are implanted in sockets; in ii. (New Zealand Lizard or *Sphenodon punctatus*) they are ankylosed to the summits of the jaws, the bone at their bases undergoing a secondary upgrowth (hyperacrodont),¹ but are soon lost by attrition, their functions being carried on by the dense free margins of the maxilla and mandible; in iii. (Lizards) they are ankylosed and non-socketed; and in iv. (Snakes) the same; while in v. (Turtles and Tortoises) they are absent.

In *Crocodylia*

The genesis of the teeth in Crocodiles resembles in a marked degree that of mammalian animals. An exhaustive description would be, in the main, little better than a mere recapitulation of the story. Suffice it to say that the teeth succeed vertically, being thecodont—*i.e.*, contained in the same socket. Absorption of the functional tooth by its successor takes place, owing, no doubt, to some form of absorbent organ, as in man. It is interesting to compare photomicrographs of these two conditions. (See Figs. 233 and 259).

In *Lacertilia*

The common English Green Lizard (*L. viridis*) may be employed as a type.

The chief characteristics are the great length of the tooth band, and the consequent depth of the enamel organ and dentine germ. As far as the maxilla is concerned, the whole tooth germ is placed as closely as possible to a concavity in the upper and inner surface of the jaw at the base of the functional tooth.

The ameloblasts are considerably elongated, and extend deeply down the sides of the dentine germ. The layer is continuous, as in man, with the external epithelium. There

¹ See paper by Howe and Swinnerton on "The Development of the Skeleton of the Tuatera." *Trans. Zoological Soc.*, Feb., 1901.

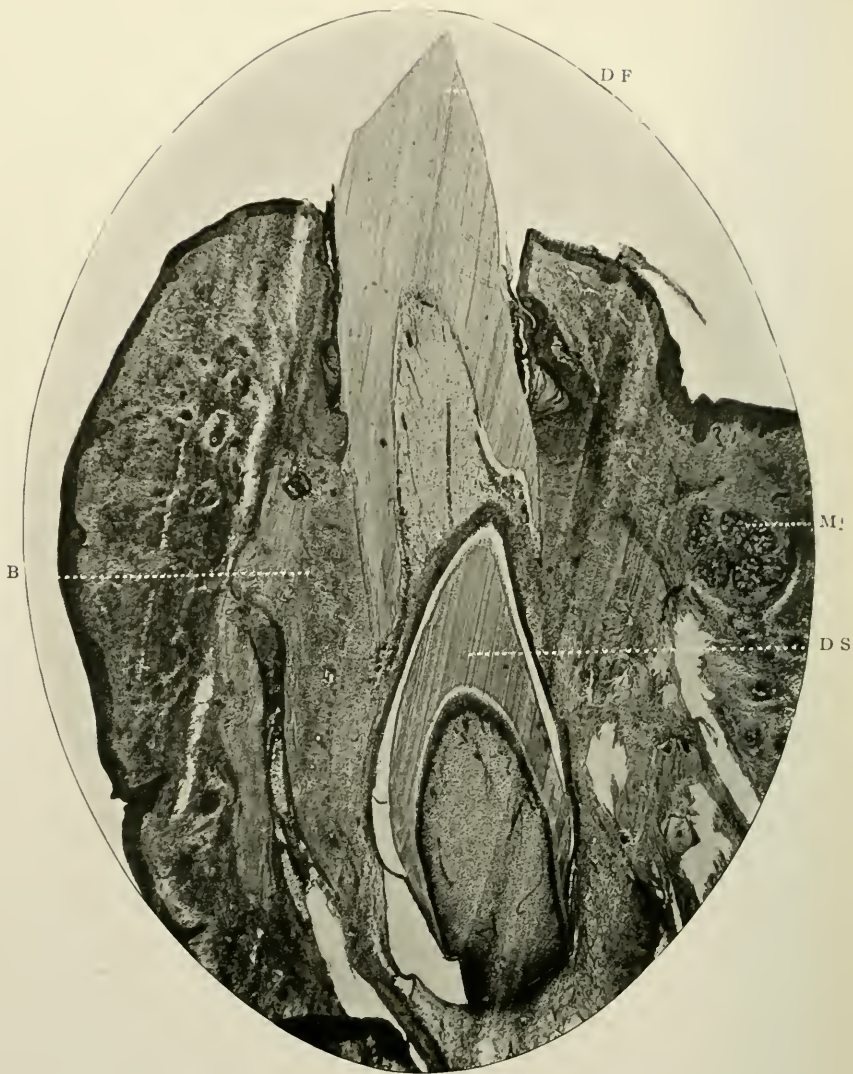


FIG. 259.—Vertical section of mandible of young crocodile. Prepared by hardening and decalcification. Stained with borax-carmin and Ehrlich's acid hæmatoxyline. Magnified 20 times. D.F. Dentine of functional tooth; D.S. Dentine of successional tooth; B. Bone of jaw; M. Mucous gland.

is no *stellate reticulum* in the otherwise well-differentiated enamel organ, but the intermediate space is occupied by a few cells with elongated nuclei. Apparently no cells analogous to the *stratum intermedium* exist.

The continuation of the tooth band is in a line with the deep part of the external epithelium of the enamel organ of

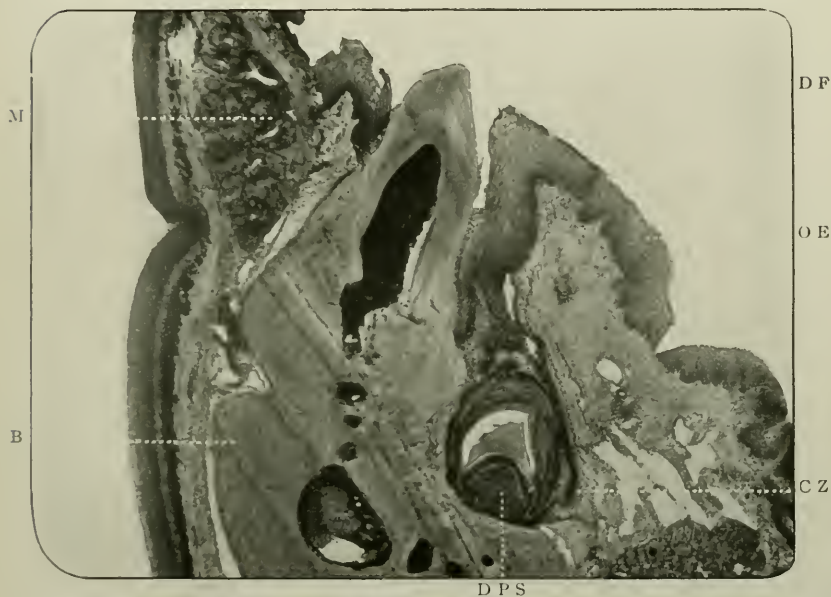


FIG. 260.—Vertical section of jaw of an acrodont lizard. Prepared as in preceding figure. Magnified 25 times. D.F. Dentine of functional tooth; D.P.S. Dentine papilla of successional tooth germ; O.E. Oral epithelium; C.Z. Continuously growing tooth band; B. Bone of jaw to which the functional tooth is ankylosed; M. Mucous gland.

the neighbouring young tooth germs, and in direct continuity with the deepest layer of cells of the original tooth band.

The dentine germ is made up of a dense mass of oval cells, which at the periphery are somewhat elongated.

The submucous tissue by condensation of its cells and fibrous tissue produces an "adventitious capsule."

In *Ophidia*

The bone of the jaw of the common or Ringed Snake (*Tropidonotus natrix*) is somewhat pyriform, with a broad flattened base. The functional tooth surmounts this. Occupying a site internal to the bone, the young tooth germs are found very closely placed, not only to one another, but to the body of the bone itself.

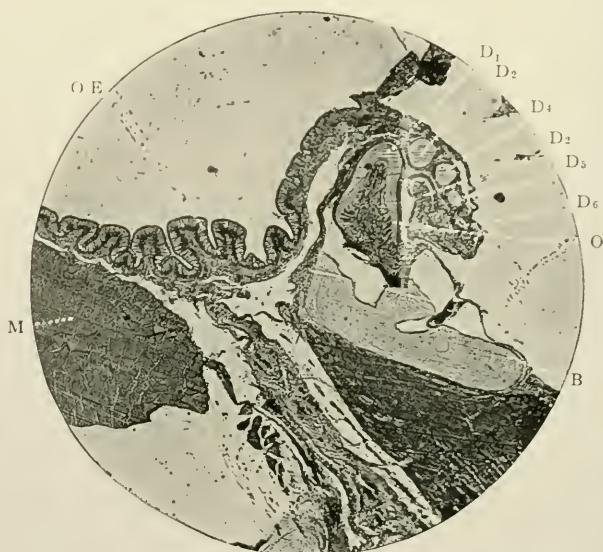


FIG. 261.—Vertical section of jaw of snake. Prepared as in preceding figure. Stained with Ehrlich's acid hæmatoxyline. D_1 . Dentine of oldest tooth germ; O . Odontoblasts of the dentine papilla of the same; D_2 . Dentine of next oldest tooth germ; D_3 , D_4 , D_5 . Dentine of younger tooth germs; D_6 . Dentine of youngest tooth germ; B . Bone of jaw; $O.E.$ Oral epithelium; M . Muscle fibres.

Typical sections shew the oldest tooth germs to be triangular in outline, while the developing teeth in vertical sections have, as a rule, a circular shape. The oldest of the developing teeth in some sections presents a V-shaped outline. This apparent morphological difference is due to the fact that the circular teeth are cut transversely, and the others obliquely, lying as they do in a recumbent or semi-recumbent position before they assume the erect attitude.

The great part of the tooth is composed of ortho-dentine. The layer of odontoblasts is of interest, inasmuch as the cells near the base are the most elongated of all, those at the incisive margin being small and round. The tooth band is very short, surrounding each germ. It is of continuous growth.

The oral epithelium differs in a curious fashion from that of other reptiles. Here it consists of long, narrow cells, which have almost the appearance of ciliated columnar cells. There is only one layer, and it is arranged on a sort of basement membrane, which is puckered up into folds after the fashion of the fungiform papillæ of the tongue.

III

In *Batrachia* (Frogs and Newts)

These animals are cold-blooded vertebrates, which for some, or the whole, period of their existence breathe by gills, and in adult life from lungs. The heart is tri-lobed, having two ventricle and one auricle. Some are ecaudate and apodal. The larva is fish-like and breathes by means of gills, which later on are replaced by lungs. Some, however, retain their gills, while certain frogs leave the egg in a perfect form. They may be oviparous and ovoviviparous.

They are divided into the following orders:

- (i) *Ecaudata*—Frogs and Toads, the former of which is edentulous as far as the lower jaw is concerned, the latter, as to both jaws.
- (ii) *Caudata*—Newts, Salamanders, &c.
- (iii) *Apoda*, or Cœcilians.

The plate and mandibular bones of the newt (*Molge vulgaris*) are extremely thin and delicate. In the median line, at its innermost margin, the palate bones are thickest, the intervening portions being of remarkable tenuity.

Development of the teeth begins in the oral epithelium which is near the free margins of the bone, by a down-growth of epithelium. The tooth band is shallow, but very flat, and grows continuously towards the middle line.

The oral epithelium possesses several characteristics.

The cells are exceedingly brilliant, being almost transparent in nature, that is, the cytoplasm is scarcely granular. This

makes the large oval nuclei particularly prominent, and helps, too, to reveal the karyoplasm and chromatin they contain. The phenomena of mitosis may be well studied here. The epithelial layer is almost twelve cells deep. There is no cellular differentiation into a *rete Malphigii*.

The constituents of the tooth band are flattened bodies with flat nuclei, and they lie more or less in a direction which is parallel to the palate.

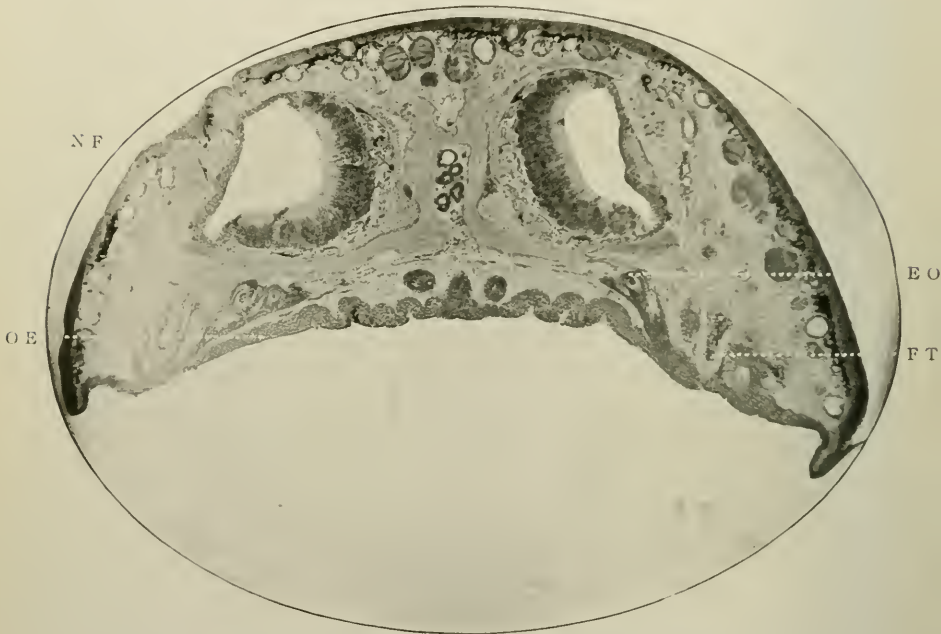

FIG. 262.—Coronal section of the head of a newt, with the mandible detached and removed. Prepared similarly to the preceding figure. Magnified 15 times. O.E. Oral epithelium; F.T. Functional tooth; E.O. Enamel organ of young tooth germ, the tooth band being continued beyond it towards the centre of the palate; N.F. Nasal fossa.

In a typical tooth germ which is beginning to assume a definite shape, the dentine organ is occupied by an assemblage of large elongated cells with reticular nuclei. The dentine is formed at a very early period of growth.

Outside this hard tissue is a layer of smaller rounder cells, and outside this is a second layer, separated from the former by a clear translucent line or space.

There is hardly any attempt at the formation of an enamel organ; if it exists at all, it is an exceedingly rudimentary structure.

In the anterior part of the mouth, the two inwardly extending tooth bands of the palate meet and become fused, and form a continuous uninterrupted sheet of epithelium, cut off on the outer side from the oral epithelium, by a thin band of submucous tissue, whose characteristics are small narrow cells imbedded in a clear matrix scantily supplied with fibres, and forming a succession of young teeth placed side by side on the thin jaw bone. The youngest tooth germs are in the centre of this band, the oldest at its margin.

DEVELOPMENT OF VASO- AND Plici-DENTINE

The process of development is essentially the same as that described in connection with hard or orthodentine (*q.v.* p. 287).

It is, however, somewhat modified by the fact that the odontoblasts are of rounded shape like osteoblasts (Tomes), which deposit calcific material along the bundles of connective tissue fibres, which in the case of fishes are most pronounced on the surface of the pulp. The capillaries remain *in situ*, and the dentine is deposited around them, leaving channels in the dentine.

With regard to plici-dentine, the mode of formation is identical, but the capillaries are not conserved in the dentine.

In *Carcharias*, as Tomes has pointed out, the organic matrix of the outer layer (probably enamel) is furnished by a specialized layer of the dentine papilla, and over this are ameloblasts of enormous length. They may measure 70μ or 80μ .

DEVELOPMENT OF OSTEO-DENTINE

The surface of the pulp is first ossified in the usual way, by deposition of lime salts around its odontogenic fibres. Thus the outer sheath of hard dentine is manufactured.

The bulk of the tissue is, however, developed after the manner of intra-membranous ossification of bone; that is,

rods of osseous material run through the long axis of the pulp, being continuous externally with the rest of the great fasciculi of connective tissue fibres which freely traverse the central soft organ. As Tomes says (*op. cit.* p. 202): "Osteoblasts clothe, like an epithelium, the trabeculae and the connective tissue fibres attached to them, and by the calcification of these the osteo-dentine is formed."

APPENDIX

NOTE A

ON THE FUNCTIONS OF THE CELLS OF THE PULP

I

The questions relative to the functions and uses of the odontoblasts are deep and intricate, and for years have been the subject of earnest inquiry. Many theories as to their properties have been brought forward.

It will be helpful, for a clear comprehension of what is to follow, to briefly enumerate these various opinions. Tomes,¹ and with him the majority of observers, once believed in (A) the conversion theory of the formation of dentine. The cells undergo changes and become converted into matrix, sheath and fibril. In recent years, however, Tomes has spoken on this point with no slight degree of uncertainty. In 1893, he remarked,² "We have always been accustomed to say that they (the odontoblasts) formed the whole of the dentine; now we know that they do not."

Further, Walkhoff³ expresses his opinion that the dentine processes serve essentially for the nutrition of the dentine, the forms of the odontoblasts being in complete accord with their functional requirements. ("Ihre Formen passen sich den jeweiligen Funktionsbedürfnissen durchaus an.")

Again, many histologists including Magitot, Kölliker, etc., hold to (B) the secretion theory, maintaining that the dentinal matrix is secreted from these cells.

¹ "Dental Anatomy," p. 170, 1889.

² *Jour. of Brit. Dent. Assoc.*, vol. xiv., p. 474.

³ "Die Normale Histologie Menschlicher Zähne," p. 128, 1901.

Klein¹ subscribed to the belief that the odontoblasts form matrix only, while the fibrils are not their processes, but stretch out from a deeper layer of cells. In addition, there is the theory of Heitzmann and Bödecker, apparently corroborated by Abbot of New York.² Here the odontoblasts are said to be first broken up into "medullary corpuscles" at their distal end, which become infiltrated first with a glue-yielding basis substance, and afterwards with lime-salts. Thus many conflicting views exist.

The axiom that dentinal fibrils are considered to be sensation conductors is well known to all. Inasmuch, then, as they are regarded functionally in the light of nerves, and as they represent the peripheral poles of the odontoblasts, and are, in fact, part and parcel of those cells, it follows that the latter must be concerned in the act of conveying extrinsic stimuli to the nerves of the pulp. An odontoblast is more of a sensation transmitter than a sensation generator. In other words, it is believed to be a means of communication between fibril and nerve telodendria—not originating, but passing on sensory impulses from without in, and warning the pulp, so to speak, of incoming dangers. This seems to the author a sensible argument, and this is his theory.

In order to prove this, it is necessary to show (1) that odontoblasts do not form dentine, as is generally understood; (2) to prove that they are the end organs of the nerve filaments of the pulp.

Negative Evidences

The arguments to disprove the dentine-forming theory are many and important. They are as follow:

1. No observer has ever seen a semi-calcified odontoblast, or recorded the observation of one secreting a calcareous material, although this has been done over and over again with regard to the ameloblasts of the enamel organ, as Tomes³ and Leon Williams have demonstrated.

¹ "Atlas of Histology," p. 185, 1880.

² *Dental Cosmos*, Sept., p. 821, 1893.

³ *Op. cit.*

2. The same cell cannot take on two totally different functions simultaneously. In general normal histology it is found that complex, branched, ganglionic bodies exist in the nervous system, while very simple cells—osteoblasts—produce the matrix of bone. There must be a separate cell for the formation of fibril and matrix.

3. The presence of spaces between odontoblasts would lead one to expect to find like spaces in dentine, but this is not so. *Per contra*, active osteoblasts are closely packed together.

4. As fibrils and their sheaths are known to cross interglobular spaces, and as the latter are considered to be an arrest of dentinal development, one would expect that if the fibrils were formed by the same agents as those which produced matrix, they themselves (fibrils) would be absent; but this is not so.

5. Again, in the matrix of the dento-genetic zone observed on the margins of incompletely developed pulps, fibrils are seen most clearly to stretch across the intervening boundary, and there is a distinct mark of demarcation between them and the homogeneous substance through which they extend.

6. The granularity of the cells, as has been already stated, is visibly unaffected by dilute acids or chemical reagents; thus it would seem that calcium salts enter but little into their composition.

7. After decalcification in formic acid, the matrix may be torn into laminae, which run parallel to the surface of the pulp cavity, whereas they would run at right angles to that surface if odontoblasts formed matrix.

8. The dissimilarity in the shapes and sizes of the cells is against the acceptance of this view; this dissimilarity would be inexplicable if they formed dentine. Osteoblasts do not differ thus.

9. The fact that nodules of calcific material in the pulp are formed by small round cells, and that odontoblasts take no part in this work, is clearly seen when sections of pulps containing calcareous degenerations are cut *in situ*. This rule obtains in the growth of composite odontomes (see Vol. II).

10. It is a law that after a cell has ceased its functions, it

atrophies and disappears. Here, however, odontoblasts persist long after all dentine matrix has been completed.

11. In some sections of the root, with the pulp *in situ*, here and there odontoblasts are absent. It is remarkable that in these situations their corresponding tubules are wanting.

12. And finally there must be added Underwood's¹ statements—"that the distinction between fibril and matrix is not merely one of a degree of calcification," because it (the fibril) is equally observable when the tissue has been formed but not calcified; it remains after decalcification; it is present in the interglobular spaces where no calcification has occurred; "that all traces of the boundaries of the cells are absolutely obliterated even in imperfectly developed tissue;" and "that the cells and their processes are sharply marked off from the surrounding tissues during all the stages of development."

Positive Evidences

In order to deal satisfactorily with the evidences which are at hand, to show what *are* the functions of the odontoblasts, it is important to take three things into consideration, viz., the development of these cells, their relation to the nutrition of dentine, and the question whether or not the ultimate terminations of the nerves have any direct or indirect connection with the odontoblasts.

And here arise the most serious difficulties that surround the subject. The odontoblasts, as far as is known, are derived from the stomodæal mesoderm, *i.e.*, they are formed on the edge of the up-growing papilla of the dentine organ. If it could be proved that they arise from ectoderm, one great difficulty would be removed, for it would be then quite easy to affirm that they are nerve endings or end bulbs, and their analogy to the cells at the terminations of the optic and auditory nerves would be more striking, not only with regard to their morphology but also their physiology. Most authorities agree that the nervous system is produced primarily by the ectodermic layer of the blastoderm. Schäfer remarks in the last edition of Quain

¹*Op. cit.*, p. 410.

(vol. i., part ii.), "All nerve-fibres and nerve-cells . . . are originally derived from the neural or neuro-sensory ectoderm." If these statements are true, one is led to the conclusion that odontoblasts cannot possibly be, from the developmental point of view, ganglion cells in which sensory or tactile or trophic impulses arise *de novo*. But it is no argument against the idea that they serve as sensation transmitters.

Again, it is difficult to believe that odontoblasts serve merely as factors in the production of and keeping up the nutrition and vitality of dentine, for, as has been pointed out, they are practically absent from the radicular part of the pulp. If this were their office there would be no diversity of shape or size. Dentine is vitalised, in the opinion of the author, by a protoplasmic exudation which emanates from the blood-vessels of the pulp, and fills the tubules by surrounding and protecting and nourishing the fibrils. The pulp capillaries end near the odontoblasts, but do not enter the tubules.

It is an extremely difficult matter to have optical proof that the telodendria of the nerves enter the basal extremities of the odontoblasts, as suggested by Aitchison Robertson. It would be different if the nerves did not lose their myelinic sheaths. The staining and demonstrating of these delicate threads would then be quite easy. But we have the presence of the basal layer of Weil, which exists in that part of the pulp which is most sentient. Pain from irritation and destruction of the fibrils begins in the crown and neck of a tooth, and not as a rule under cementum; and Weil's layer consists of fine fibres which extend deeply into the pulp on the one hand, and into the basal ends of the odontoblasts on the other. The inference, therefore, theoretically and logically speaking, is that many of the fibres in Weil's layer are amyelinic nerve fibres. This can only be disproved by the difficult experiment of severing the main trunk of the nerve and cutting off communication with its centre, and examining the pulp for any degenerative changes that might occur. Gowers¹ wrote, "If a fibre is cut off from its parent cell it degenerates; the part still in connection with the cell does not degenerate."

¹ "Diagnosis of Diseases of Brain."

As odontoblasts are largest and most important in the coronocervical portion of the pulp; as their functions must be closely associated chiefly with this part—in consequence of their large size and importance; and as this part is that through which the nerve sensations chiefly reach the pulp *viâ* the tubules, therefore it would seem that the odontoblasts must be more intimately connected with the nervous system that has hitherto been supposed, and they must be the actual end organs or dental ganglia of the nerves of the pulp. And the corollary is that the term odontoblast is a misnomer.

The Physiology of the Cells of the Pulp Proper

2

Little remains to be said about the central cells of the pulp.

The functions of the spindle-cells is probably a generative one—to produce new odontoblasts in places where the old cells have been modified by the advancing line of freshly deposited dentine. The round cells would seem to have a secretive property, in cases where secondary dentine or nodules, or calcareous degenerations are taking place, in addition to the all-important function of laying down the matrix of dentine in developing teeth. *These* cells, then, should be called odontoblasts.

These researches and arguments tend thus to shew what probably are the functions and uses of the cells of the pulp; it is at present impossible to say absolutely that this view is substantially correct. But until they are disproved, the reader may believe that the building of the dentinal wall of this organ does not depend on the integrity of the odontoblasts, but on the functions of the small secretory cells of the pulp proper; and that while the former are active agents, governing and protecting, as sense or trophic organs, its interior, their duties only ending at the death of the pulp, the latter are more passive agents, serving merely for mechanical purposes by secreting matrix or new dentinal formations during the life of the tooth.

NOTE B

PHYSIOLOGICAL (LACUNAR) ABSORPTION OF THE ALVEOLAR PROCESSES OF THE JAWS OF MAN

The phenomena associated with physiological absorption—as distinct from pathological absorption of the hard tissues—are observed to a remarkable extent in the mouth. The teeth and their sockets exhibit these phenomena and reveal thus another trait in their unique character.

It must be remembered that the bone of the alveolar processes of the jaws is a particularly transitory and unstable structure. Osseous tissue generally is frequently undergoing changes, and that composing the sockets of the teeth at an early period of life begins to show signs of degeneration.

The teeth of man are degenerative organs and their alveolar attachments also. With regard to the latter, five reasons may be adduced: (i) Absence of muscular origins or insertions; (ii) atypical character of the structure of the bone; (iii) poor or inadequate blood supply; (iv) lack of function, and (v) decreased physiological resistance to disease, as to retrogressive metamorphoses.

(i) With the exception of a few fibres of the Buccinator muscle in the molar region there are no reflected or attached muscular tendons or fasciæ in the neighbourhood of the teeth.

(ii) As has been demonstrated in Chap. X., Vol. I, their histological elements differ very greatly from those of compact or cancellous bone.

(iii) Near the terminal margins at the gum the medullary spaces and contents of normal bone are generally absent, leading to malnutrition of the parts.

(iv) The main function of the skeleton is to support the muscles of the body. This function is certainly lacking here; the main function of the alveolar processes is merely to afford attachment, by a fixed gomphosis, for the roots of the teeth.

(v) As a consequence of lack of function, malnutrition and atypical character, resistance to disease is diminished and soon disappears.

“Physiological absorption” “atrophy,” “wasting” are synonymous terms. It occurs very early in man in the alveolar processes of the jaws. Not only does bone undergo this physiological absorption but, as was described in Chap. XI, dentine and cementum do also. This is exemplified on examining a vertical section of the jaws of a young mammal, *e.g.*, a kitten, before the deciduous teeth are shed. Absorption areas of various sizes can be easily seen over the apical as well as the cervical portions of the deciduous teeth. The phenomenon is well observed also in the teeth of animals which have a polyphyodont dentition, such as the crocodile.

The same process occurs through the operations of natural laws in the deciduous teeth of man. Persistent members of this set, even if not followed by any permanent successors, have their roots painlessly absorbed. In these cases the histological process would appear to be identical with pathological ones. The hard parts are removed by the agency of osteoclasts, and very frequently the process of repair may be seen going on side by side with the process of absorption.

If dried skulls of children aged from four to six years be examined, an instructive demonstration of the condition can be obtained as it applies to the shedding of the deciduous teeth and their sockets. There is here an obvious physiological absorption of the bone, the immediate effect being the thinning and destruction of the tissues by a method similar to that which obtains in osteoporosis. Thus there is an entire absorption and complete loss of the sockets of the deciduous teeth occurring in a normal painless manner. With regard to this absorption Tomes¹ says:—“The alveolar portion of the jaw, that which lies above the level of the mandibular canal, is developed around the milk teeth; when they are lost, it disappears, to be re-formed again for the second set of teeth, and is finally wholly removed after the loss of the teeth in old age.”

The skulls of adults show a similar wasting of bone around the cervical and radicular portions of the teeth. Osseous atrophy over the labial surfaces of maxillary and mandibular

¹ *A Manual of Dental Anatomy.* Edited by Marett Tims and Hopewell-Smith, 1914.

canines, over the palatal aspect of the palatine roots of maxillary molars, as well as in other localities is frequently observed.

The changes undergone by the bone of the mandible are well known. Again to quote Mr. Tomes:

“As the jaw undergoes increase in size, large additions are made to its surface by deposition of bone from the periosteum, necessarily lengthening the mandibular canal. The additions to the canal do not, however, take place quite in the line of its original course, but in this added portion it is bent a little outwards and upwards. If we rasp off the bone of an adult jaw down to the level of this bend, *a process which Nature in great part performs for us in an aged jaw*, or if instead we make due allowance for the alteration, the mental foramen becomes an available fixed point for measurement.

“The manner in which the jaw is formed might also be described as wasteful; *a very large amount of bone is formed which is subsequently, at no distant date, again removed by absorption.*

“To bring it more clearly home to the student’s mind, if all the bone formed were to remain, the coronoid process would extend from the condyle to the region of the first premolar, and all the teeth behind that would be buried in its base; there would be no “neck” beneath the condyle, but the internal oblique line would be a thick bar corresponding in width with the condyle. It is necessary to fully realize that the articular surface with its cartilage has successfully occupied every spot along this line, and as it progresses backwards by the deposition of fresh bone, it has been followed up by the *process of absorption* removing all that was redundant.

“On the outer surface of the jaw we can frequently discern a slight ridge, extending a short distance from the head of the bone, but if the prominence were preserved on the inner surface, the mandibular artery and nerve would be turned out of their course. We have thus a speedy removal of the newly formed bone, so that a concavity lies immediately on the inner side of the condyle; and microscopic examination of the bone at this point shows that *the lacunæ of Howship, those characteristic evidences of absorption, abundantly cover its surface, showing that here, at least, absorption is most actively going on.*

“In the same way the coronoid process, beneath the base of which the first, second, and third molars have successfully been formed, has moved backward by *absorption* cutting away its anterior, and by deposition adding to its posterior surfaces.

“In old age, concomitantly with the diminution of muscular energy, the bone about the angle *wastes*, so that once more the ramus appears to meet the body at an obtuse angle. But all the changes which mark an aged jaw are the simple results of a *superficial and not of an interstitial absorption*, corresponding with a wasting of the muscles, of the pterygoid plates of the sphenoid bone, etc.” [The author’s italics.]

To the above, two further instructive illustrations from comparative anatomy may be added. In *Batrachia*, e.g., the frog, the teeth are attached by their bases and external surfaces to a groove in the jaw, having the external wall higher than the inner, and also having on their outer side a new osseous formation which slightly extends over the outer side of each tooth. The deficiency on its inner aspect is supplied by a long pillar, which disappears when the tooth is shed, a new column being developed for the succeeding tooth.

And even a more interesting fact is observed in the mouth of the eel. Here the teeth are fixed to the jaws by means of a “bone of attachment.” When the teeth are shed, the bone of attachment is shed also, being removed from the body of the jaw itself. This is effected by means of large multi-nucleated giant cells, which leave the surface of the bone scalloped out into Howship’s foveolæ.

It is certain that the free alveolar edges of the jaws of man begin to disappear at a very early age. Radiographs show the commencement of the absorption of the bone around the roots of the deciduous teeth in the normal mouths of healthy children at the age even of four years. If radiographs of the jaws of healthy and normal adults aged twenty and more be examined the same thing is apparent. The free edges of the *lamina dura* disappear, while they themselves remain in their other portions intact.

Examples need not be further multiplied; physiological ab-

sorption is so obvious. Finally Hektoen and Riesman (*A Text-book of Pathology*, 1901) write:—"It is generally believed that anæmia of bone favors absorption and hinders apposition, and it may be one of the factors in these forms of atrophy. The atrophy may be concentric or eccentric. It begins, as a rule, at those points *that are free from muscular attachments*. In the calvaria the bone becomes thin, granular and finely porous, especially in the temporal regions. An atrophy occurs in the external table; the internal may become rough from the production of new bone. In the maxillæ the alveolar process may disappear completely."

Bordering on the line between physiological and pathological absorption of bone, as witnessed in the alveolar processes, is that induced by the mechanical action of orthodontical appliances when a tooth is moved from one position to another. Absorption occurs from pressure, on the side opposite to the occasioning force, while deposition of fresh osseous material takes place on the proximate side.

INDEX TO VOL. I

- ABBOT on enamel, 28, 33
 Abrachiate lacunæ, 201, 202
 Absorbent organ, 209
 Origin of, 209
 Osteoclasts of, 211
 Stroma of, 209
 Absorption, physiological, 333
 Addison and Appleton on
 Growth of teeth of rat, 299
 Aitchison Robertson on
 Growth of dentine, 291
 Nerve endings in pulp, 154
 Odontoblasts, 127
 Alveolar processes of jaws, bone of, 208
 Alveolo-dental periosteum, 166
 Black on, 167, 168, 172, 173, 174
 Calco-spherite spherules of, 178
 Cells of, 169
 Epithelial "rests" of, 173
 Fibres of, 167
 Malassez on, 174
 Measurements of, 167
 Nerves of, 177
 Noyes on, 173, 178
 Origin of, 166
 Osteoblasts of, 173
 Osteoclasts of, 173
 Principal fibres of, 167
 Sharpey's fibres of, 169
 Vascular supply of, 177
 Ameloblasts, 245, 250, 279, 281
 Cytoplasm of, 281
 Amyelinic nerve fibres, 135, 145
 Andrews, fibres of, 282
 Andrews on ameloblasts, 282
 On Nasmyth's membrane, 9
 On vascularity of enamel organ, 261
 Antrum of Highmore, 223
 "Battledore" cells of, 225
 Epithelium of, 224
 Glands of, 226
 Antrum of Highmore, Goblet cells of, 225
 Lining membrane of, 224
 Origin of epithelium of, 224
 Sappey on, 223
 Wall of, 205
 Arnell on ameloblasts, 282
 Axones, 142
 "BATTLEDORE," cells of antrum, 225
 Baume on origin of lip-furrow, 235
 Beaver, enamel of, 94
 Bennett on lamellæ in dentine, 77
 Black on epithelial bodies in peri-
 odontal membrane, 174
 On gingival gland, 174
 Bland-Sutton on "Glands of Serres,"
 223
 On development of ovarian teeth,
 305
 Bödecker on enamel, 28, 32
 On Nasmyth's membrane, 10, 11
 On nerve endings in pulp, 155
 On vascular supply of antrum, 224
 Boll on dentinal tubes, 69
 On nerve endings, 149
 On odontoblasts, 126
 On sheaths of Neumann, 69
 Bone, structure of, 196
 Broomell on cementum, 86, 89
 CANINE fossa, bone of, 198
 Capillaries of dental pulp, 137
 Cat, nerves in dental pulp of, 151, 152
 Cemental organ, 272, 302
 Cementum, Black on, 87
 Broomell on, 86, 89
 Development of, 302
 Distribution of, 79
 Incremental lines of, 85
 Magitot on, 302
 Matrix of, 80

- Cementum, Measurements of, 79
 Modifications of, 110
 Of opossum, 110
 Origin of, 79
 Perforating canals of, 87
 Sharpey's fibres of, 87
 Walkhoff on, 84
- Cheeks, structure of, 181
- Choquet on relationships of hard tissues, 19
- Crescents of Gianuzzi, 189, 227
- Czermak, inter-globular spaces of, 69
- DEMILUNES of Heidenhain, 189
- Dental capsule, 212, 266
 Development of, 272
 Fibres of, 214
 Glands of, 215
 Origin of, 212
- Dental pulp, 111
 Cells of, 115
 Measurements of, 111
 Nerves of, 138
 Origin of, 111
 Stroma of, 130
 Vessels of, 134
- Dentary centre, 195
- Dentine, 49
 Aitchison Robertson on growth of, 291
 Bennett on, 77
 Contour lines of, 74
 Development of, 287
 Distribution of, 50
 Experiments in growth of, 201
 Granular layer of, 71
 Growth of, 291
 Homogeneous layer of, 73
 Interglobular spaces of, 69
 Lamellæ of, 76
 Matrix of, 50
 Measurements of, 50
 Measurement of growth of, 291, 295
 Modifications of, 100
 Mummery, on development of, 289
 Mummery, on matrix of, 50
 Odontogenic, fibres of, 52
 Of fishes, 104
- Dentine, Origin of, 50
 Osteo-dentine, 104
 Plicidentine, 100
 Röse on varieties of, 49
 Schreger's lines in, 73
 Secondary dentine, 78
 Varieties of, 49, 100
 Vaso-dentine, 103
 Von Ebner on development of, 289
 Waldeyer on development of, 288
- Dentine of hake, 104
 Of *Pristis*, 102
- Dentinal tubes, 53
 Boll on, 69
 Branches of, 61
 Contents of, 63
 Courses of, 59
 Höhl on, 69
 Klein on contents of, 64
 Kölliker on, 57, 61, 62, 67
 Lent on, 69
 Magitot on contents of, 65
 Measurements of, 57
 Morgenstern on contents of, 65
 Neumann on, 65, 66
 Römer on, 67
 Sudduth on, 68
 Tomes on, 69
 Underwood on, 69
 Walls of, 63, 65
- Dentogenetic zone, 280
- Dependorf on innervation of dentine, 154
- Development of dental capsule, 272
 Of dentine papilla, 245
 Of enamel organ, 238
 Of jaws, 195, 303
 Lepkowski on vascular supply of, 266
 Of osteo-dentine, 325
 Of plicidentine, 325
 Vascular supply of, 262
 Of vaso-dentine, 325
- Development of teeth in cod fish, 314
 Crocodile, 319
 Dog fish, 316
 Human embryos, 303
 Lizard, 319
 Mammals, 231

- Development of teeth in Newt, 323
 Reptiles, 319
 Snake, 322
- EBNER on development of dentine, 289
 On enamel, 33
 On enamel spindles, 43
 On matrix of dentine, 50
- Enamel, 17
 Amelo-dentinal junction of, 47
 Andresen on, 33
 Andrews on development of, 282
 Appearances of, 21
 Arnell on development of, 282
 Of beaver, 94
 Bödecker on, 28, 43
 Bodies of, 31
 Choquet on relationships of, 19
 Development of, 280
 Distribution of, 17
 Encapsuled lacunæ of, 13
 Of fishes, 96
 Of hare, 96
 Imbrication lines of, 26
 Kölliker on, 25
 Leon Williams on development of, 285
 Of man, 21
 Of manatee, 95
 Matrix of, 32
 Measurements of, 18
 Modifications of, 93
 Origin of, 17
 Of porcupine, 95
 Of rat, 94
 Relationships of, 19
 Of rodents, 94
 Of *Sargus*, 97
 Schreger's lines in, 37
 Spee on development of, 282
 Of squirrel, 95
 Structural modifications of, 93
 Sudduth on, 33, 284
 Thorsen on relationships of, 20
 Tomes on, 43, 281
 Tubular, 96, 281
- Enamel "bud," 238
- Enamel organ, ameloblasts of, 250
 Beale on vascularity of, 261
 External epithelium of, 244, 245, 279
 Inner ameloblastic membrane of, 251
 Internal epithelium of, 245, 279
 Leon Williams on, 245, 251, 252, 279
Membrana preformativa of, 251
 Stellate reticulum of, 240, 244, 245, 256, 261, 279
Stratum intermedium of, 241, 245, 252, 255, 261, 279
 Vascularity of, 261
- Enamel rods, 21
 Abbott on, 28, 32, 33
 Bödecker on, 28, 32
 Curvatures of, 34
 Ebner on, 33
 Leon Williams on, 29, 31, 32, 37
 Of man, 21
 Measurements of, 25
 Pigmentation of, 29
 Striæ of Retzius of, 35
 Sudduth on, 33
 Tomes on, 34
 Walkhoff on, 32
- Enamel spindles, 39
 Bödecker on, 43
 Ebner on, 43
 Hertz on, 46, 47
 Höllander on, 43
 Paul on, 45
 Römer on, 41, 44
 Tomes on, 43
 Waldeyer on, 45
 Walkhoff on, 46
 Wedl on, 43
- Epithelial sheath of Hertwig, 174, 257, 279
- FIBRES of Andrews, 282
 "Formative ring," 293, 294, 296, 297
 Fromman's lines in myelinic nerve fibres, 143
- Gasterosteus*, nerves in dental pulp of, 144

- Gianuzzi, crescents of, 189
 Gingival trough, 221
 Glands of antrum, 226
 Salivary, 187
 Of tongue, 186
Gobius, nerves in dental pulp of, 144
 Goblet cells of antrum, 225
 Gum, Andrews on "Glands of Serres"
 of, 223
 Epithelium of, 217, 220
 Glands of, 222
 "Glands of Serres" of, 223, 261
 Papillæ of, 221
 "Spiny" cells of, 220
 Tomes on "Glands of Serres" of,
 223
 Vascular system of, 264
- HAKE, enamel of, 96
 Hard palate, bone of, 203
 Structure of, 191
 Haversian systems, 196
 Hektoen and Riesman on physiological
 absorption, 337
 Hertwig, epithelial sheath of, 174
 Hertz on enamel rods, 34
 On odontoblasts, 129
 Höhl on sheaths of Neumann, 69
 Höllander on enamel spindles, 43
 Homogeneous layer of dentine, 73
 Howes on vascularity of enamel organ,
 261
 Howship's foveolæ (lacunæ), 209
 Huber on nerve endings in dental pulp,
 150
- IMBRICATION lines of enamel, 25, 26
 Incisures, 143
 Intercalary duct, 188
 Interdental septa, bone of, 202
 Intralobular duct, 187
- JAWS, bone of, 195
 Development of, 195, 303
- KLEIN on contents of dentinal tubes,
 64
 On odontoblasts, 328
- Kölliker on dentinal tubes, 61, 62, 63,
 67
 On enamel, 25, 36, 37
 On Nasmyth's membrane, 11
 On nerve endings in pulp, 154
 On odontoblasts, 121
- LABIO-DENTAL strand, 235
Lacerta agilis, nerves of pulp of, 145
 Lacunæ, abrachiate, 201
 Of bone, 197
 Lamellæ of bone, 197
 Of dentine, 76
Lamina dura, 169, 203
 Layer of Weil, 130
 Leche on origin of lip-furrow, 235
 Lent on dentinal tubes, 69
 Leon Williams on development of
 enamel, 285
 On enamel, 31, 32, 37
 On secreting papillæ, 245
 On *stratum intermedium*, 245
 On vascularity of enamel organ,
 285
 Lepkowski on vascular supply of den-
 tinal tissues, 266
 Lingual tonsil, 186
 Lips, structure of 181
 Lip-furrow, 234
 Baume on origin of, 235
 Leche on origin of, 235
 Röse on origin of, 235
 Sudduth on origin of, 235
 Lizard, development of teeth of, 319
 Low on mandible, 195
 Lymph nodes of tongue, 186
- MAGITOT on contents of dentinal
 tubes, 65
 On nerve endings, 152
 On odontoblasts, 127
 On sheaths of Neumann, 68
 On vascularity of enamel organ,
 261
 Malassez on "rests" in periodontal
 membrane, 174
 Manatee, enamel of, 95
 Mandible, bone of, 205
 Low on, 195

- Marett Tims on vascularity of enamel organ, 261
- Maxillary sinus (*see* Antrum).
- Meckel's cartilage, 195, 232
- Mice, nerves in dental pulp of, 148
- Morgenstern on contents of dentinal tubes, 65
On nerve endings, 156
- Mucous glands, 189
Crescents of Gianuzzi of, 189, 227
- Mucous membrane of antrum, 223
Of mouth, 217
- Mummery on development of dentine, 289
On matrix of dentine, 50
On nerve endings in *Mammalia*, 158
- Myelinic nerves of pulp, 140
Axones of, 142
Crosses of Ranvier of, 143
Fromman's lines of, 143
Incisures of, 143
Internodular segments of, 143
Kölliker on, 154
Method of distribution of, 140
Myelin sheath of, 143
Neurilemma of, 143
Nodes of Ranvier of, 143
Schäfer on, 158
Structure of, 142
Terminations of, 144
In fishes, 144
In mammals, 148
In reptiles, 145
- NASMYTH'S membrane, 9
Andrews on, 9
Bödecker on, 10
Cellular layer of, 11
Development of, 279
Distribution of, 9
Kölliker on, 11
Lacunæ in, 13
Measurements of, 10
Origin of, 9
Of ovarian teeth, 16
Paul on, 13
Translucent pellicle of, 13
- Nervous system of periodontal membrane, 177
Of pulp, 138
- Neumann, sheaths of, 65
On contents of dentinal tubes, 66
- Neurilemma, 143
- Newt, development of teeth of, 324
- Noyes on alveolo-dental periosteum, 178
On osteoblasts, 173
- ODONTOBLASTS, 116
Aitchison Robertson on, 127
Analogies of, 129
Boll on, 126
Hertz on, 129
Kölliker on, 121
Magitot on, 127
Paul on, 119, 121, 122, 129
Processes of, 126
Relationships of, 121
Röse on, 115
Shape of, 116
Size of, 121
Structure of, 122
Transitional tissue of, 122
Underwood on, 119, 330
Waldeyer on, 121
- Odontogenic fibres, 52
- Opossum, cementum of, 110
- Ortho-dentine, 49
- Osteoblasts, 173
- Osteoclasts, 173
- Osteo-dentine, 104
Development of, 325
- Osteoid dentine, 109
- Owen's lines in dentine, 74
- Ox, nerves in pulp of, 154
Odontoblasts of, 127
- PALATE, 191
Bone of, 203
Papilla palatina, 192
Soft palate, 191, 192
- Papillæ of tongue, 182
Circumvallate papillæ, 184
Conical papillæ, 183
Fungiform papillæ, 184
Gustatory cells of, 186

- Papillæ of tongue, Schäfer on, 184
 Parotid gland, 187
 Partsch on basal layer of Weil, 132
 Paul on enamel spindles, 45
 On Nasmyth's membrane, 13
 On odontoblasts, 119, 121, 122, 129
 On tubular enamel, 98
 On vascularity of enamel organ, 261
 Paulton on vascularity of enamel organ, 261
 Periodontal membrane (*see* Alveolar dental Periosteum).
 Periosteum of bone, 197
 Physiological absorption, Hektoen and Riesman on, 337
 Plicidentine, 100
 Development of, 325
 Pont on nerves of the pulp, 160
 On odontoblasts, 161
 Porcupine, enamel of, 95
 Primary epithelial inflection, 234, 278
 Primitive dental furrow, 233
Pristis, dentine of, 102
 Pulp, arteries of, 134, 136
 Basal layer of Weil of, 130
 Capillaries of, 137
 Cells of, 115
 von Ebner on basal layer of Weil of, 133
 Mummery on basal layer of Weil of, 132, 134
 Nervous system of, 138
 Partsch on basal layer of Weil of, 132
 Supporting fibres of, 122
 Veins of, 137
 Weil on basal layer of, 130
 RABBITS, nerves in dental pulp of, 149
 Ranvier, crosses of, 143
 Nodes of, 143
 Raschkow, plexus of, 140, 164
 Rat, enamel of, 94
 Growth of teeth of, 290
 Retzius on nerve endings in dental pulp, 144, 145, 148
 Striae of enamel of, 35
 Römer on enamel spindles, 41, 44
 On nerve endings in pulp, 153
 On walls of dentinal tubes, 67
 Röse on odontoblasts, 115
 On origin of lip-furrow, 235
 On varieties of dentine, 49, 108
 Russell's fuchsine bodies, 221
Salumander maculata, nerves in pulp of, 148
 "Salivary corpuscles," 194
 Salivary glands, 187
 Acini, 188
 Ducts of, 187
 Structure of, 187
 Salter on secondary dentine, 78
 On cementum, 86
 Sappey on antral glands, 223
Sargus ovis, enamel of, 97
 Schäfer on myelinic nerves, 158
 On nerve endings, 158
 On origin of nerves, 330
 On papillæ of tongue, 184
 Schreger's lines in dentine, 73
 In enamel, 37
 Schultze on axones, 142
 Schweitzer on supposed pulp lymphatics, 137
 Secondary dentine, 78
 Serous glands, 190
 Serres, "glands" of, 223, 261
 Sharpey's fibres, 87, 160, 197, 198
 Sheaths of Neumann, 65
 Boll on, 69
 Höhl on, 69
 Lent on, 69
 Magitot on, 69
 Römer on, 67
 Sudduth on, 68
 Tomes on, 69
 Underwood on, 69
 Snake, development of teeth of, 322
 Spee on ameloblasts, 282
 Spiny cells of gum, 220
 Of Nasmyth's membrane, 13
 Squirrel, enamel of, 95
Stratum intermedium, 241, 245, 252, 255, 261, 279

- Stellate reticulum, 240, 244, 245, 256,
261, 270
- Stöhr on alveolo-dental periosteum,
166
On cementum, 87
- Sublingual gland, 187
- Submaxillary gland, 187
- Sudduth on enamel, 33
On sheaths of Neumann, 68
- Sympathetic nerves of pulp, 144
- TOMES on dentine, 49, 70
On dentinal tubes, 69
On enamel, 34, 281
On enamel organ, 261
On enamel "spindles," 43
On "glands of Serres," 223
On odontoblasts, 327
On osteo-dentine, 108
On physiological absorption, 334,
335
On sheaths of Neumann, 69
- Tongue, glands of, 186
Lymph nodes of, 186
Muscles of, 181
Papillæ of, 182
Taste buds of, 186
- Tonsils, lymphoid cells of, 193, 194
Lymphoid follicles of, 193
- Tooth-band, 234, 278
- Trabecular dentine, 108
- Translucent pellicle of Nasmyth's
membrane, 13
- Triton cristatus*, nerves of pulp of, 148
- Tubular enamel, 96
- UNDERWOOD on cementum, 90
On odontoblasts, 119
On sheaths of Neumann, 69
- Uvula, structure of, 192
- VASCULARITY of enamel organ, 261
- Vaso-dentine, 103
Development of, 325
- Vitro-dentine, 49, 108
- Vitro-trabecular dentine, 109
- Veins of the pulp, 137
- WALDEYER on development of dentine,
288
On enamel spindles, 45
On odontoblasts, 121
- Walkhoff on cementum, 84
On Dental Histology, 4
On enamel, 32
On enamel spindles, 47
On odontoblasts, 327
- Wedl on vascularity of enamel organ,
261
- Weil, basal layer of, 130
- Welcker on dentinal tubes, 60

RK280

IA

H772

1918 1

Hopewell-Smith

Normal and pathological histology
of the mouth.

1/3/11 Balled

1/2 2/3 1/4 2/4-30

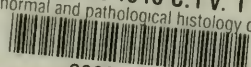
Annex

1-23-31

IA

Annex

COLUMBIA UNIVERSITY LIBRARIES (hsl.stx)
RK 280 .H772 1918 C.1 v. 1
 The normal and pathological histology of



2002384272

